

## Polymorphous Light Eruption in Hypopigmented Pressure Areas with a UVA Sunbed

E. TEGNER and A. M. BRUDIN

*Department of Dermatology, University of Lund, Lund, Sweden*

Tegner E, Brudin AM. Polymorphous light eruption in hypopigmented pressure areas with a UVA sunbed. *Acta Derm Venereol (Stockh)* 1986; 66: 446-448.

In two persons a papular dermatitis was provoked by UVA on an area of the back which was subjected to high pressure and therefore did not tan. The inflammation observed had the appearance of a polymorphous light eruption, but neither of the individuals had a history of any pathological light reaction. *Key word: Oxygen.* (Received March 5, 1986.)

E. Tegner, Department of Dermatology, University Hospital, S-221 85 Lund, Sweden.

Skin areas under pronounced external pressure, probably leading to tissue anoxia, will not exhibit delayed erythema or immediate or delayed pigmentation from UVA (1). This results in a "white area" on the medial sacro-gluteal region and on the scapular region, a phenomenon well known from commercial UVA tanning booths. Application of a stabilized hydrogen peroxide cream induces delayed tanning on the pressure sites after UVA irradiation, whereas the placebo-treated contralateral sites remain unpigmented (2). This finding supports the assumption that oxygen reduction products mediate delayed pigmentation by UVA (1, 3, 4). The present report describes a peculiar papular reaction confined to the sacral hypopigmented area observed after exposure to UVA light on a sunbed.

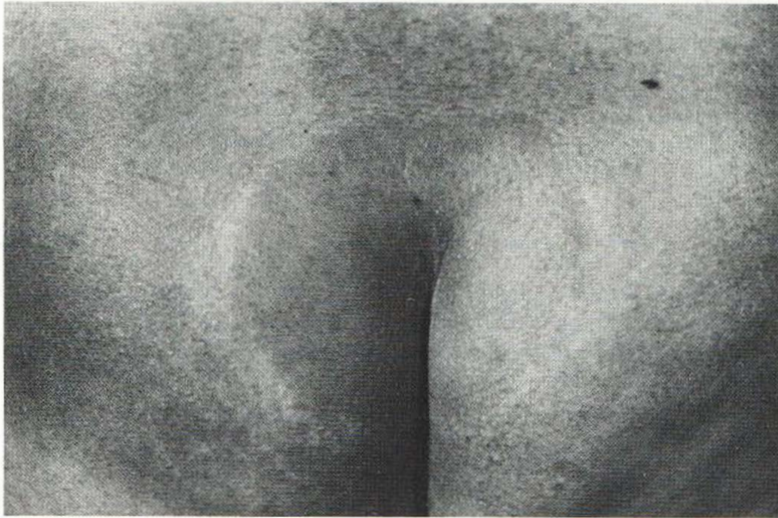
### CASE REPORTS

#### *Case 1*

A 34-year-old healthy woman with skin type II, who had never before had any skin diseases or shown intolerance to light, took part in a series of UVA light exposures given to volunteers in order to study the role of oxygen in pigment response to UVA. The light source was a high-intensity UVA system (Philips TL 85 W/09 T) with an emission spectrum of 310-420 nm and a peak emission of 355 nm. About 0.4% of the radiant energy output of this light source is in the UVB region. The sunbed consisted of 10 tubes above which was a transparent plate of acrylic plastic for the individual to lie on. Using a Waldmann UV-meter (H. Waldmann Werk für Lichttechnik, Germany) the intensity of the lamp in the UVA region was estimated to 7.25 mW/cm<sup>2</sup> just above the plate. The skin was exposed for 30 min per day, 4-5 times per week, 10 exposures in all. After 3 days the woman reported itching over the non-pigmented medial sacral area. After 4 days this skin area was erythematous and after 5 days confluent papules were seen over this area, which was thereafter covered with a cloth during irradiation. After about a week the skin lesions had healed and the white skin area was again easily observed. About 6 weeks later, the exposures to UVA light on the sunbed were repeated. Again after 3 days she complained of itching confined to the non-pigmented medial sacral area: after 4 days this area was erythematous and slightly oedematous (Fig. 1). A skin biopsy was taken and the histopathological examination showed no epidermal changes. In the upper dermis some oedema was seen and in the middle dermis lymphocytic infiltrates, predominantly with a perivascular distribution but sometimes also round the adnexae, were observed (Fig. 2).

#### *Case 2*

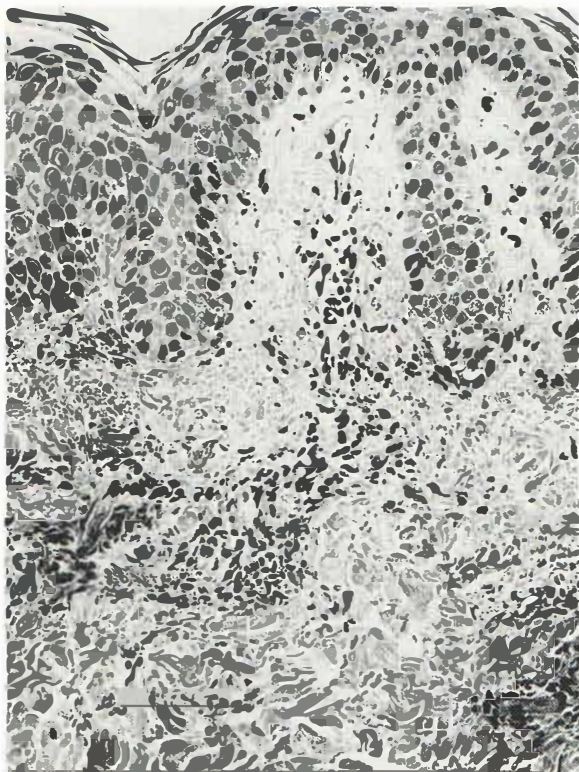
A 28-year-old healthy woman with skin type II, who had never before had any skin diseases or shown intolerance to light, took part as a volunteer in the same study mentioned above. She had been exposed to UVA light on sunbeds before but had earlier always worn panties during light exposure. After 3 days the woman reported itching over the non-pigmented medial sacral area. After 4 days this non-pigmented pressure area was erythematous with slight oedema and papules. During the following irradiations this skin area was shielded with a cloth and a steroid ointment was also applied locally.



*Fig. 1.* Erythematous, slightly oedematous eruption confined to hypopigmented pressure area after 4 days of UVA irradiation.

After another 4 days the eruption had healed, and the white skin area over the sacrum was again discernible.

About 2 months later the UVA irradiations on the sunbed were repeated. Before each irradiation a hydrogen peroxide cream and its placebo were randomly applied on symmetrical sacro-gluteal areas according to the double-blind principle. The creams were applied to the selected areas 5 times (once every 5 min) before the irradiation. After 4 days the subject complained of itching and some days later



*Fig. 2.* Focal lymphocytic infiltrates in the middle dermis and a slight oedema in the upper dermis after 4 days of UVA irradiation.

this area was red and partly papulomatous. The white spot was now asymmetrical, more pronounced on the side pretreated with the placebo cream and hardly discernible on the side pretreated with the hydrogen peroxide cream. However, the erythematous reaction could be seen on both sides. After 9 irradiations a biopsy was taken from the inflamed skin not treated with hydrogen peroxide and the histopathological examination showed a slight oedema in the corium papillae and deeper in the corium lymphocytic infiltrates predominantly with a perivascular distribution were seen. Light testing with UVB light was performed with a Xenon lamp. Irradiation with 4 and 8 × MED gave no pathological reaction.

## COMMENTS

Of about 100 individuals exposed to UVA on sunbeds in our department 2 females developed a peculiar papular reaction confined to the hypopigmented sacral spot. We have learned from laymen using UVA sunbeds for cosmetic reasons that about 1% of their customers developed "sun eczema" on the white spot over the sacrum. However, many of the customers use panties during irradiation to avoid erythematous reactions on the previously non-sunexposed gluteal skin. The papular reaction in our two cases had similarities with a polymorphous light eruption (PMLE). However, neither of the two individuals had had any pathological light reaction before. PMLE is provoked by UVB but perhaps more often by UVA (5, 6, 7). Light testing with UVB light in one of the women did not provoke any pathological light reaction. However, there seem to be few reports on PMLE after UVA irradiation from a UVA sunbed used for cosmetic reasons (8). This may be due to the fast development of a tan—immediate pigmentation followed by delayed pigmentation—which offers a good photoprotective screen in many photosensitive disorders. In fact, in experimental studies it is difficult to provoke PMLE with UVA in a tanned skin (7, 9). The PMLE eruption in the sacral pressure area in our 2 patients after UVA exposure may be due to the lack of a photoprotective pigmentation in this area. The application of the hydrogen peroxide cream did not prevent the erythematous light reaction, but it should be noted that the pigment response to UVA in the H<sub>2</sub>O<sub>2</sub>-treated area of the skin appeared rather late (after 5 days).

Our observations indicate that the development of the eruptions described was independent of the presence of oxygen in the tissue at the time of exposure to light. This is in contrast with the mechanism effective in the appearance of "normal" erythema and pigmentation after exposure to UVA which both are dependent on oxygenation of the tissue at the time of irradiation (1, 4).

## REFERENCES

1. Tegner E, Rorsman H, Rosengren E. 5-S-Cysteinyl-dopa and pigment response to UVA light. *Acta Derm Venereol (Stockh)* 1983; 63: 21–25.
2. Tegner E, Björnberg A. Induction of UVA pigmentation in pressure areas by hydrogen peroxide. *Acta Derm Venereol (Stockh)* 1986; 66: 65–67.
3. Tegner E. Tissue anoxia prevents inflammation and pigmentation caused by UVA but not by UVB or PUVA. *Photodermatology* 1984; 1: 311–312.
4. Auletta M, Gange RW, Tan OT, Matzinger EA. Abstract. The differential effect of cutaneous blood flow upon the induction of UVA and UVB pigment responses in human skin. *J Invest Dermatol* 1984; 82: 420.
5. Frain-Bell W, Dickson A, Herd J, Sturrock I. The action spectrum in polymorphic light eruption. *Br J Dermatol* 1973; 89: 243–249.
6. Epstein JH. Polymorphous light eruption. *J Am Acad Dermatol* 1980; 3: 329–343.
7. Hölzle E, Plewig G, Hofman C, Roser-Maass E. Polymorphous light eruption. Experimental reproduction of skin lesions. *J Am Acad Dermatol* 1982; 7: 111–125.
8. Devgun MS, Johnson BE, Paterson CR. Tanning, protection against sunburn and vitamin D formation with a UVA sunbed. *Br J Dermatol* 1982; 107: 275–284.
9. Gschnait F, Hönigsmann H, Brenner W, Fritsch P, Wolff K. Induction of UV light tolerance by PUVA in patients with polymorphous light eruption. *Br J Dermatol* 1978; 99: 293–295.