

## Treatment of Erosive Lichen planus with Dapsone

HANS-IVER BECK and FLEMMING BRANDRUP

*Department of Dermatology and Venereology, Odense University Hospital, DK-5000 Odense C, Denmark*

Beck H-I, Brandrup F. Treatment of erosive lichen planus with dapsone. *Acta Derm Venereol (Stockh)* 1986; 66: 366-367.

A 74-year-old woman with a chronic, severe, erosive lichen planus on the tongue, buccal mucosa and toes was treated successfully with dapsone. Previous therapy had failed. Partly due to side effects. *Key word: Erosions.* (Received January 29, 1986.)

Hans-Iver Beck, Department of Dermatology and Venereology, Odense University Hospital, DK-5000 Odense C, Denmark.

Dapsone has a therapeutic effect in several dermatoses (1). A possible mechanism of action may be an ability to inhibit the polymorphonuclear leukocyte cytotoxicity (2). However, this drug may have an anti-inflammatory effect as well in dermatoses without predominant polymorphonuclear infiltration. Thus, recently a report on successful treatment of erosive lichen planus with dapsone has been published (3), which is confirmed in the following case report.

### CASE REPORT

A 74-year-old woman was seen in the out-patient clinic in 1983 due to an itching, papular skin disease and erosions in the mouth. The patient had been suffering from lichen planus since 1971 with lesions in the mouth and eruptions of typical, lichenoid papules, mainly at the extremities including some toes.

In 1983, extensive, whitish lesions with erosions were seen at the dorsum of the tongue, buccal mucosa and soft palate. Pruritic, violaceous, lichenoid papules were seen on the extremities, including the dorsal and ventral aspects of hands and feet. On the first toe of both feet severe, chronic, violaceous lesions were seen leading to destruction of the nail matrix and consequently onychia with erosions of the nail beds. Typical histological features were found in a punch-biopsy from a skin papule.

The patient was treated with prednisolone orally for 5 months in an initial dosage of 25 mg daily, gradually reduced to 5 mg daily, with good clinical effect of higher doses. However, the treatment had to be stopped due to arterial hypertension, glycosuria, dyspepsia and mental depression. Subsequent treatment with etretinate (Tigason®) (4) 50 mg daily for two months was unsuccessful.

In May 1985 the patient was still severely affected by erosive lesions on the tongue (Fig. 1A), buccal mucosa and first toes. Treatment with dapsone (Avlosulfon®) 50 mg daily was started, gradually increased to 150 mg daily. At monthly controls, gradual epithelialisation of the erosions was observed, and at the last control after 7 months' treatment the lesions on the buccal mucosa and toes had completely healed, and the erosions on the tongue (Fig. 1B) were reduced to about ¼ of the pretreatment size. The itching had disappeared and the patient could eat and walk without inconvenience.

### DISCUSSION

Our patient had been suffering from rather severe, erosive lichen planus for years, and the beneficial effect of dapsone seems to be evident.

It is interesting that dapsone is effective in lymphocyte-rich lesions like lichen planus, as well as polymorphonuclear leukocyte infiltrations like dermatitis herpetiformis. The drug may be working through a mechanism similar to that proposed for dermatoses with polymorphonuclear infiltrations, i.e. an inhibition of the myeloperoxidase-hydrogenperoxide cytotoxic system (2, 5). Furthermore, an inhibition of the release of inflammatory and/or chemotactic factors from mast cells (6) might be of importance.

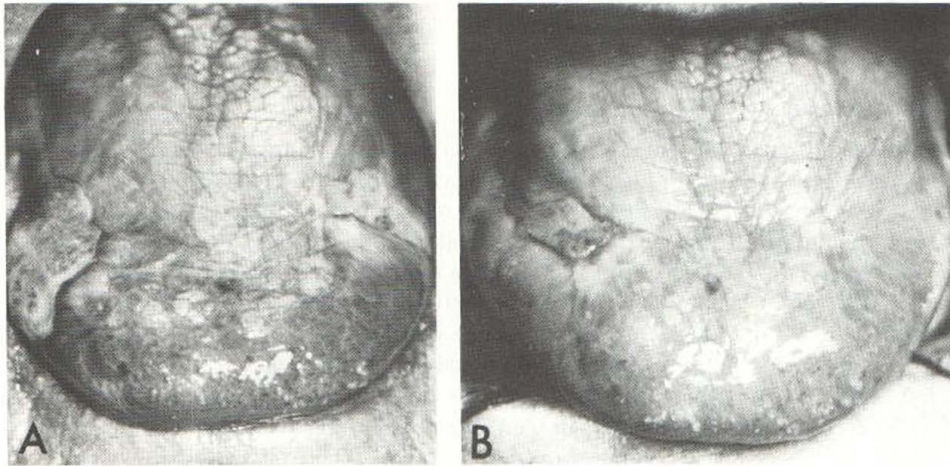


Fig. 1. The tongue prior (A) to dapsone treatment and after seven months (B).

Dapsone may be useful in severe cases of erosive lichen planus, when short courses of systemic steroids have failed to induce prolonged remissions. However, further studies of series of patients with erosive as well as non-erosive lichen planus are needed to establish the effect of dapsone in lichen planus.

#### REFERENCES

1. Lang PG. Sulfones and sulfonamides in dermatology today. *J Am Acad Dermatol* 1979; 1: 479-492.
2. Stendahl O, Molin L, Dahlgren C. The inhibition of polymorphonuclear leukocyte cytotoxicity by dapsone. *J Clin Invest* 1978; 62: 214-220.
3. Falk DK, Latour DL, King LE. Dapsone in the treatment of erosive lichen planus. *J Am Acad Dermatol* 1985; 12: 567-570.
4. Sloberg K, Hersle K, Mobacken H, Thilander H. Severe oral lichen planus: remission and maintenance with vitamin A analogues. *J Oral Pathol* 1983; 12: 473-477.
5. Clark RA, Klebanoff SJ. Myeloperoxidase-H<sub>2</sub>O<sub>2</sub>-Halide system: Cytotoxic effect on human blood leukocytes. *Blood* 1977; 50: 65-70.
6. Ruzicka T, Wasserman SI, Soter NA, Printz MP. Inhibition of rat mast cell arachidonic acid cyclooxygenase by dapsone. *J Allergy Clin Immunol* 1983; 72: 365-370.