

4. Aggett PJ, Atherton DJ. Symptomatic zinc deficiency in breast-fed premature infants. *Arch Dis Child* 1980; 55: 547-550.
5. Ahmed S, Blair AW. Letter. Symptomatic zinc deficiency in a breast-fed infant. *Arch Dis Child* 1981; 56: 315.
6. Husnoo MA, Hutchinson PE, Swift PGF. Letter. Symptomatic zinc deficiency in a breast-fed infant. *Arch Dis Child* 1981; 56: 735.

## Pyrogallol in the Tumour Stage of Mycosis fungoides: A Case Report

P. C. M. van de KERKHOF

*Department of Dermatology, University of Nijmegen, Nijmegen, The Netherlands*

van de Kerkhof PCM. Pyrogallol in the tumour stage of mycosis fungoides: A case report. *Acta Derm Venereol (Stockh)* 1986; 66: 361-363.

The case history of a patient with mycosis fungoides (tumour stage) is reported. As ultimum refugium pyrogallol 5% in petrolatum proved to be remarkably effective. (Received January 30, 1986.)

P. C. M. van de Kerkhof, Department of Dermatology, University of Nijmegen, Javastraat 104, 6524 MJ Nijmegen, The Netherlands.

### CASE REPORT

The patient was a 60-year-old woman, who at the age of 53 experienced erythematous-squamous skin lesions on the face, neck, presternal region and lower arm. After 4 years the clinical and histological picture had developed to a classical mycosis fungoides. One year later tumours were seen on her face. Physical examination, laboratory investigations, X-ray of thorax, CT scan of the abdomen, sternum aspirate and crista biopsy did not reveal any sign of systemic involvement.

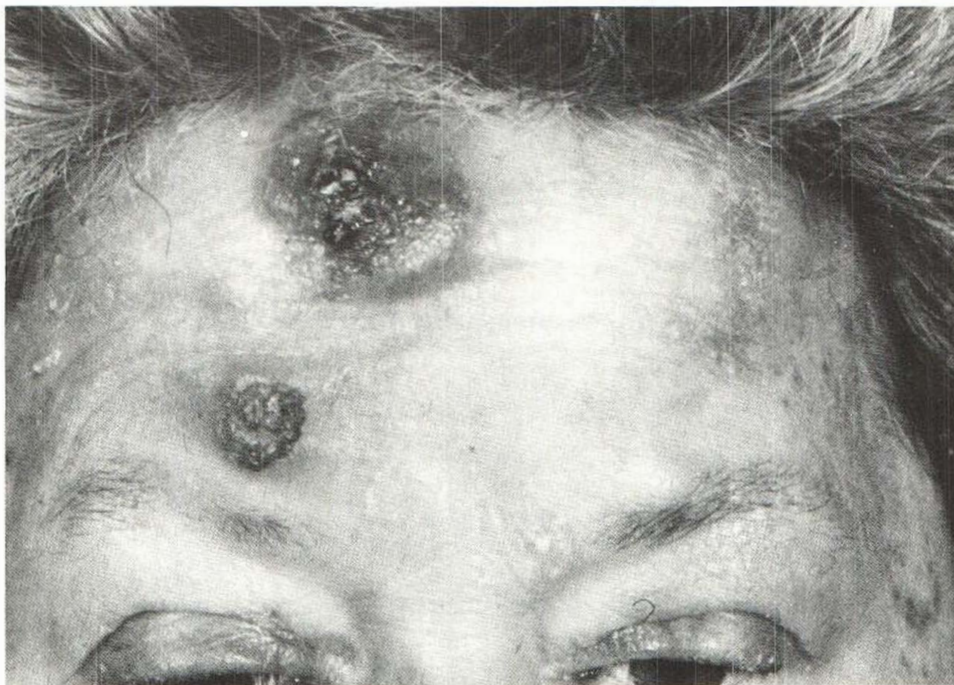
Topical application of nitrogen mustard had been partially effective. However, contact sensitization complicated this therapy. PUVA and PUVA + Etreinate had no effect at all. Radiotherapy (electron beam and orthovoltage X-ray) resulted in remissions of short duration (a few weeks). Cumulative dosages on the forehead had reached 5400 Rad.

Therefore we tried an alternative therapy; pyrogallol 5% in petrolatum was applied daily on the tumours. The clinically uninvolved skin surrounding the lesions was protected by zinc paste. The effectivity of this treatment is shown in Fig. 1. The tumours resolved via crust formation. After 2 months of therapy only a residual erythema and some hyperpigmentation remained. Therapy was discontinued and up to the time of writing this communication (5 months of observation) the treated areas remained clinically clear.

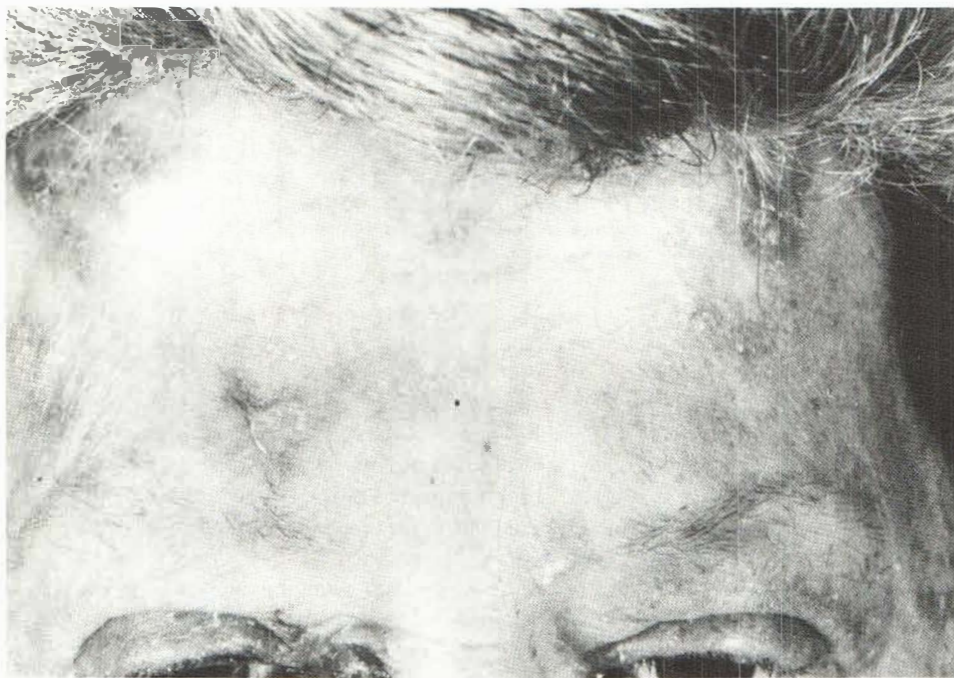### DISCUSSION

Pyrogallol has been used with success in the treatment of psoriasis (1). As far as we know this is the first report of a beneficial effect of this substance in mycosis fungoides. In this respect it is of interest that many other therapies are effective in both mycosis fungoides and psoriasis. Topical corticosteroids, tar, PUVA, radiotherapy and nitrogen mustard are well known therapies for both diseases. Methotrexate and retinoids, classical therapies for psoriasis, are also effective in mycosis fungoides (2-4).

The working mechanism of pyrogallol is not clear. It is a potent reducing agent. An inhibitory effect of pyrogallol on catechol-O-methyltransferase has been described (5). Theoretically this biochemical effect could account for the effectivity in psoriasis and mycosis fungoides, both diseases being characterized by a hyperproliferative cell system (epidermal hyperproliferation and T-cell proliferation respectively). Hyperproliferative



*Fig. 1 (a).* Tumours on the forehead before treatment with pyrogallol.



*Fig. 1 (b).* The same area after 2 months therapy.

cell systems can be inhibited *in vitro* by increased intracellular cyclic AMP levels (6). The inhibition of catechol-O-methyltransferase by pyrogallol results in an accumulation of catecholamines in the treated areas. Such an accumulation will increase the intracellular cyclic AMP levels via stimulation of adenylylase (7).

It seems worth while to investigate the effectivity of this drug in a series of patients with mycosis fungoides. An extra therapeutic modality for stubborn cases would be of great practical value.

#### ACKNOWLEDGEMENT

The author wishes to thank Professor J. W. H. Mali for his advice to keep in mind therapies from many decades ago.

#### REFERENCES

1. Baker H, Wilkinson DS. Psoriasis. In: Rook A et al., eds. Textbook of dermatology. Oxford: Blackwell Scientific Publications, 1979; 1315–1368.
2. Edelson RL. Cutaneous T cell lymphoma: Mycosis fungoides, Sézary syndrome, and other variants. *J Am Acad Dermatol* 1980; 2: 89–106.
3. Thomsen K, Molin L, Volden G, Lange Wantzin G. 13-cisretinoic acid effective in mycosis fungoides. *Acta Derm Venereol (Stockh)* 1984; 64: 563–566.
4. Claudy AL, Rouchouse B, Boucheron S, Le Peptid JC. Treatment of cutaneous lymphom with etretinate. *Br J Dermatol* 1983; 109: 49–56.
5. Ackermann H. Die kalorigene Wirkung von Adrenalin ohne und nach Vorbehandlung mit Pyrogallol und Desipramin. *Biomed Biochem Acta* 1984; 3: 395–400.
6. Voorhees JJ, Duell EA, Kelsy WH. Dibutyl cyclic AMP inhibition of epidermal cell division. *Arch Dermatol* 1972; 105: 384–386.
7. Gommen JM, Bergers M, van Erp PEJ, van de Hurk JJMA, van de Kerkhof P, Mier PD, Roelfzema H. Studies on the plasma membrane of normal and psoriatic keratinocytes. 2. Cyclic AMP and its response to hormonal stimulation. *Br J Dermatol* 1979; 101: 413–419.

### Vulval Lichen sclerosus et atrophicus Treated with Etretinate (Tigason®)

NILS-JØRGEN MØRK,<sup>1</sup> PETTER JENSEN<sup>1</sup> and PER SIGURD HOEL<sup>2</sup>

<sup>1</sup>Department of Dermatology and <sup>2</sup>Department of Pathology, The National Hospital, Oslo, Norway

Mørk NJ, Jensen P, Hoel PS. Vulval lichen sclerosus et atrophicus treated with etretinate (Tigason®). *Acta Derm Venereol (Stockh)* 1986; 66: 363–365.

In an open uncontrolled study eight patients with vulval lichen sclerosus et atrophicus were given etretinate (Tigason®) 1 mg/kg/day. The dose was then gradually reduced according to effect and side effects. Six patients showed improvement in symptoms and in clinical morphology based on the physician's evaluation and photographic documentation. In four of five patients where biopsies were taken, there was a marked change in the histological picture towards normalization. Two patients did not respond to the treatment. All patients experienced the well-known side effects of etretinate in various degree. We conclude that treatment with etretinate should be tried in vulval lichen sclerosus et atrophicus if the result of other therapeutical efforts are unsatisfactory. (Received February 13, 1986.)

N. J. Mørk, Department of Dermatology, Rikshospitalet, Pilestredet 32, Oslo 1, Norway.

Lichen sclerosus et atrophicus in women is commonly restricted to the perigenital region. Treatment for this condition is most unsatisfactory. Many patients suffer from itching and burning sensations giving difficulties in their sexual and marital relations.