

Incontinentia Pigmenti and Behçet's Syndrome: An Unusual Combination

SILVANO MENNI,¹ ROBERTA PICCINNO,¹ ANGELA BIOLCHINI,²
ROSA MARIA DELLE PIANE² and MARIA BARDARE²

¹Istituto di Clinica Dermatologica I e Dermatologia Pediatrica and ²Istituto di
Clinica Pediatrica I, University of Milan, Italy

Menni S, Piccinno R, Biolchini A, Delle Piane RM, Bardare M. Incontinentia pigmenti and Behçet's syndrome: an unusual combination. *Acta Derm Venereol (Stockh)* 1986; 66: 351-354.

We describe an unusual case of a child who had had incontinentia pigmenti from birth and developed the clinical picture of Behçet's syndrome at five years of age. Among the various investigations performed, chemotactic activity of the polymorphonuclear leukocyte was found to be low. We discuss the possibility that there are common immunological abnormalities in the two syndromes. *Key words: Chemotaxis; Polymorphonuclear leukocytes.* (Received December 6, 1985.)

S. Menni, Istituto di Clinica Dermatologica I e Dermatologia Pediatrica, University of Milan, Via Pace 9, 20122 Milan, Italy.

We report a case of a female child with the rare combination of incontinentia pigmenti and Behçet's syndrome. The first condition is hereditary, usually occurring in females. It affects the skin and, in a high percentage of the patients, the central nervous system, eyes and skeleton as well. The skin manifestations are typically spread along the lines of Blaschko, and at birth there are mostly vesicles that then pass through a wart stage into pigmented lesions. Occasionally there may be pigmentation from birth. Behçet's syndrome is rare in children. It consists of recurrent oral aphthae, genital ulcers and ocular lesions. There may also be a pustular skin eruption and occasionally there are other articular, neurological, intestinal or vascular abnormalities.

The ethiopathogeneses of both diseases are unknown. In both syndromes there are some immunological abnormalities.

CASE REPORT

A female child had hyperpigmented skin lesions in lines over her entire body from the first weeks of her life (Fig. 1). By the end of the first year, she looked small in height and weight and her bone maturation was retarded. In the following years she had recurrent bronchial and bronchopulmonary infections, inguinal abscesses and a perianal abscess. From the age of five she developed ulcers of the labia majora and in the perianal region. These lesions (Fig. 2) had purulent floor, hard, eroded and painful borders, and tended to grow in a few days, then heal to atrophic scars in about 15-20 days. In the following months she also developed aphthae on the oral mucosa and purulent blepharconjunctivitis (Fig. 3). Abdominal symptoms, which she had already had in her early months of life, became worse after six years of age, with frequent episodes of diarrhoea, vomiting and colicky pain.

The investigations of the digestive tract showed: colitis, sigmoiditis, anal canal narrowed by circles of scar tissue, and pseudopolyps of sigma. Brain CAT scan revealed: slight dilation of the subaracnoid spaces of the brain convexity. Eye examination showed ulcerative blepharitis and dendritic corneal areas.

The immunological studies showed: a slight hypergammaglobulinemia. IgA 820 mg% (normal range (n.r.) 47-206 mg%), IgG 3 500 mg% (n.r. 744-1 300 mg%), IgM 362 mg% (n.r. 59-150 mg%), IgE 1 400 U/ml (normal up to 100 U/ml). RAST for Gramineae + + +, Aspergillus +, milk + +, eggwhite + + +, *Alternaria Tenuis* +, *Dermatophagoides Pteronyssimus* +. C₃ 155 mg% (n.r. 80-140 mg%), C₄ 80 mg% (n.r. 20-50 mg%). CH₅₀ 1 481 U/ml (control 1 378 U/ml). Circulating immune complexes 0.49 (normal 0.12). Intradermal tests with tuberculin and saline were negative, with antipyrogen vaccine and candidine positive. E rosettes 55% (normal 60 ± 10%). Lymphocyte response to phytohemagglutinin stimulation was normal.

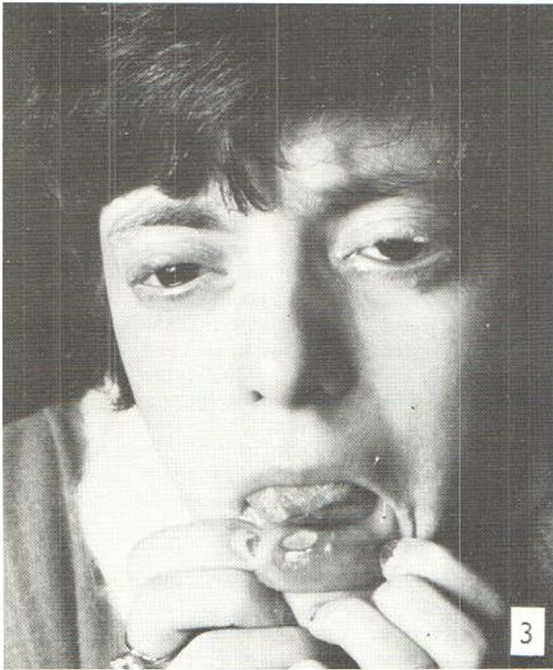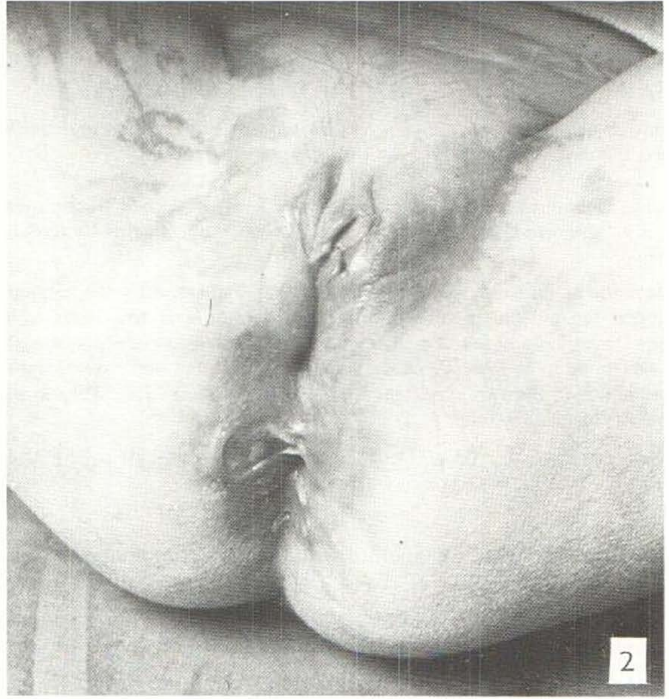
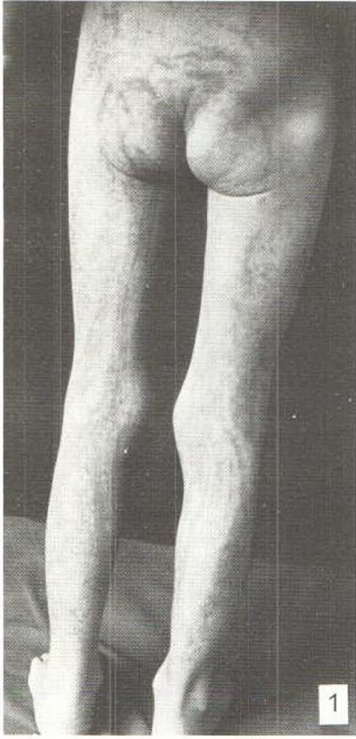


Fig. 1. Typical linear pattern of hyperpigmented lesions of *incontinentia pigmenti* on lower limbs.

Fig. 2. Ulcers and atrophic scars in perianal and labia majora areas.

Fig. 3. Aphthae of oral mucosa and blepharoconjunctivitis.

Granulocyte function tests: NBT test within normal limits, phagocytosis and killing of *Candida albicans* were normal. Deficient chemotaxis of polymorphonuclear neutrophils (39%, normal 70%) was revealed in repeated tests, performed using Boyden's method (1).

The child had many different treatments: thalidomide, zinc sulfate, with a moderate improvement of ulcerative lesions, and levamisole, that normalized the chemotaxis of polymorphonuclear neutrophils. At the age of 11 the child died. Autopsy showed diffuse peritonitis, chronic purulent enterocolitis, interstitial pneumonia and bronchopneumonia with abscesses, subglissonian and portal hepatic microabscesses and acute gastritis.

DISCUSSION

Some investigators (2) think that the clinical picture of incontinentia pigmenti is the result of an autoimmune reaction against ectodermic cellular clones that develop during fetal life and have surface antigens that are abnormal, because of a mutated X chromosome. The lack of immune tolerance is explained as due to a delayed expression of the modified antigens or to the appearance of a 'prohibited' antigen on the surface of the ectodermic cells.

Two other cases with defective leukocyte chemotaxis like that in our patient have been described in the literature (3, 4). One of these also had abnormal lymphocyte function (4). The recurrent infections in these three patients could be explained on this basis.

There are many data in the literature demonstrating involvement of the immune system in Behçet's syndrome: the pathergy; the high levels of IgM, IgG and IgA; high titers of circulating immune complexes, high serum levels of C₉ (5, 6), and increased leukocyte chemotaxis, even though investigators are not certain whether this reflects a leukocyte or a serum abnormality (6, 7). In some other cases, however, decreased chemotaxis has been found (8).

The co-existence of the two syndromes appears to be a chance occurrence. There have been no studies of histocompatibility antigens in incontinentia pigmenti indicating that it is related to Behçet's syndrome (9). However, recently Ammann et al. (10) have reported six cases of children affected by Behçet's syndrome, two of whom showed an association with incontinentia pigmenti.

The presence of an impaired leukocyte chemotaxis in a patient affected by two diseases, both associated with this immunological abnormality, seems to suggest a common pathogenetic basis.

REFERENCES

1. Boyden S. The chemotactic effect of mixtures of antibody and antigen on polymorphonuclear leukocytes. *J Exp Med* 1962; 115: 453-466.
2. Person JR. Incontinentia pigmenti: A failure of immune tolerance? *J Am Acad Dermatol* 1985; 13: 120-123.
3. Dahl MV, Matula G, Leonards R, Tuffanelli DL. Incontinentia pigmenti and defective neutrophil chemotaxis. *Arch Dermatol* 1975; 111: 1603-1605.
4. Jessen RT, van Epps DE, Goodwin JS, Bowerman J. Incontinentia pigmenti. Evidence for both neutrophil and lymphocyte dysfunction. *Arch Dermatol* 1978; 114: 1182-1186.
5. Haim S, Gilhar A. Clinical and laboratory criteria for the diagnosis of Behçet's disease. *Br J Dermatol* 1980; 102: 361-363.
6. Jorizzo JL, Hudson R, Schmalstieg FC, Daniels JC, Apisarnthanarax P, Henry JC, Gonzalez EB, Ichikawa Y, Cavallo T. Behçet's syndrome: Immune regulation, circulating immune complexes, neutrophil migration and colchicine therapy. *J Am Acad Dermatol* 1984; 10: 205-214.
7. Djawari D, Hornstein P, Schötz J. Enhancement of granulocyte chemotaxis in Behçet's disease. *Arch Dermatol Res* 1981; 270: 81-88.
8. Lehner T, Barnes CG. Behçet's syndrome: clinical and immunological features. In: Lehner T, Barnes CG, eds. *Behçet's syndrome*. London, New York: Academic Press. 1979: 74-77.

9. Haim S, Gideoni O, Barzilai A. The histocompatibility antigens in patients with Behçet's disease. *Acta Derm Venereol (Stockh)* 1977; 57: 243-245.
10. Ammann AJ, Johnson A, Fyfe GA, Leonards R, Wara D, Cowan MJ. Behçet syndrome. *J Pediatr* 1985; 107: 41-43.

Palmoplantar Keratoderma in Association with Myxedema

EMMILIA HODAK, MICHAEL DAVID and ELEASAR J. FEUERMAN

Department of Dermatology, Beilinson Medical Center, Petah Tikva, and the Sackler School of Medicine, Tel Aviv University, Israel

Hodak E, David M, Feuerman EJ. Palmoplantar keratoderma in association with myxedema. *Acta Derm Venereol (Stockh)* 1986; 66: 354-357.

A 63-year-old female who had been suffering from intractable palmoplantar keratoderma for 13 years was found to have myxedema. Shortly after institution of substitution therapy with thyroid hormone there was a striking improvement in her condition. The possibility of a causal relationship between hypothyroidism and hyperkeratosis is suggested. *Key words: Hyperkeratosis; Dorsal hands and feet; Thyroid hypofunction.* (Received February 7, 1986.)

E. Hodak, Department of Dermatology, Beilinson Medical Center, Petah Tikva 49100, Israel.

The epidermal signs accompanying primary hypothyroidism such as dryness and ichthyosiform changes are well documented in the literature, affecting over 80% of the patients (1). In contrast, hyperkeratosis of soles and/or palms in association with hypothyroidism is extremely unusual, and to the best of our knowledge this has been reported on only two occasions (2, 3). Hereby we present an additional case exhibiting such an association.

CASE REPORT

A 63-year-old female was evaluated for a 13-year history of severe disabling hyperkeratosis of the hands and feet, unresponsive to keratolytic and steroid topical treatments. Her past and family history was not contributory. Upon questioning the patient admitted that she was tired and lethargic. She also noted a change in her voice, considerable gain in weight and generalized stiffness of joints for several years. Menopause had occurred at the age of 50. On physical examination she was mentally alert but seemed extremely slow in her responses with hoarse voice and slow speech. Ankle jerks revealed a slow relaxation phase. Examination of the skin disclosed: periorbital edema, coarse hair, rough, dry, yellowish skin particularly over the extensor surfaces of the limbs and keratotic papules on the elbows. The skin of the soles showed diffused hyperkeratosis, extending to the lateral aspects of the sole, over the ankles and digits forming gray-violaceous verrucous masses (Fig. 1A). There were hyperkeratotic plaques on the hands, particularly on the dorsal surface.

Routine blood tests disclosed elevated cholesterol and skeletal muscle enzyme levels. The serologic tests for syphilis and latex test were negative. The endocrine function tests showed free T₄ 0.5 ng/dl (normal: 0.8-2.4) and TSH 60 micro units/ml (normal: 0.5-4).

Two biopsies obtained from the skin of the ankle and the wrist showed an identical picture of marked hyperkeratosis, acanthosis, papillomatosis and hypergranulosis. Foci of