

Skin Tumors and Reactive Cellular Infiltrate: Further Studies*

J. C. CLAUDATUS Jr, R. d'OVIDIO, M. LOSPALLUTI
and C. L. MENEGHINI

Department of Dermatology, University of Bari, Bari, Italy

Claudatus JC Jr, d'Ovidio R, Lospalluti M, Meneghini CL. Skin tumors and reactive cellular infiltrate. *Acta Derm Venereol (Stockh)* 1986; 66: 29-34.

Twenty-two non-ulcerated basal cell carcinomas and 30 non-ulcerated squamous cell carcinomas were selected to study the reactive cellular infiltrate, utilizing histological, histoenzymatic and immunological methods. Substantial differences in cell behaviour were observed between the two tumors: advanced and metastatic squamous cell carcinoma showed prominent presence of T8+ lymphocytes, Leu 7+ cells, macrophages, mast cells and granulocytes, notably eosinophils. Degranulation of mast cells was seen both in the tumor itself and in the adjacent stroma. The basal cell carcinoma presented a low count of T4+, T8+ lymphocytes, whereas Leu 7+ cells and granulocytes were absent. *Key words:* Skin tumors; Cellular infiltrate. (Received July 25, 1985.)

J.C. Claudatus Jr, Clinica Dermatologica, Università di Bari, Policlinico, Pza. G. Cesare, 70124 Bari, Italy.

The question as to whether the infiltration of reactive cells in cancer tissue is merely an epiphenomenon of the underlying disease or rather an active participant in determining the fate of the neoplasia has once again become a much debated current issue, especially in view of the increasing knowledge and understanding of the individual cells. In this sense, T and B lymphocytes, NK cells, macrophages, granulocytes (1), Langerhans' cells and mast cells (2) are being scrutinized for their potential role. The interdependence of these cells, the release of both tumor and host cell derived factors, the alteration of the connective tissue and the microambient are but some of the general aspects of this extremely complicated and multifaceted problem, yet to be resolved (3, 4, 5).

As a consequence we thought it opportune to compare two seemingly opposed models of cutaneous tumoral behaviour: the basal cell carcinoma (BCC) versus the squamous cell carcinoma (SCC), and to characterize more precisely the infiltrating immunocompetent cells by adopting immunohistological methods with various kinds of monoclonal antibodies, histoenzymatic and common histological techniques. On the basis of the results obtained, an attempt to interpret the possible interrelationship between the host cells and the neoplasia and their function is postulated.

MATERIALS AND METHODS

Fifty-two biopsy samples of non-ulcerated BCC and SCC were obtained from 49 patients (37 males and 12 females), aged 45-75 yrs. Three patients presented both types of tumors contemporaneously. The histopathology is reported in Table I. Samples were divided into two parts and successively fixed in formaldehyde or snap frozen in liquid nitrogen and stored at -70°C. Formaldehyde-fixed specimens were used for *routine histology*, i.e. hematoxylin-eosin and toluidine blue.

Histoenzymatic techniques

Cryo-fixed biopsies were sectioned at 3 microns on a cryostat and subjected to the following procedures:

* The data of this paper were presented in part at the III International Congress of Inflammation in Paris, September 3-7, 1984.

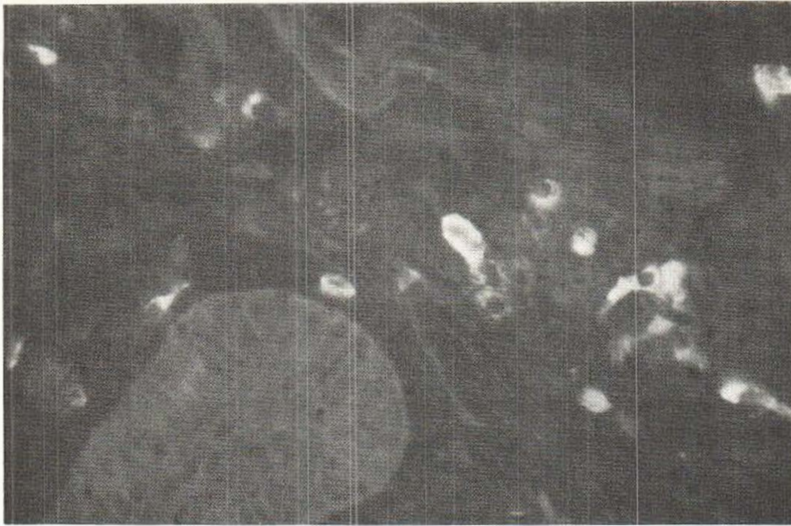

Fig. 1. Peritumoral mast cells in basal cell carcinoma (immunofluorescence): membrane IgE are homogeneously distributed.

1) the method of Yam (6) was used to reveal alpha-naphthyl acetate activity (alpha-NAE) which visualizes monocytes and macrophages;

2) the method of Wong (7) was utilized to evidence chloracetate activity (CAE) indicative of mast cells. Granulocytes may also be positive, but tend to stain less intensely (personal experience);

3) the method of Breton-Gorins (8) was carried out to evaluate peroxidase activity. Eosinophils stain intensely, whereas neutrophils give a moderate positivity.

Immunofluorescence

Monoclonal antibodies OKT3 (Pan T lymphocytes), OKT4 (helper/inducer T subset), OKT8 (suppressor/cytotoxic T subset), OkIa1 (B and activated T lymphocytes, monocytes) were purchased from the Orthomune Co., Raritan, N.J., USA. Monoclonal antibodies Leu 7 (killer/natural killer cells) and Leu M₂ (HLA DC-DS positive, antigen presenting monocytes) were obtained from the Becton Dickinson Co., Mountain View, Ca., USA. Rabbit anti-human kappa-lambda and anti-human IgE antisera were purchased from Behringwerke AG, Marburg, W. Germany.

Cryostated samples were incubated with the monoclonal antibodies and/or antisera, respectively, for 30 min, then rinsed and incubated with second step reagent corresponding to an anti-rabbit IgG or anti-mouse IgG or IgM antiserum, conjugated with fluorescein isothiocyanate or rhodamin isothiocyanate, respectively. Some samples were incubated with both types of conjugated serum to obtain a double-labelled immunofluorescence. (The antisera were obtained from Bionetics, Kensington, MD, U.K.)

RESULTS

All forms of BCC presented a similar cellular infiltrate pattern and thus will be described as the BCC in general. The exceptions which were observed are dealt with in the text.

The monoclonal antibody OKT3 demonstrated the presence of numerous T lymphocytes distributed throughout the neoplasia and the stroma in the BCC and SCC. The helper/inducer subset (OKT4+) exceeded the cytotoxic/suppressor subset (OKT8+) in the BCC, and in the initial stages of the SCC, preferring the periphery, whereas OKT8+ cells predominated in advanced and metastatic SCC, infiltrating both the tumor and the surrounding stroma.

NK/K cells (Leu 7+) were virtually undetectable in BCC, but tended to follow the OKT8+ cell behaviour and distribution pattern in SCC, though minor in number. Interesting to note was the appearance of these cells in three cases of basosquamous cell carcinoma.

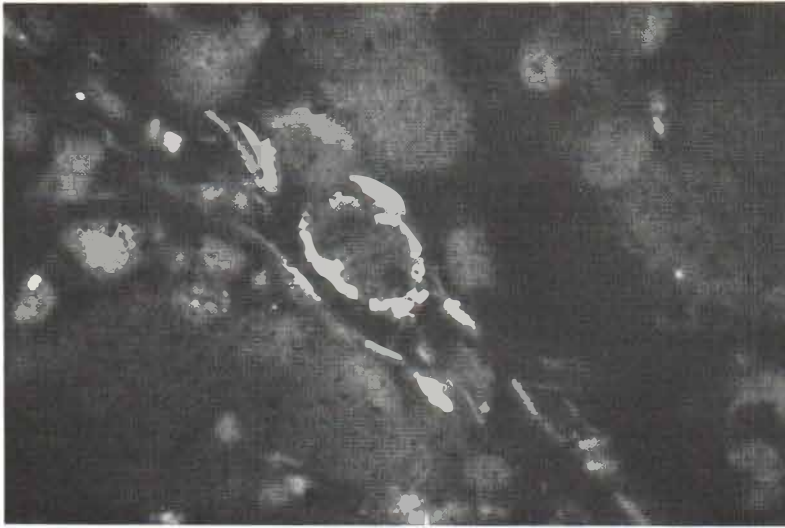


Fig. 2. Intratumoral mast cell in squamous cell carcinoma (immunofluorescence): note granular pattern of membrane IgE.

A heterogeneous population of cells was positive with the monoclonal antibody OKIa1 in both types of tumors. The cells were mainly elongated, corresponding to macrophages, histiocytes and Langerhans' cells (the latter present in the epidermis adjacent to the tumor, but not overlying the tumor), but also small, modestly fluorescent round cells, indicative of activated T and B cells. In both BCC and SCC, Ia+ cells were scattered throughout the stroma and the neoplasia. It should be added that in some cases of SCC the tumoral cells gave a weak Ia-positivity.

Leu M₂ cells were virtually absent in all forms of SCC, whereas these cells were observed surrounding the tumoral islets in the BCC. Giant cells, found both in BCC (of the pigmented type) and SCC, proved to be Leu M₂ negative.

Anti-IgE antisera revealed the presence of positive cells in both types of tumors. In BCC membrane fluorescence was homogeneously distributed on large cells, which occupied the peripheral connective tissue and were demonstrated to be mast cells histo-enzymatically. In some cases, presenting areas of necrosis within the tumor, IgE+ cells were also Ia+ and histoenzymatic alpha-NAE staining proved these cells to be macrophages. On the other hand, IgE positivity was different in SCC. Here, staining was granular, not homogeneous, covering both small (located within the tumor itself) and larger cells (situated in the surrounding connective tissue, subcutis and along the underlying muscle fibers). Both types of cells stained with CAE, meaning that they were mast cells.

Table I. *Histopathology*

Basal cel carcinoma	No. of cases	Squamous cell carcinoma	No. of cases
Solid	12	Initial	9
Pigmented	1	Grade 2 (Broders)	4
Cystic	2	Grade 3	6
Basosquamous	3	Grade 4	5
Sclerodermiform	1	Indifferentiated	3
Superficial	3	Metastatic	3
Total	22		30

B lymphocytes and plasma cells reacted with anti-kappa lambda antiserum. These cells were observed throughout the stroma of both types of neoplasias, though more numerous in the BCC, where they tended to cluster into groups, sometimes even forming lymphatic-like follicles. Peroxidase-positive cells were negligible in non-ulcerated BCC, whereas in SCC infiltration varied notably, predominating in areas of necrosis. Furthermore, these cells were present also in and around horn pearls. Eosinophils, in particular, were relatively numerous, as confirmed by I.F. (autofluorescence), and hematoxylin-eosin staining. Histochemical alpha-NAE showed both tumors to be particularly rich in monocytes and macrophages, scattered about in the peri- and intratumoral connective tissue, becoming more numerous as the degree of malignancy increased to finally invade the tumor itself. Multinucleated giant cells were observed in pigmented BCC, apparently in correlation to the presence of melanin and keratin; such cells were also variably present in differentiated SCC, infiltrating the horn pearls or around areas of necrosis.

CAE-positive cells (mast cells) were consistently present in both tumors, tending to increase as the degree of malignancy worsened. In BCC these cells were mainly concentrated in the peritumoral stroma, occasionally within the tumor mass and often showing signs of degranulation. BCC connective tissue characteristically stained metachromatically with Toluidine Blue. In the sclerodermiform type, mast cells were extremely numerous, predominating all other infiltrating cell populations. The SCC, on the other hand, presented these cells within the tumor mass; the more malignant the tumor form, the more heterogeneous the mast cell population became, showing large elements distributed within the underlying muscle fibers, throughout the subcutis, and within the dermis peritumorally, and smaller elements infiltrating the tumoral cords, even in early forms of SCC. Furthermore, mast cells were always observed disposed peripherally to areas of necrosis, usually degranulating, but never in the central cores of lytic zones, where only debris, macrophages, lysed tumoral and inflammatory cells, and PMNs were present.

DISCUSSION

The comparison of the two tumor models reveals the interesting finding that each neoplastic growth seems to present its own specific infiltrate, whereby intermediate forms, such as the basosquamous cell carcinoma, tend to resemble the more malignant forms. Furthermore, the observation of three patients presenting both types of tumors contemporaneously, and once again, the demonstration that each individual tumor had the infiltrate characteristic of that specific type of tumor (i.e. BCC or SCC), seems to indicate the important role played by the tumor itself in inducing a reactive response, and therefore the type of infiltrate seems to depend on the type of tumor and not on the host.

At this point the question arises: what consequences could this infiltrate have in determining the fate of the tumor? BCC differ from SCC in that they present an OK-T4/OKT8 ratio superior to the unit, but do not present Leu 7+ cytotoxic cells. Furthermore, mast cells are represented by large, mature elements, showing evidence of degranulation. The SCC, on the other hand, has a heterogeneous population of degranulating mast cells (seemingly more numerous than in BCC), which tend to infiltrate the neoplasia even in the initial stages, possibly reflecting the first defense mechanism utilized by the host against the neoplasia (9). With anti-IgE antibodies another important clue is revealed: IgE are homogeneously distributed over the mast cell membrane in BCC, whereas they show a granular pattern in SCC (see Figs. 1-2). This finding could be the evidence of two different types of stimuli of tumoral origin: that the tumor is implicated in inducing this response seems to be supported by the fact that mast cells in adjacent healthy dermis were not found to have membrane IgE. It could therefore be suggested that granular distribution of

IgE on mast cells in SCC is indicative of immunological activation, whereas the homogeneous distribution pattern observed for mast cells in BCC could merely be the result of polyclonal Ig production on behalf of the numerous plasma cells recluted in situ. Furthermore, as is known (10), depending on the type of stimulus, specific mediators are secreted by mast cells and this could also occur in tumors, thus conditioning microambient conditions and the type of response observed.

Macrophages are numerous in both types of tumors, where they seem to be simply scavengers; yet, together with mast cells and granulocytes, they are important sources of proteolytic enzymes, which could be implicated in lysing the neoplastic cells, but at the same time could favour the diffusion of metastatic cells. The fact that the SCC do not present HLA-DC/DS positive monocytes (i.e. antigen-presenting cells), contrary to what is found in BCC, seems to support the hypothesis that these cells are secreting scavenger cells (5).

Cytotoxic cells are detectable in SCC, indicative of the host's defense mechanism (11), but the presence of mediators such as histamine, heparin, PGs, known to have an immunosuppressive action at physiologic doses, could inactivate their cytotoxic function (12, 13, 14, 15, 16). This concurs with what has been reported in the literature so far, where cells extracted from autologous tumors exhibit reduced cytotoxic activity, even though the peripheral blood cells of the same subject proved to be cytotoxic (17, 18, 19).

Thus, it would seem that the poor results obtained with the various immune therapies adopted so far may be explained by the fact that important events occurring in the microambient of the tumor have been given too little consideration.

ACKNOWLEDGEMENT

This work was supported by the Consiglio Nazionale delle Ricerche (CNR), Rome, Italy: Special project "Control of Neoplastic Growth".

REFERENCES

1. Cohen S, Cohen MC. Mechanisms of tumor immunity. An overview. *Am J Pathol* 1978; 93: 449-457.
2. Hartveit F, Sandstad E. Stromal metachromasia: a marker for areas of infiltrating tumor growth? *Histopathology* 1982; 6: 423-428.
3. Benjamini E, Rennick DM, Sell S. Tumor immunology. In: Stites DP, Stobo JD, Fudenberg HH, Wells JV, ed. *Basic and clinical immunology*. Lange Med Publ 1982: 233-244.
4. Prehn RT, Lappe MA. An immunostimulation theory of tumor development. *Transplant Rev* 1971; 7: 26-30.
5. Liotta LA, Rao CN, Barsky S. Tumor invasion and extracellular matrix. *Lab Invest* 1983; 49: 636-649.
6. Yam LT, Li CY, Crosby WH. Cytochemical identification of monocytes and granulocytes. *Am J Clin Pathol* 1971; 55: 283-286.
7. Wong E, Morgan EW, MacDonald DM. The chloracetate esterase reaction for mast cells in dermopathology: a comparison with metachromatic staining methods. *Acta Derm Venereol (Stockh)* 1982; 62: 431-437.
8. Breton-Gorins J. Mise en évidence des activités peroxydasiques endogènes des cellules animales. *J Microscopie* 1974; 21: 275-280.
9. Van Loveren H, Den Otter W, Meade R, Terheggen PMAB, Askenase PW. A role for mast cells and the vasoactive amine serotonin in T cell-dependant immunity to tumors. *J Immunol* 1985; 134: 1292-1299.
10. Morrison D. Receptor modulation and mast cell secretion. *J Invest Dermatol* 1978; 71: 85-91.
11. Nairn RC, Nind APP, Guli EPG, Muller HK, Rolland JM, Minty CCJ. Specific immune response in human skin carcinoma. *Br Med J* 1971; 4: 701-705.
12. Askenase PW, Schwartz A, Siegel JN, Gershon RK. Role of histamine in the regulation of cell-mediated immunity. *Int Archs Allergy Appl Immunol* 1981; 66 (Suppl 1): 225-233.

13. Wesolowski J, Ault K, Houghton R, Parkman R. Heparin inhibition of antibody-dependant complement-mediated lysis. *Exp Hematol* 1984; 12: 700-705.
14. Goodwin JS, Kaszubowski PA, Williams RC Jr. Cyclic adenosine monophosphate response to prostaglandin E₂ on subpopulations of human lymphocytes. *J Exp Med* 1979; 150: 1260-1264.
15. Hartveit F. Mast cell and metachromasia in human breast cancer: their occurrence, significance and consequence: a preliminary report. *J Pathol* 1981; 134: 7-11.
16. Schwartz LB, Austen KF. Structure and function of the chemical mediators of mast cells. In: Ishizaka K, ed. *Progress in allergy: Mast cell activation and mediator release*. Karger 1984: 271-321.
17. Hibbs JB Jr, Chapman HA Jr, Weinberg JB. Macrophage tumor killing: influence of the local environment. *Science* 1977; 197: 279-282.
18. Moore M, Vose BM. Extravascular natural cytotoxicity in man: anti-K 562 activity of lymph node and tumor infiltrating lymphocytes. *Int J Cancer* 1981; 27: 265-272.
19. Moy PM, Golub SH, Holmes EC. Inhibition of NK cell recycling in tumor infiltration lymphocytes from human lung cancers. *Proc Annu Meet Am Assoc Cancer Res* 1984; 25: 269.