

Fungal Infections Inducing HLA-DR but not HLA-DQ Transplantation Antigens on Keratinocytes

SIV JOHANSSON,¹ ANNIKA SCHEYNIUS¹ and JAN FAERGEMANN²

¹*Institute of Clinical Bacteriology, University of Uppsala, and* ²*Department of Dermatology, University of Gothenburg, Sweden*

Johansson S, Scheynius A, Faergemann J. Fungal infections inducing HLA-DR but not HLA-DQ transplantation antigens on keratinocytes. *Acta Derm Venereol (Stockh)* 1986; 66: 277-280.

The phenotypes of infiltrating cells and class II transplantation antigens on keratinocytes in candida and dermatophyte lesions from 15 patients were analysed *in situ* with an immunohistochemical double staining technique combined with periodic acid-Schiff staining. In five out of ten biopsies from candida lesions and in one of five biopsies from dermatophyte lesions the keratinocytes expressed HLA-DR but not HLA-DQ antigens. The HLA-DR expression was patchy in all and most pronounced in two candida biopsies which also contained large infiltrates of anti-Leu 3a reactive T lymphocytes. The induction of detectable amounts of different class II antigens on keratinocytes might depend on the type of antigen, the magnitude and duration of the response elicited and/or the immunological state of the patient. *Key words: Skin biopsies; Class II antigens; Cellular infiltrate.* (Received November 11, 1985.)

S. Johansson, Institute of Clinical Bacteriology, Box 552, S-751 22 Uppsala, Sweden.

Dermatophyte infections and candida intertrigo are the most frequent fungal infections in skin. Candida intertrigo is often very red, moist, with pustules and typically located in the groins, axillae or, in women, beneath the breasts. Dermatophyte infections in the groins (tinea inguinalis) are more dry and scaly especially *Trichophyton rubrum* infections, but *Epidermophyton floccosum* infections may be more red, moist and less scaly.

In pityriasis versicolor, a less inflammatory fungal disease, we have previously observed moderate dermal cell infiltrates dominated by anti-Leu 3a reactive cells (1). A similar pattern of infiltrating cells was found in Pityrosporum folliculitis lesions. The cell infiltrates were, however, larger than in pityriasis versicolor lesions and HLA-DR but not HLA-DQ transplantation antigens were detected (2).

In the present investigation phenotypes of infiltrating cells and class II transplantation antigens on keratinocytes were studied in candida and dermatophyte skin lesions to ascertain whether the magnitude and type of the inflammatory reaction may be responsible for the induction of class II antigens on keratinocytes.

MATERIALS AND METHODS

Characteristics of patients

Ten patients, mean age 69 years, with candida intertrigo and five patients, mean age 29 years, with dermatophyte infections in the groins were included in the study.

Culture of candida and dermatophytes

Culture specimens were taken from lesions in all patients. Sabouraud, DTM and Grütz-Kimmig agar plates were inoculated. The plates were incubated at 32°C and were examined for 3 weeks. The final diagnosis was made by means of microscopy and/or biochemical tests.

Skin biopsies

Three mm punch biopsies were taken from both lesions and normal-looking skin in all patients. The specimens were kept in Histocon® (Histolab, Bethlehem Trading Ltd., Gothenburg, Sweden) at 4°C for not more than 24 hours and were then frozen and cut in a cryostat (3).

Immunohistochemical staining

Mouse monoclonal antibodies denoted anti-HLA-DR, anti-Leu 10 (specific for HLA-DQ antigens), anti-Leu 1 (all peripheral T cells), anti-Leu 2a ('suppressor/cytotoxic' T cells), anti-Leu 3a ('helper/inducer' T cells; some macrophages and Langerhans' cells) and anti-Leu 6 (reactive with Langerhans' cells) were obtained from Becton Dickinson Corp., Sunnyvale, CA., USA, OKM1 reactive with monocytes/macrophages and granulocytes from Ortho Diagnostic Systems Inc., Raritan, NJ, USA and monoclonal antibodies towards human IgG and IgM heavy chains from Seward Laboratory, London, England. A rabbit antiserum against HLA-DR antigens was generously donated by Dr L. Klareskog (4).

Acetone-fixed skin sections, 4 µm thick, were studied by a sensitive modified double immunoenzymatic staining technique (3) originally described by Mason & Sammons (5). This method permits simultaneous recognition of cells binding mouse monoclonal antibodies (peroxidase-catalysed brown staining) and those binding rabbit anti-HLA-DR antibodies (alkaline phosphatase-catalysed blue staining). The appropriate dilutions of the antibodies (see legends to figures) were determined on sections from normal human lymph nodes and skin. In control experiments staining was not observed when the primary antibodies were omitted or replaced by normal rabbit serum. Routine haematoxylin and eosin staining was also performed on each biopsy.

Periodic acid-Schiff (PAS) staining

After immunohistochemical staining the skin sections were further processed for PAS staining to visualize the presence of fungi. In control experiments PAS staining did not affect the previous immunohistochemical staining or vice versa.

RESULTS

Positive cultures of *Candida albicans* were obtained from all patients with suspected candida intertrigo. In the five patients with suspected dermatophyte infections, *T. rubrum* was cultured in 3 patients and *E. floccosum* in 2 patients.

In all biopsies from lesional skin there was infiltration of anti-Leu 1 reactive T lymphocytes in both dermis and epidermis. Candida lesions showed larger cell infiltrates than dermatophyte lesions. The majority of the T lymphocytes expressed anti-Leu 3a antigen, whereas anti-Leu 2a reactive cells were few and scattered. The numbers of anti-Leu 6 reactive Langerhans' cells and OKM1 reactive cells were enhanced in the dermis. There were no clear differences between the numbers or locations of epidermal anti-Leu 6 reactive cells in the lesions and normal-looking skin. A close spatial relation of Leu 6 expressing cells to fungi was observed in two of the five biopsies from dermatophyte lesions (Fig. 1). Immunoglobulin-bearing cells were rare in both the biopsies from lesions and in normal-looking skin.

In five of the ten biopsies from candida lesions and in one of five biopsies from dermatophyte lesions the keratinocytes expressed HLA-DR but not HLA-DQ antigens (Figs. 2a and 2b). The HLA-DR expression on the keratinocytes was patchy in all and most pronounced in two candida biopsies which also contained large infiltrates of T lymphocytes.

DISCUSSION

The human class II transplantation antigens are coded for by at least three distinct loci on the sixth chromosome: HLA-DR, -DQ and -DP (6). The HLA-DR antigens are the best characterized as to distribution and function, and are mainly found on cells belonging to the immune system (6, 7). Induced expression of HLA-DR antigens on non-lymphoid cells

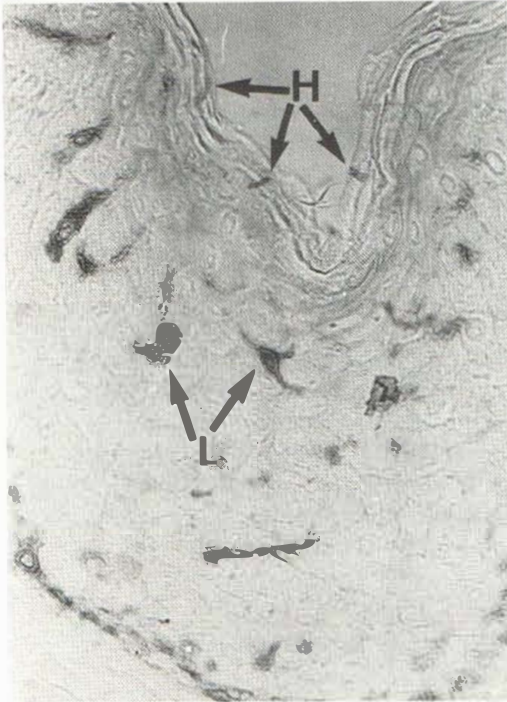
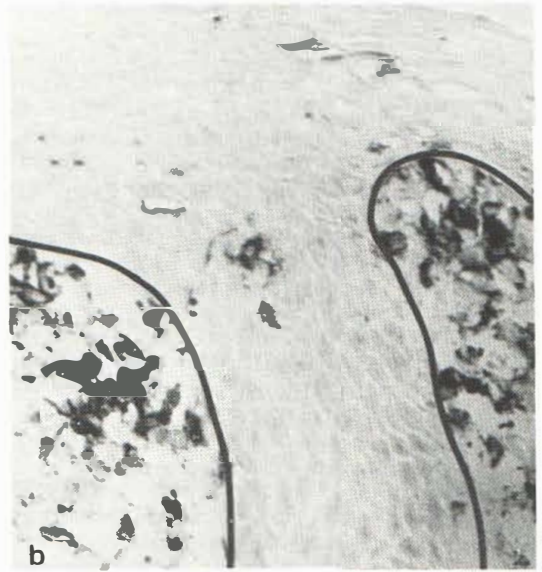
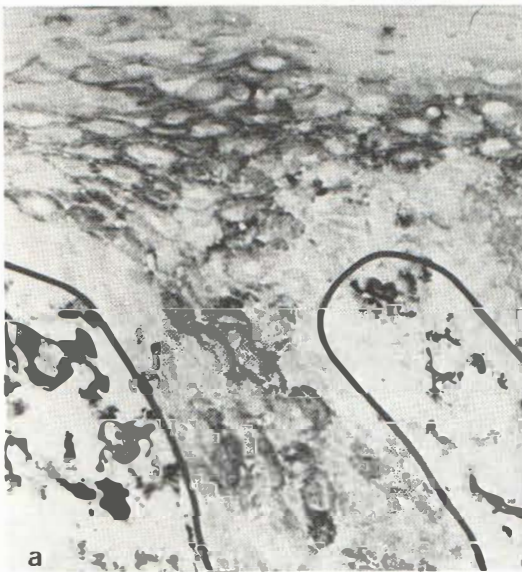
Fig. 1. Combined immunoperoxidase and PAS staining on a frozen section of a skin biopsy from a dermatophyte lesion. Lagerhans' cells reactive with anti-Leu 6 antibodies (diluted 1/64) are marked *L*. The hyphae are marked *H*.

Fig. 2. Immunoperoxidase staining on serial frozen sections of a skin biopsy from a candida lesion. (a) Cells reacting with mouse monoclonal anti-HLA-DR antibodies (diluted 1/128) and (b) with anti-HLA-DQ (Leu 10) antibodies (diluted 1/128). The solid lines indicate the epidermal basal membrane zone.



is described in autoimmune disorders, delayed type of hypersensitivity reactions and in infections (7). The function of class II molecules on epithelial cells is not understood but may be related to the regulation of immune responses such as the protection of the individual against microorganisms.

We here report on the induction of HLA-DR antigens on keratinocytes in candida and dermatophyte infections. It is noteworthy that the lesions which showed this pattern also

possessed large cell infiltrates dominated by anti-Leu 3a reactive cells. This is similar to our previous observation in *Pityrosporum* folliculitis lesions (2). γ -interferon has been shown to be a potent inducer of HLA-DR expression on keratinocytes in tissue cultures (8). This lymphokine might be released *in vivo* from activated infiltrating T lymphocytes thereby, when in sufficient numbers, inducing HLA-DR antigens on keratinocytes.

In agreement with a recent report (9) we observed anti-Leu 6 reactive Langerhans' cells in close spatial relation to fungi in two of the biopsies from dermatophyte lesions supporting the notion of an antigen presenting situation. Langerhans' cells have *in vitro* been shown capable of inducing T cell response to trichophytin in dermatophytosis (10). Direct contact *in situ* with the fungi is however probably not necessary since antigenic products may be liberated (11).

HLA-DQ expression on keratinocytes was not detected in the present study. This is in agreement with earlier reports (2, 12, 13). However, we recently observed HLA-DQ antigens on strongly HLA-DR expressing keratinocytes in the late skin manifestations of a *Borrelia* spirochete infection (14). The induction of detectable amounts of different class II antigens on keratinocytes may thus depend on the type of antigen, the magnitude and duration of the response elicited and/or the immunological state of the patient.

ACKNOWLEDGEMENTS

Excellent technical assistance was given by Ann-Kristin Ulfgren and Catharina Johansson. This work was supported by grants from the Swedish Work Environment Fund, Edward Welander's Foundation and Anders Otto Svård's Foundation.

REFERENCES

1. Scheynius A, Faergemann J, Forsum U, Sjöberg O. Phenotypic characterization *in situ* of inflammatory cells in pityriasis (tinea) versicolor. *Acta Derm Venereol (Stockh)* 1984; 64: 473-479.
2. Faergemann J, Johansson S, Bäck O, Scheynius A. An immunological and cultural study of *Pityrosporum* folliculitis. *J Am Acad Dermatol* (in press).
3. Scheynius A, Klareskog L, Forsum U. *In situ* identification of T lymphocyte subsets and HLA-DR expressing cells in the human skin tuberculin reaction. *Clin Exp Immunol* 1982; 49: 325-330.
4. Klareskog L, Trädgårdh L, Lindblom JB, Petterson PA. Reactivity of a rabbit antiserum against highly purified HLA-DR antigens. *Scand J Immunol* 1978; 7: 199-208.
5. Mason DY, Sammons R. Alkaline phosphatase and peroxidase for double immunoenzymatic labelling of cellular constituents. *J Clin Pathol* 1978; 31: 454-460.
6. Möller G, Editor. Molecular genetics of Class I and II MHC antigens 2. *Imm Rev* 1985; 85: 1-149.
7. Forsum U, Claesson K, Hjelm E, Karlsson-Parra A, Klareskog L, Scheynius A, Tjernlund U. Class II transplantation antigens: Distribution in tissues and involvement in disease. *Scand J Immunol* 1985; 21: 389-396.
8. Basham TY, Nickloff BJ, Merigan TC, Morhenn VB. Recombinant γ -interferon induces HLA-DR expression on cultured human keratinocytes. *J Invest Dermatol* 1984; 83: 88-90.
9. Emtestam L, Kaaman T, Hovmark A, Åsbrink E. An immunohistochemical staining of epidermal Langerhans' cells in tinea cruris. *Acta Derm Venereol (Stockh)* 1985; 65: 240-243.
10. Braathen LR, Kaaman T. Human epidermal Langerhans cells induce cellular immune response to trichophytin in dermatophytosis. *Br J Dermatol* 1983; 109: 295-300.
11. Holden CA, Hay RJ, McDonald DM. The antigenicity of *Trichophyton rubrum*: *In situ* studies by an immunoperoxidase technique in light and electron microscopy. *Acta Derm Venereol (Stockh)* 1981; 61: 207-211.
12. Volc-Platzer B, Majdic O, Knapp W, Wolff K, Hinterberger W, Lechner K, Stingl G. Evidence of HLA-DR antigen biosynthesis by human keratinocytes in disease. *J Exp Med* 1984; 159: 1784-1789.
13. Scheynius A, Tjernlund U. Class II transplantation antigens in the late human skin tuberculin reaction. *Scand J Immunol* 1985; 22: 227-233.
14. Tjernlund U, Scheynius A, Åsbrink E, Hovmark A. Expression of HLA-DQ antigens on keratinocytes in *Borrelia* Spirochete induced skin lesions. *Scand J Immunol* (in press).