

## Epidermodysplasia Verruciformis

### *Skin Carcinoma Containing Human Papillomavirus Type 5 DNA Sequences and Primary Hepatocellular Carcinoma Associated with Chronic Hepatitis B Virus Infection in a Patient*

P. C. VAN VOORST VADER,<sup>1</sup> G. ORTH,<sup>2</sup> V. DUTRONQUAY,<sup>2</sup> L. H. H. M. DRIESSEN,<sup>1</sup> H. F. EGGINK,<sup>3</sup> C. G. M. KALLENBERG<sup>4</sup> and T. H. THE<sup>4</sup>

*Departments of <sup>1</sup>Dermatology, <sup>3</sup>Pathology and <sup>4</sup>Immunology, University Hospital Groningen, The Netherlands, and <sup>2</sup>Unité des Papillomavirus, Unité INSERM 190, Institut Pasteur, Paris, France*

van Voorst Vader PC, Orth G, Dutronquay V, Driessen LHHM, Eggink HF, Kallenberg CGM, The TH. Epidermodysplasia verruciformis. Skin carcinoma containing human papillomavirus type 5 DNA sequences and primary hepatocellular carcinoma associated with chronic hepatitis B virus infection in a patient. *Acta Derm Venereol (Stockh)* 1986; 66: 231-236.

In a case of epidermodysplasia verruciformis with impaired cell-mediated immunity and multiple skin cancers human papillomavirus type 5 (HPV5) DNA sequences were demonstrated in a cutaneous squamous cell carcinoma. HPV5 and HPV8 were detected in the benign disseminated skin lesions together with three newly characterized HPV's: HPV17, HPV19 and HPV24. A chronic infection with hepatitis B virus resulting in macronodular cirrhosis associated with a primary hepatocellular carcinoma was also acquired by this patient. This case provides an example of the circumstantial evidence which suggests that certain types of HPV are potentially oncogenic and stresses the importance of immune surveillance in the protection against virus-associated tumors. *Key words: Human papillomaviruses; Hepatitis B virus; Cellular immune deficiency; Viral oncogenesis.* (Received November 8, 1985.)

P. C. van Voorst Vader, Department of Dermatology, University Hospital. P. O. Box 30.001, 9700 RB Groningen, The Netherlands.

Epidermodysplasia verruciformis (EV), described as a new entity in 1922, is caused by a generalized persistent cutaneous infection, usually acquired in childhood, with human papillomaviruses (HPVs) (1). The disease is associated with an impaired non-HPV-specific cell-mediated immune response (2), although exceptions have been reported (3, 4). The viral aetiology of EV was established in 1966 by electron microscopy studies (5). Recently the association of EV with a plurality of specific HPV types has been demonstrated (6-9). The hypothesis that certain HPV types are potentially oncogenic, a well-known characteristic of several animal papillomaviruses (10), has received a great deal of attention lately (11-15). This hypothesis is strongly suggested by the data concerning EV. In about 30% of 147 EV patients reported cutaneous intraepithelial and invasive squamous cell carcinomas were described, usually multiple and located on sun-exposed areas, with an average age of onset of 31 years (1). The genome of HPV type 5 (HPV5) has been detected in primary (16-18) and metastatic (17) skin carcinomas of EV patients, suggesting that HPV5 has an oncogenic potential.

We describe here a case of EV with a persistent hepatitis B virus infection, in which the development of primary carcinomas of the skin as well as the liver was observed. This represents a follow-up study of the patient in whom the presence of papillomavirus particles in EV lesions was demonstrated for the first time (5). We report the characterization of the HPVs in the benign skin lesions and the search for HPV DNA sequences in a cutaneous carcinoma.

## PATIENT AND METHODS

### Patient

A 22-year-old Caucasian male patient with EV since childhood was seen for the first time at the Department of Dermatology in 1965 (5). His skin showed multiple verruca plana-like lesions, partly giving rise to red hyperkeratotic plaques, on the extensor side of the hands and knees, disseminated red-brown macular pityriasis versicolor-like lesions on the trunk and extremities, and greyish-brown hyperkeratotic lenticular lesions on the face. He died in 1981 at the age of 38. During these 16 years the extent and morphology of the lesions did not change markedly, except on the face and scalp, where multiple malignant lesions developed from the age of 22. He was institutionalized elsewhere because of mental retardation. There was no parental consanguinity. One cousin was mentally retarded. The mother died of lung carcinoma. There is one healthy male sibling.

The histology of a lesion on the trunk was typical of EV, showing large clear cells with keratohyalin granules in the upper layers of the epidermis (5). Intraepithelial and invasive squamous cell carcinomas and keratosis actinica-like changes were observed on face and scalp (19). Intranuclear viral particles were demonstrated by electron microscopy in the upper layers of the epidermis in benign lesions (5) and in a carcinoma-in-situ (20), but could not be detected in an invasive squamous cell carcinoma (20).

In 1972 positive antibody responses were obtained after immunization with the primary test immunogen *Helix pomatia* haemocyanin (21) and the following recall antigens: diphtheria, tetanus and typhoid O and H. Subsequent skin tests with *Helix pomatia* haemocyanin, diphtheria, tetanus, tuberculin, candida and mumps were negative. A positive reaction however was obtained after intradermal injection of streptokinase-dornase. Blood chemistry and morphology were normal. In June 1980, a screening for internal disease because of ankle oedema and ascites revealed HBs antigenaemia (HBsAg+, anti HBs-), moderate elevation of the values of alkaline phosphatase, lactate dehydrogenase and  $\gamma$ -glutamyl transferase, normal values of transaminases and a lowered albumin level. The oedema and ascites disappeared after the institution of diuretic therapy and dietary measures, but the laboratory abnormalities persisted. In December 1980, a serological investigation for hepatitis B virus infection gave the following results: HBsAg+, anti HBs-, HBcAg+, anti HBe-, anti HBc+. The  $\alpha$ -fetoprotein level was 266 ng/ml (normal: <20 ng/ml). In April 1981, ascites developed again. In May 1981, an hepatic tumor was palpable, which was confirmed by intravenous technetium colloid scintigraphy, showing a large defect in the left lobe of the liver. In November 1981, aged 38, the patient died because of hepatic insufficiency. Post mortem examination of the liver by light microscopy demonstrated a macronodular cirrhosis associated with a primary hepatocellular carcinoma. Using peroxidase conjugated anti-HBs, anti-HBc and anti-HBe immunoglobulins (Organon, Oss, the Netherlands) HBs antigen was observed in some non-malignant cells, but not in the hepatocellular carcinoma. HBc and HBe antigens were not observed.

### Methods

Scrapings were taken from the back of the hands, which showed mainly confluent verruca plana-like lesions, and from the back of the trunk, which showed pityriasis versicolor-like lesions. Seven months later, at the post mortem examination, scrapings were taken again from the hands, breast and back. A cutaneous carcinoma was excised from the forehead. The scrapings and part of the skin tumor were snap-frozen in liquid nitrogen and stored at  $-70^{\circ}\text{C}$ . Part of the cutaneous carcinoma was embedded in paraffin for routine light microscopy and for immunoperoxidase studies. The skin tumor was screened for papillomavirus genus-specific antigen by the peroxidase-antiperoxidase method, using a rabbit antiserum against bovine papillomavirus type 1 disrupted particles (2, 12).

Viral DNA was selectively extracted from the benign skin lesions and total cellular DNA was extracted from the skin and liver carcinomas as previously described (6-8, 12, 16). The ulcerated central part of the cutaneous tumor and the peripheral part were processed separately. DNAs were cleft with restriction endonucleases PstI, BamHI, EcoRI, and HindII and the fragments were separated by agarose gel electrophoresis and visualized by staining with ethidium bromide. DNA fragments were denatured in situ, transferred to "Gene Screen" hybridization transfer membrane (New England Nuclear) and hybridized with  $^{32}\text{P}$ -labelled cloned probes specific for skin wart HPVs (HPV1, 2, 4) (11) and EV HPVs (HPV3, 5, 8, 9, 10, 12, 14, 15, 17, 19 to 24) (6-8). All procedures have been described previously (6-8, 12, 16). A search for hepatitis B virus DNA in the hepatocellular carcinoma was precluded by degradation of the liver cell DNA.

## RESULTS

In DNA extracted from benign skin lesions two HPV DNAs (HPVX and Y) with PstI (Fig. 1a, b), BamHI, EcoRI and HindII endonuclease cleavage patterns distinct from those

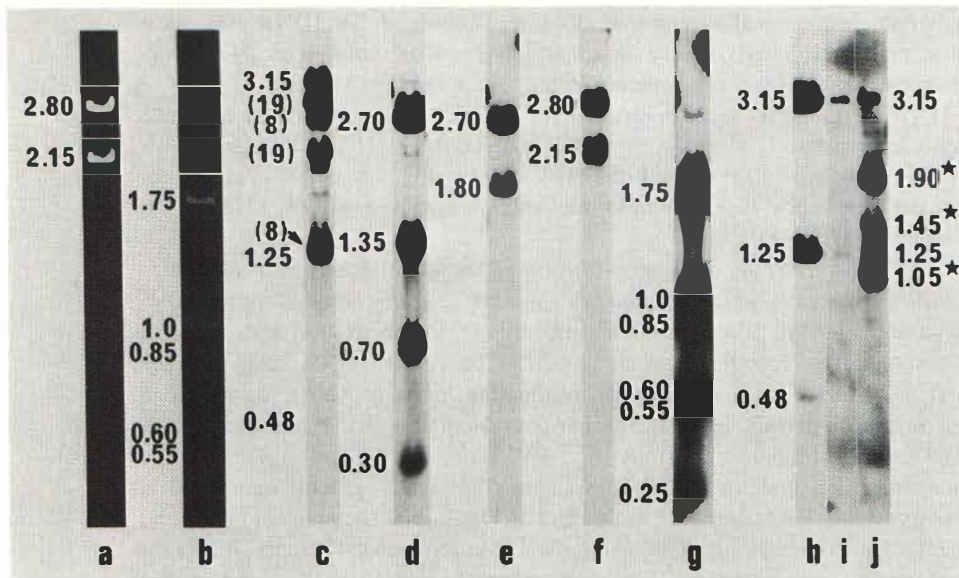


Fig. 1. Identification of HPV types associated with benign lesions and a skin cancer in an EV patient. DNAs extracted from benign lesions of the back (a), the breast (b) and both locations (c-g) and from the center (i) and the periphery (j) of a skin cancer were cleaved with PstI endonuclease and run into an agarose gel (1 µg per lane except for 5 µg in lane j). As a control (h) DNA extracted from the benign lesions of an EV patient infected with prototypical HPV5 (6) (0.5 ng) was run in the same gel as the skin cancer samples. Viral DNA fragments were detected after ethidium bromide staining (lanes a, b) or after transfer to a membrane (lanes c-j) and hybridization with <sup>32</sup>P-labelled cloned probes specific for HPV5 (c, h-j), HPV8 (d), HPV17 (e), HPV19 (f), HPV24 (g). Labeled fragments were detected after exposure on a Kodak AR X-Omat film for 4 hours (f), 24 hours (c, d, g), 3 days (e) or 6 days (h-j). Numerals indicate molecular weights of fragments expressed in megadaltons (Md) corresponding to HPV5 (c, h-j), HPV8 (d), HPV17 (e), HPV19 (a, f), HPV24 (b, g). The smallest HPV5 PstI fragment (0.29 Md) (6) ran out of the gels. Numbers in brackets indicate the types of the viruses whose fragments are revealed with the HPV5 probe. Stars indicate the extra bands found in the sample from the cancer periphery.

reported for already recognized HPVs were detected in large quantities on ethidium bromide-stained agarose gels. HPVX was found to be prominent on the hands and back (Fig. 1a), HPVY on the breast (Fig. 1b). Molecular cloning of the genomes of these viruses led to their characterization as new types, HPV19 and HPV24 respectively, on the basis of less than 50% DNA sequence homology with the genomes of other HPVs, as determined by liquid phase hybridization followed by S1 nuclease analysis (8). HPV19 shows some DNA sequence homology (6 to 28%) with the members of a group of related EV specific HPV types (HPV5, 8, 12, 14, 20 to 23) and no or almost no detectable sequence homology (less than 4%) with other HPVs, including other EV associated HPVs: HPV3 and HPV10 found also in flat warts of the general population, another group of related EV specific HPVs (HPV9, 15, 17) and HPV24 (8). HPV24 shows no or almost no detectable sequence homology with any of the other 23 types of HPVs (8).

Three other HPVs (HPV5, 8, 17), yielding barely detectable bands on ethidium bromide-stained gels (Fig. 1a, b), were detected together with HPV19 and 24 in pooled scrapings after blot hybridization with the different HPV cloned probes (Figs. 1c to g).

The cutaneous carcinoma was shown to be an invasive squamous cell carcinoma by light microscopy. Small foci of large clear cells, i.e. with the features of the cytopathic effect

associated in benign lesions with vegetative DNA replication of EV HPVs (16), were observed in the epidermis overlying the peripheral portion of the cancer. No group-specific papillomavirus antigens were detected in the tumor sections studied.

In the total DNA extracted from the central necrotic part of the tumor and cleaved with different endonucleases, bands with the mobilities expected for HPV5 DNA fragments were detected after blot hybridization with the HPV5 probe (Fig. 1*h, i*). No evidence for the presence of the other HPV types found in the benign lesions, i.e. HPV8, 17, 19 or 24, was obtained using specific probes.

In the DNA extracted from the peripheral portion of the tumor bands with mobilities distinct from HPV5 fragments were detected with the HPV5 probe in addition to HPV5 specific DNA bands (Fig. 1*j*). Blot hybridization of this DNA preparation with different HPV probes revealed the specific cleavage products of HPV17 DNA and, in trace amounts, of HPV 24 DNA (data not shown), originating, most probably, from benign lesions present in the epidermis covering the peripheral portion of the carcinoma. It is unlikely that the additional bands labelled by the HPV5 probe correspond to HPV17 or 24 fragments since they have distinct molecular weights (Fig. 1*e, g, j*) and since there is almost no cross-hybridization between HPV5, 17 and 24 DNAs (8). They could correspond to rearranged HPV5 genomes as observed for some EV carcinomas (17) (and Orth G. et al., unpublished results) or to a sixth HPV, partially related to HPV5 but different from the known HPV types and overlooked in the DNA preparations obtained from pooled scrapings of benign lesions.

## DISCUSSION

In 1979, two clinical phenotypes of EV were distinguished in a study of 14 patients (22). Disseminated verrucae planae on the face and extremities caused by an infection with HPV3 or a related virus, now recognized as HPV10 (7), characterized one phenotype. In the other multiple verruca plana-like lesions on the extremities and the face together with pityriasis versicolor-like lesions on the trunk were observed in conjunction with an infection with HPV5 or HPV5-related viruses. Only this latter phenotype, to which about 75% of EV patients belong (1), appeared to be cancer associated. Our patient clearly belongs to this classical phenotype of EV. At least thirteen other HPVs besides HPV5 have been identified since 1979, i.e. HPV8, 9, 12, 14, 15, 17 and 19 to 25, in the benign lesions of EV patients with pityriasis versicolor-like lesions originating from different parts of the world (6-9) (and Orth G. et al., unpublished results). Often several HPVs were detected in one patient, as in the patient described. These HPVs have not been found so far in the general population, in contrast to HPV3 and 10, which induce flat warts (7). HPV3-induced flat warts were also found in some EV patients with pityriasis versicolor-like lesions (6, 7, 22).

The detection of HPV5 DNA sequences in a cutaneous invasive squamous cell carcinoma in our case of EV supports the hypothesis of the potential oncogenicity of some specific HPVs. HPV5 DNA has been reported to be present in the carcinomas of three EV patients (16-18) and the DNA of HPV5, and less frequently of HPV8 and HPV14 (23), has recently been found in the DNA extracted from cutaneous carcinomas of 14 other EV patients (Orth G. et al., unpublished results). HPV3-related sequences were found in a vulvar carcinoma-in-situ of an EV patient with disseminated verrucae planae (24). In addition the presence of the HPV5 genome has been reported in two skin cancers of a renal allograft recipient with skin lesions resembling the pityriasis versicolor-like lesions of EV (12). The cutaneous malignancies of that patient developed on sun-exposed skin as is the case in the large majority of EV patients with skin carcinomas. Therefore sunlight is suggested as a co-carcinogenic factor (1, 12, 19).

Mental retardation of unknown cause, as observed in the case presented, has been described in 8% of 147 EV patients reported (1). Although sporadic cases constitute the majority of EV patients, the occurrence of familial cases and parental consanguinity and the association with mental retardation suggest a genetic factor in the pathogenesis of EV (1, 23, 25). This genetic factor may be responsible for an immunologically determined persistence of HPV infection in EV patients. Impairment of the non-HPV-specific cell-mediated immune response in our case of EV seems highly probable in view of the negative skin tests performed almost ten years before death. Whether this impairment, which has been frequently reported in EV patients (2, 16), is primary or secondary to the HPV infection is unknown however. When a cellular immune deficiency exists, this not only predisposes to protracted viral infections, but may also facilitate virus-induced tumor growth (26, 27). This seems illustrated in our patient, one of the rare cases of EV with long term follow-up data available (1, 25), by the simultaneous occurrence of an HPV5-associated cutaneous carcinoma and an hepatitis B virus-associated primary hepatocellular carcinoma. The occurrence of a probable Burkitt's lymphoma, an Epstein-Barr virus associated malignant lymphoma, has also been reported in another EV patient (1).

A persistent hepatitis B virus infection, characterized by HBs antigenaemia and lack of anti HBs formation, which was also apparent in our patient, seriously aggravates the risk for the development of primary hepatocellular carcinoma (28). Most cases of primary hepatocellular carcinoma in developed countries arise in a liver already affected with cirrhosis. Hepatitis B virus antigens are rarely found in the carcinomas, but can be seen in non-carcinomatous parts of the liver, as in our case. The presence of hepatitis B virus DNA in hepatocellular carcinomas developing in HBsAg positive and even in HBsAg negative subjects supports the association of the virus with the tumor (28).

Our observations support the hypothesis of a synergism between a persistent infection with specific HPV types, cellular immune deficiency and sunlight in the pathogenesis of squamous cell carcinoma of the skin in epidermodysplasia verruciformis and stress the importance of immune surveillance in the protection against virus-associated tumor growth.

#### ACKNOWLEDGEMENTS

The virologic study was supported by grant P. R. C. Convention N° 134 030 from the Institut National de la Santé et de la Recherche Médicale (France) and by grant AI N° 033 694/00 from the Centre National de la Recherche Scientifique (France).

#### REFERENCES

1. Lutzner MA. Epidermodysplasia verruciformis: an autosomal recessive disease characterized by viral warts and skin cancer. *Bull Cancer* 1978; 65: 169-182.
2. Jablonska S, Orth G, Lutzner MA. Immunopathology of papillomavirus-induced tumors in different tissues. *Springer Semin Immunopathol* 1982; 5: 33-62.
3. Kienzler JL, Laurent R, Coppey J, Favre M, Orth G, Coupez L, Agache P. Epidermodysplasie verruciforme. Données ultrastructurales, virologiques et photobiologiques: à propos d'une observation. *Ann Dermatol Venereol* 1979; 106: 549-563.
4. Claudy AL, Touraine JL, Mitanne D. Epidermodysplasia verruciformis induced by a new human papillomavirus (HPV-8). *Arch Dermatol Res* 1982; 274: 213-219.
5. Ruiter M, van Mullem PJ. Demonstration by electron microscopy of an intranuclear virus in epidermodysplasia verruciformis. *J Invest Dermatol* 1966; 47: 247-252.
6. Kremsdorf D, Jablonska S, Favre M, Orth G. Biochemical characterization of two types of human papillomaviruses associated with epidermodysplasia verruciformis. *J Virol* 1982; 43: 436-447.
7. Kremsdorf D, Jablonska S, Favre M, Orth G. Human papillomaviruses associated with epidermodysplasia verruciformis. II. Molecular cloning and biochemical characterization of human papillomavirus 3a, 8, 10 and 12 genomes. *J Virol* 1983; 48: 340-351.

8. Kremsdorf D, Favre M, Jablonska S, Obalek S, Rueda LA, Lutzner MA, Blanchet-Bardon C, van Voorst Vader PC, Orth G. Molecular cloning and characterization of the genomes of nine newly recognized human papillomavirus types associated with epidermodysplasia verruciformis. *J Virol* 1984; 52: 1013-1018.
9. Gassenmaier A, Lammel M, Pfister H. Molecular cloning and characterization of the DNAs of human papillomaviruses 19, 20 and 25 from a patient with epidermodysplasia verruciformis. *J Virol* 1984; 52: 1019-1023.
10. Lancaster WD, Olson C. Animal papillomaviruses. *Microbiol Rev* 1982; 46: 191-207.
11. Lutzner MA. The human papillomaviruses: a review. *Arch Dermatol* 1983; 119: 631-635.
12. Lutzner MA, Orth G, Dutronquay V, Ducasse MF, Kreis H, Crosnier J. Detection of human papillomavirus type 5 DNA in skin cancers of an immunosuppressed renal allograft recipient. *Lancet* 1983; ii: 422-424.
13. Dürst M, Gissmann L, Ikenberg H, zur Hausen H. A papillomavirus DNA from a cervical carcinoma and its prevalence in cancer biopsy samples from different geographic regions. *Proc Natl Acad Sci USA* 1983; 80: 3812-3815.
14. Crum CP, Ikenberg H, Richart RM, Gissmann L. Human papillomavirus type 16 and early cervical neoplasia. *N Engl J Med* 1984; 310: 880-883.
15. Boshart M, Gissmann L, Ikenberg H, Kleinheinz A, Scheurlen W, zur Hausen H. A new type of papillomavirus DNA, its presence in genital cancer biopsies and in cell lines derived from cervical cancer. *EMBO J* 1984; 3: 1151-1157.
16. Orth G, Favre M, Breitburd F, Croissant O, Jablonska S, Obalek S, Jarzabek-Chorzelska M, Rzesza G. Epidermodysplasia verruciformis: a model for the role of papillomaviruses in human cancer. *Cold Spring Harbor Conf Cell Proliferation* 1980; 7: 259-282.
17. Ostrow RS, Bender M, Niimura M, Seki T, Kawashima M, Pass F, Faras AJ. Human papillomavirus DNA in cutaneous primary and metastasized squamous cell carcinomas from patients with epidermodysplasia verruciformis. *Proc Natl Acad Sci USA* 1982; 79: 1634-1638.
18. Pfister H, Gassenmaier A, Nürnberger F, Stüttgen G. Human papilloma virus 5-DNA in carcinoma of an epidermodysplasia verruciformis patient infected with various human papillomavirus types. *Cancer Res* 1983; 43: 1436-1441.
19. Rüter M, van Mullem PJ. Further histological investigations on malignant degeneration of cutaneous lesions in epidermodysplasia verruciformis. *Acta Derm Venereol (Stockh)* 1970; 50: 205-211.
20. Rüter M, van Mullem PJ. Behaviour of virus in malignant degeneration of skin lesions in epidermodysplasia verruciformis. *J Invest Dermatol* 1970; 54: 324-331.
21. Kallenberg CGM, Toesma R, The TH. The immune response to primary immunogens in man. In: Reeves WG, ed. *Recent developments in clinical immunology*. Amsterdam: Elsevier Biomedical Press, 1984; 1-26.
22. Orth G, Jablonska S, Jarzabek-Chorzelska M, Obalek S, Rzesza G, Favre M, Croissant O. Characteristics of the lesions and risk of malignant conversion associated with the type of human papillomavirus involved in epidermodysplasia verruciformis. *Cancer Res* 1979; 39: 1074-1082.
23. Lutzner MA, Blanchet-Bardon C, Orth G. Clinical observations, virologic studies and treatment trials in patients with epidermodysplasia verruciformis, a disease induced by specific human papillomaviruses. *J Invest Dermatol* 1984; 82: 18s-25s.
24. Green M, Brackmann KH, Sander PR, Loewenstein PM, Freel JH, Eisinger M, Switlyk SA. Isolation of a human papillomavirus from a patient with epidermodysplasia verruciformis: presence of related viral DNA genomes in human urogenital tumors. *Proc Natl Acad Sci USA* 1982; 79: 4437-4441.
25. Jablonska S, Orth G, Jarzabek-Chorzelska M, Gliński W, Obalek S, Rzesza G, Croissant O, Favre M. Twenty-one years of follow-up studies of familial epidermodysplasia verruciformis. *Dermatologica* 1979; 158: 309-327.
26. Klein G, Klein E. Immune surveillance against virus-induced tumors and non-rejectability of spontaneous tumors: contrasting consequences of host versus tumor evolution. *Proc Natl Acad Sci USA* 1977; 74: 2121-2125.
27. Herberman RB. Possible role of natural killer cells and other effector cells in immune surveillance against cancer. *J Invest Dermatol* 1984; 83: 137s-140s.
28. Arthur MJP, Hall AJ, Wright R. Hepatitis B, hepatocellular carcinoma, and strategies for prevention. *Lancet* 1984; i: 607-610.