

Collagen Components in the Duodenal and Rectal Mucosa in Progressive Systemic Sclerosis and Other Diseases

LENE HENDEL,¹ THORKIL AMMITZBØLL,¹ KAREN DIRKSEN²,
and MICHAEL PETRI³

Departments of ¹Dermatology (with connective tissue research laboratories) and ²Radiology, Rigshospital, and ³Department of Histopathology, Sundby Hospital, Copenhagen

Hendel L, Ammitzbøll T, Dirksen K, Petri M. Collagen components in the duodenal and rectal mucosa in progressive systemic sclerosis and other diseases. *Acta Derm Venereol (Stockh)* 1986; 66: 220-224.

Small intestinal mucosa from 14 patients suffering from progressive systemic sclerosis and 22 patients with various other diseases was analysed for collagen components. There was no significant difference in the concentration of hydroxyproline, hydroxylysine and proline between the two groups. Rectal mucosa from 11 progressive systemic sclerosis patients, 5 patients with ulcerative colitis and 7 patients with various other diseases was analysed for collagen components. No significant difference was demonstrated in the concentration of hydroxyproline, hydroxylysine and proline between progressive systemic sclerosis patients and patients with various other diseases, but in patients with ulcerative colitis the concentration of hydroxyproline, hydroxylysine and proline were found to be significantly lower than in the two other groups. *Key words: Gastrointestinal mucosal biopsies; Hydroxyproline, hydroxylysine, proline; Scleroderma; Ulcerative colitis.* (Received January 13, 1986.)

Lene Hendel, Department of Dermatology, Rigshospital, Blegdamsvej 9, DK-2100 Copenhagen Ø, Denmark.

Progressive systemic sclerosis (PSS, generalized scleroderma) is a systemic disease characterized by excessive deposits of collagen in skin and various internal organs. The gastrointestinal tract is frequently involved. The esophagus is involved in about 70% of all PSS cases, the small and large intestine in about 40% and 100%, respectively (1). In a previous study we demonstrated the esophageal mucosa from PSS patients with esophageal involvement to contain a higher concentration of collagen than esophageal mucosa from PSS patients without involvement (2). In the present study, we determined the concentrations of amino acids characteristic of collagen in the duodenal and rectal mucosa of PSS patients and of patients with various other diseases. The aim of the study was to investigate whether changes in collagen concentration in the surface layers of the gastrointestinal tract is a characteristic feature in PSS (2, 3).

MATERIAL

The material consisted of 14 patients with an established diagnosis (4) of PSS and 34 other patients with various skin and/or gastrointestinal disorders admitted to the departments of dermatology and internal medicine. All individuals consented after proper information to participate in the study. The 14 PSS patients were 12 women and 2 men, age range 16-75 years, duration of PSS 1-28 years. The 34 other patients were 15 women and 19 men, age range 20-74 years. Skin conditions were psoriasis, dermatitis herpetiformis and lichen planus. Gastrointestinal disorders included a variety of diagnosis. Small intestinal biopsies were provided from 14 PSS patients and 22 patients with one of the following diagnoses: gluten sensitive enteropathy, lactose malabsorption, Crohn's disease, irritable bowel

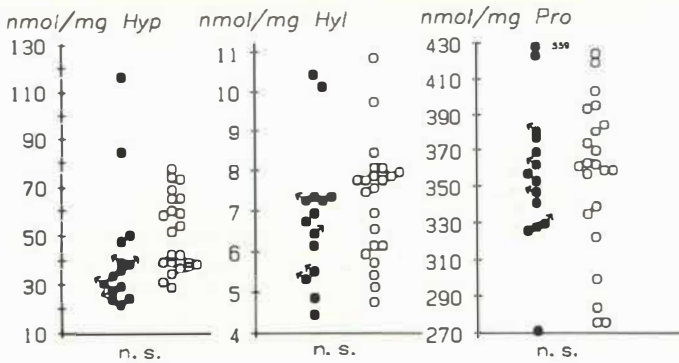


Fig. 1. Concentrations of hydroxyproline (Hyp), hydroxylysine (Hyl) and proline (Pro) in duodenal mucosa of PSS patients (●) and other patients (○). PSS patients with duodenal involvement are marked with an arrow.

syndrome and non-specific chronic diarrhoea. Rectal mucosa was provided from 11 PSS patients, 5 patients with ulcerative colitis and 7 patients with one of the following diagnoses: sigmoid cancer, hypersedimentation and non-specific chronic diarrhoea. All biopsies were taken from a mucosal surface without evident macroscopic inflammation.

METHODS

All 14 PSS patients had routine X-ray examination of the small intestine and large bowel and xylose absorption test (five hour urine excretion) was carried out as well.

Small intestinal biopsies were taken at the duodeno-jejunal junction using a hydraulic suction biopsy equipment (Quinton). The position of the biopsy capsule was controlled by fluoroscopy. Several biopsies were obtained in each patient and the villus pattern of each biopsy was surveyed in a dissecting microscope.

Rectal biopsies were taken through the rectoscope from normal appearing mucosa 12 cm above anus. In the patients with ulcerative colitis a slight granulation of the mucosa was accepted. Biopsy material for histopathologic evaluation was fixed in Lillies solution, embedded in paraffine and sectioned at 4 μ m. Biopsy material for collagen analysis was fixed in acetone.

Collagen analysis. The samples were defatted and dried in acetone, acetone/ether, and ether. The defatted, dried tissue was hydrolysed in 6 N HCl at 118°C for 18 hours and evaporated to dryness at 60°C at 50 mbar. The residue was dissolved in a 0.046 M citrate/0.415 M phosphate buffer, pH 7.0 and analysed for hydroxyproline (Hyp), hydroxylysine (Hyl), and proline (Pro) by an Auto-Analyzer®-equipment (5, 6). The results were expressed as nmol amino acid per mg defatted, dried tissue.

Statistic evaluation was performed by the Wilcoxon test for unpaired data and by the *t*-test for paired differences. Biological significance was recognized at $p < 0.05$.

RESULTS

X-ray

Four of 14 PSS patients showed changes consistent with duodenal sclerosis, one had changes of the large bowel (Table I).

Xylose absorption

One of 14 PSS patients showed impaired absorption (Table I).

Table I. Fourteen PSS patients studied as indicated below

	Small intestine		Large intestine	
	Normal	Abnormal	Normal	Abnormal
X-ray	11	3	10	1
Histopathology	14	0	11	0
Xylose absorption	13	1		

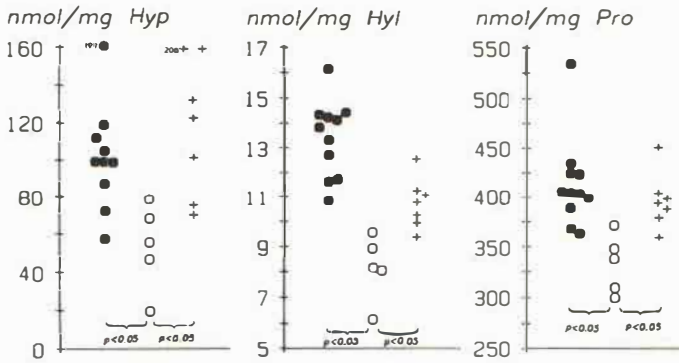


Fig. 2. Concentrations of hydroxyproline (Hyp), hydroxylysine (Hyl) and proline (Pro) in rectal mucosa from PSS patients (●), patients with ulcerative colitis (○), and other patients (+).

Histopathology

Specific changes were not found neither in the small intestinal biopsies nor in the rectal biopsies in the PSS patients (Table I). Specific changes were found in none of the small intestinal specimens from other patients. Inflammatory changes consistent with a diagnosis of ulcerative colitis were found in one rectal biopsy. All other rectal biopsies were described as normal. All biopsies reached the level of the muscularis mucosa.

Biochemistry

The concentrations of the collagen components Hyp, Hyl and Pro in duodenal mucosa of PSS patients as compared to other patients are illustrated in Fig. 1. No significant differences were found. The concentrations of Hyp, Hyl and Pro in duodenal mucosa from the PSS patients with PSS involvement of the small intestine did not differ from the rest of the group, but were very close to the mean (Fig. 1). The concentrations of the collagen components Hyp, Hyl and Pro in PSS patients as compared to patients with ulcerative colitis and patients with other diseases are illustrated in Fig. 2.

A significant difference between PSS patients and other patients could not be demonstrated except for patients with ulcerative colitis, whose rectal mucosa showed concentrations of Hyp, Hyl and Pro significantly lower than the other two groups.

Comparison between Hyp, Hyl and Pro concentrations in duodenal and rectal mucosa of PSS patients is shown in Fig. 3. For the collagen specific amino acids, Hyp and Hyl, the difference was highly significant. In 8 patients small intestinal biopsies from 2 areas in each patient were evaluated. The mean variation in the values of Hyp, Hyl and Pro between the areas was 6.0, 0.15 and 14 nmol/mg, respectively. These values do not exceed the standard deviations of the analytical methods as determined by analysing pure collagen standards.

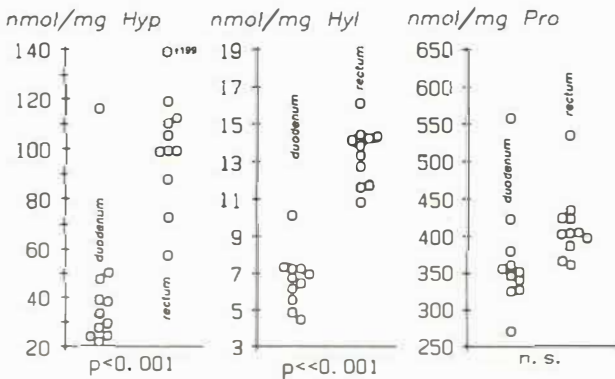


Fig. 3. Concentrations of hydroxyproline (Hyp), hydroxylysine (Hyl) and proline (Pro) in duodenal and rectal mucosa of PSS patients.

This indicates that the inhomogeneity of the tissue contributes very little to the overall analytic variation.

DISCUSSION

PSS involves the gastrointestinal tract in 70% of all cases. The esophagus, small bowel, colon and stomach are involved in decreasing order of frequency. The conception of involvement is based on radiographic and myoelectric changes fairly specific for PSS. These findings are due to small muscle atrophy of the outer muscle coat with fibrotic repair. Histopathology needs full wall (surgical or autopsy) tissue specimens to suggest a diagnosis of PSS. Mucosal biopsies have never been reported to contribute to the diagnosis, although fibrosis of the lamina propria has been described in a case story (7).

Previously, we have shown that mucosal biopsies from PSS involved esophagi contained larger amounts of collagen components than did mucosal biopsies from non-involved esophagi and we suggested that this might be of importance in the pathogenesis of stricture formation. We found it of interest to investigate the small intestinal mucosa in order to find out whether fibrosis in the surface layers might influence absorptive capacity and thus be a factor in the pathogenesis of malabsorption. Malabsorption in PSS is partly due to bacterial overgrowth but is not fully explained (1, 8). We were not able to demonstrate any difference in the concentration of Hyp, Hyl and Pro as compared to other patients. Four PSS patients (29%) had PSS manifestations of the duodenum, matching the percentage found in other materials. Hyp, Hyl and Pro concentrations in the duodenal mucosa from these patients did not tend to exceed the corresponding values in the rest of the PSS patient group, but were, on the contrary, placed in the lower part of the distribution (Fig. 1). This is in accordance with an ultrastructural study of small intestinal mucosa from PSS patients, where no collagen deposits could be demonstrated in the mucosa (9).

We did not find the rectal mucosa of PSS patients to contain a larger concentration of Hyp, Hyl and Pro as compared to other patients either. Incidentally, we found the rectal mucosa from patients with ulcerative colitis to contain significantly lower concentrations of Hyp, Hyl and Pro as compared to PSS patients and other patients. This might be due to deterioration of membranes although histopathology was found normal. Hyp, Hyl and Pro concentrations in duplicate biopsies from the same patient were almost identical, indicating that the interindividual variance is real and not due to methodology.

Rectal mucosa contains significantly higher amounts of collagen specific amino acids than does duodenal mucosa. The concentration of Pro is not significantly different in rectal and duodenal mucosa consistent with the fact that Pro occurs in other proteins than collagen.

Concentrations of Hyp, Hyl and Pro were not significantly higher in duodenal or rectal mucosa of PSS patients than in a control group of other patients. PSS patients with duodenal manifestations of PSS did not differ from the rest of the PSS patient group. This is in contrast to the conditions previously demonstrated in the esophagus. An incidental finding is that in patients with ulcerative colitis concentrations of Hyp, Hyl and Pro in rectal mucosa are significantly lower than in PSS patients and other patients.

ACKNOWLEDGEMENTS

We want to thank Mr Ole Christensen and Mrs Eva Hoffmann for expert technical and Mrs Inger Johansson for very competent secretarial assistance. We also want to thank the gastroenterological laboratories of Rigshospital, Gentofte Hospital, and Glostrup Hospital, for their help providing biopsy material.

REFERENCES

1. Cohen S, Laufer I, Snape WJ, Shian Y, Levine GM, Jimenez S. The gastrointestinal manifestations of scleroderma: Pathogenesis and management. *Gastroenterology* 1980; 79: 155-166.
2. Hendel L, Ammitzbøll T, Dirksen K, Petri M. Collagen in the esophageal mucosa of patients with progressive systemic sclerosis. *Acta Derm Venereol (Stockh)* 1984; 64: 480-484.
3. Greenberger NJ, Dobbins WO, Ruppert RD, Jessoph JE. Intestinal atony in progressive systemic sclerosis (scleroderma). *Am J Med* 1968; 45: 301-308.
4. Masi AT et al. Subcommittee for scleroderma criteria of the American Rheumatism Association diagnostic and therapeutic criteria subcommittee. *Arthritis Rheum* 1980; 23: 581-590.
5. Blumenkrantz N, Asboe-Hansen G. Methods for analysis of connective-tissue macromolecules by determination of certain constituents. In: Glick D, ed. *Methods of biochemical analysis*. New York: John Wiley & Sons, 1977; 24: 39-91.
6. Blumenkrantz N. Automated triple assay for proline, hydroxyproline and hydroxylysine on one single sample. Manual and automated assays for proline and hydroxylysine on individual samples. *Clin Biochem* 1980; 13: 177-183.
7. Rosson R, Yesner R. Peroral duodenal biopsy in progressive systemic sclerosis. *N Engl J Med* 1965; 272: 391-394.
8. Cøbden I, Axon AT, Ghoneim AT, McGoldrick J, Rowell NR. Small intestinal bacterial growth in systemic sclerosis. *Clin Exp Dermatol* 1980; 5: 37-42.
9. Hendel L, Kobayasi T, Petri M. Ultrastructure of the small intestinal mucosa in progressive systemic sclerosis. Submitted for publication.