

Tubuloreticular Structures in Kaposi's Sarcoma: A Comparison of the Classical and AIDS-Associated Forms

K. KONRAD,¹ PETER SCHENK² and
KLEMENS RAPPERSBERGER¹

¹Department of Dermatology I and ²Department of Otolaryngology II,
University of Vienna, Vienna, Austria

Konrad K, Schenk P, Rappersberger K. Tubuloreticular structures in Kaposi's sarcoma: a comparison of the classical and AIDS-associated forms. *Acta Derm Venereol (Stockh)* 1986; 66: 207-212.

The ultrastructural morphology of both the classical and the AIDS-associated forms of Kaposi's sarcoma was examined electron-microscopically. Tubuloreticular structures were found only in the AIDS-associated form of Kaposi's sarcoma, and not in the classical variant of the tumor. Moreover, the tubuloreticular structures, 20-30 nm in diameter, were present in very high numbers and in two different forms: the loosely intertwined tubuli, which were clearly predominant; and those forming a more compact pattern. These findings suggest that the presence of tubuloreticular structures may well be an ultrastructural marker for diagnosing AIDS and AIDS-associated disorders. *Key words: Acquired immune deficiency syndrome.* (Received January 30, 1986.)

K. Konrad, Department of Dermatology I, University of Vienna, Alser Strasse 4, A-1090 Vienna, Austria.

The classical form of Kaposi's sarcoma (KS), a rare malignant tumor with an unusual clinical course and exhibiting interesting epidemiological features, was first described by Kaposi in 1872 (1) and is still not completely understood. The new epidemic form of KS, found in patients with the acquired immune deficiency syndrome (AIDS), has stimulated new interest in this rare vascular neoplasm. It is, unlike the classical form, biologically more aggressive and affects young adults. Further, the disease tends to be more generalized with visceral and lymph node involvement.

Tubuloreticular structures (TRS) are irregularly branching and anastomosing tubules within the endoplasmic reticulum, and have been found in a variety of autoimmune, viral and neoplastic diseases (2, 3).

As we have consistently found TRS in the AIDS-associated form of KS, it seemed essential to re-examine the classical form of KS with regard to the presence of TRS. Thus, in the present paper, we report on the occurrence of TRS in KS cells in three patients with AIDS as compared with the classical form of KS.

MATERIAL AND METHODS

Skin biopsies were taken from classical KS lesions of two patients, and from early plaque lesions and tumor lesions of KS of three patients with AIDS. In the AIDS patients the diagnosis was established by HTLV-III serology, the demonstration of an inverted T-helper/T-suppressor cell ratio, the presence of opportunistic infections and of KS. The excised tissues were immediately processed for light and electron microscopy according to standard methods.

RESULTS

Light microscopically, the tumor lesions in both the classical and the AIDS-associated form of KS revealed typical spindle-shaped KS cells and numerous extravasated erythro-

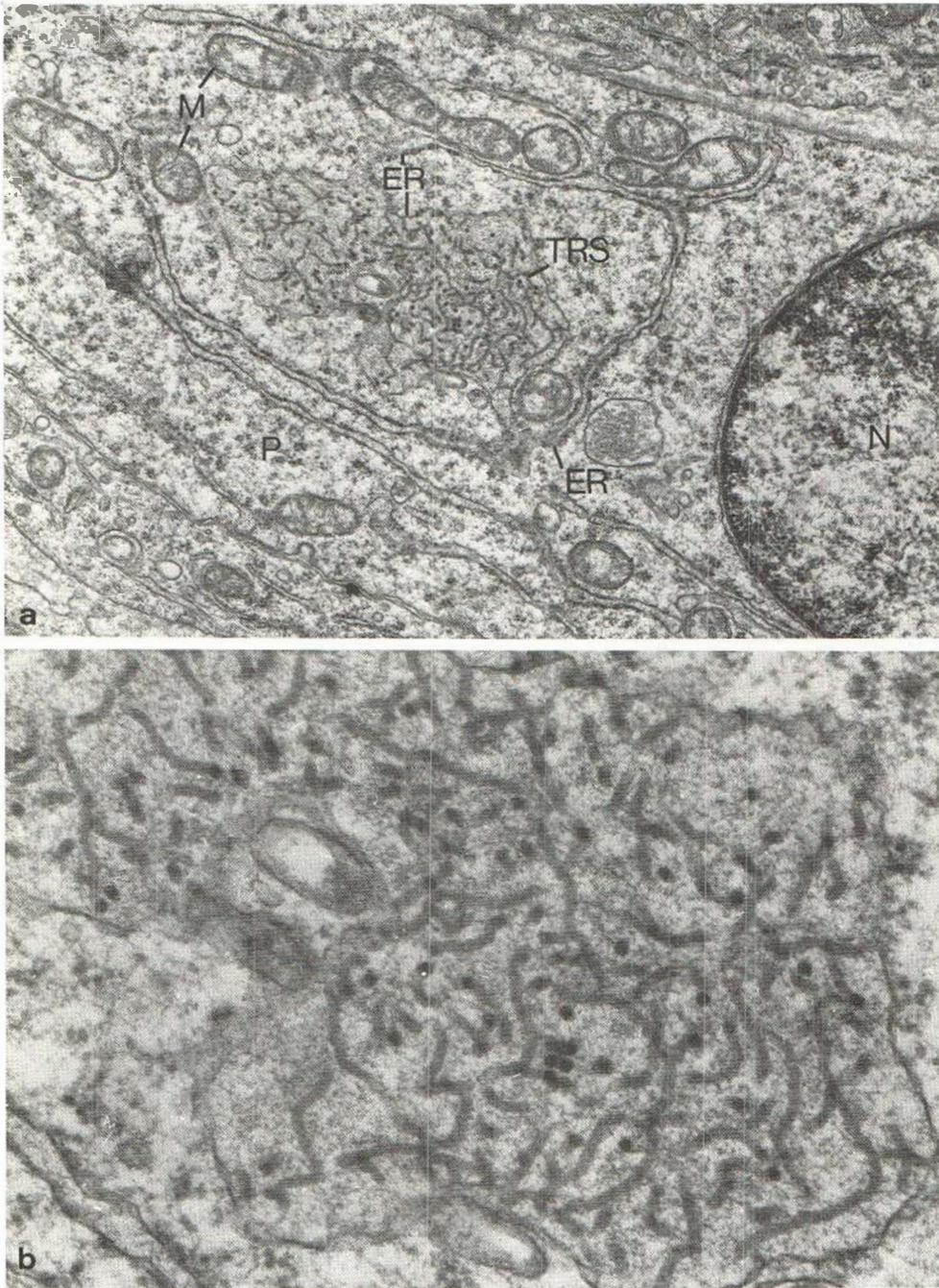


Fig. 1 a, b. Tumor lesion of Kaposi's sarcoma in AIDS. (a) Neoplastic spindle cell containing the loosely intertwined variety of tubuloreticular structures (TRS). *N*, nucleus; *M*, mitochondria; *ER*, endoplasmic reticulum; *P*, polysomes. ($\times 23\,850$.) (b) High power magnification of the tubuloreticular structures shown in Fig. 1 a. Note the tubular lumen, and apparent contiguity of the tubuloreticular structures and the granular endoplasmic reticulum. ($\times 75\,600$.)

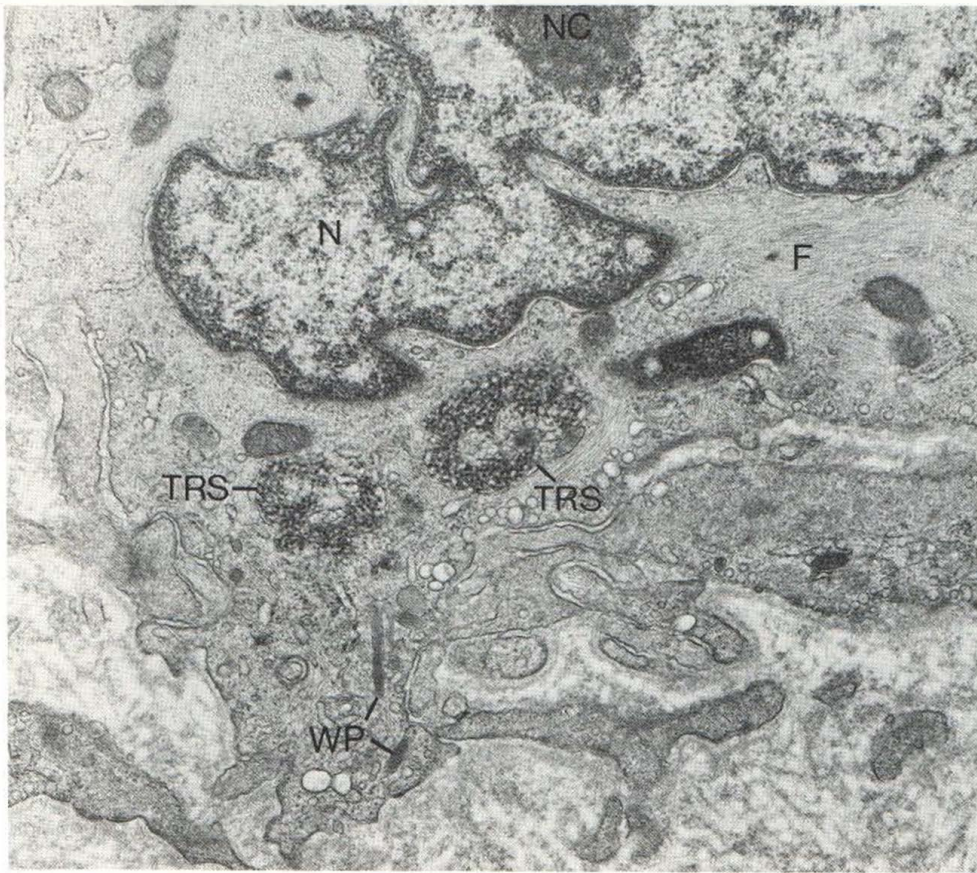


Fig. 2. Early plaque stage of Kaposi's sarcoma in AIDS. Vascular endothelial cell with the compact pattern of tubuloreticular structures (TRS) within endoplasmic reticulum. *N*, nucleus; *NC*, nucleolus; *F*, cytoplasmic filaments; *WP*, Weibel-Palade bodies. ($\times 23\,850$.)

cytes. Further, there were irregular vascular slits and channels surrounded by infiltrates consisting of lymphocytes and plasma cells.

TRS were found only in AIDS-associated KS and not in the classical form of the tumor. In AIDS-associated KS the TRS were present in almost every vascular endothelial cell and neoplastic spindle cell, but only rarely in lymphocytes and macrophages.

Ultrastructurally, the TRS were numerous and were seen in two distinct forms. One consisted of loosely intertwining branching and anastomosing tubuli (Figs. 1*a, b*). The other was a more compact reticular network of tubular profiles of the same individual size as the loosely intertwined variety (Figs. 2, 3). The loosely intertwined tubuli were far more numerous than those with a more compact form. In very rare instances, both TRS patterns could be observed within one and the same cell (Fig. 4). There were no differences either in the number or morphology of TRS in early plaque lesions or in tumor lesions of AIDS-associated KS.

The individual tubuli measured up to 20–30 nm in diameter, and the TRS as a whole extended over an area of 1.5–2.0 μm . They occurred most frequently within the endoplasmic reticulum (Fig. 1*b*), or very occasionally, in the perinuclear cisternae of the cells (Fig. 3).

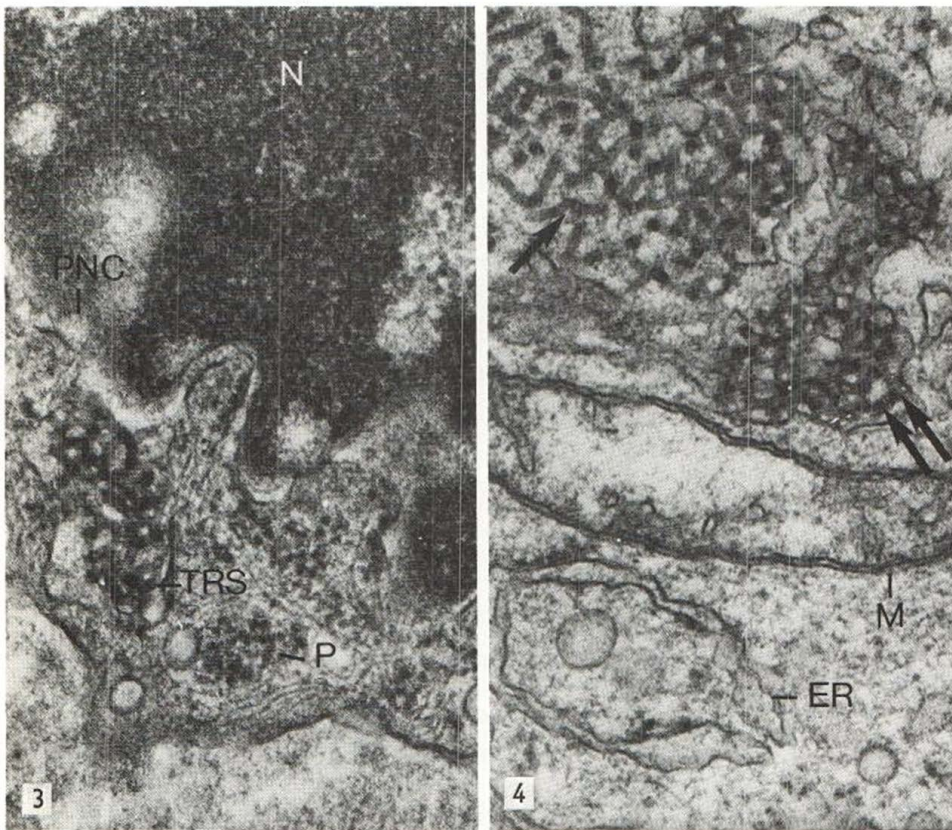


Fig. 3. Tumor stage of Kaposi's sarcoma in AIDS. Compact tubuloreticular structures (TRS) in perinuclear cisterna (PNC). *N*, nucleus; *P*, polysomes. ($\times 75\,600$.)

Fig. 4. Tumor stage of Kaposi's sarcoma in AIDS. Both loose (arrow) and compact (double arrow) tubuloreticular structures within endoplasmic reticulum of one and the same Kaposi's sarcoma cell. *M*, mitochondrion; *ER*, endoplasmic reticulum. ($\times 75\,600$.)

DISCUSSION

This study confirms not only the presence of TRS (4) but also that they occur in very high numbers in KS cells obtained from both early plaque lesions as well as tumor lesions in patients with AIDS. It also shows that in patients with the classical form of KS TRS do not occur in lesional skin. This statement is based on the fact that a very large number of electron micrographs were closely scrutinized and corresponds to earlier reports on the ultrastructure of classical KS (5, 6, 7) which fail to mention the presence of TRS within KS tumor cells.

TRS are not specific to AIDS, although they have been described in different tissue biopsies and peripheral blood samples from patients with AIDS and AIDS-related diseases (8, 9, 10, 11); they may be found in various autoimmune (12), viral (13, 14) and neoplastic (15, 16) disorders. However, TRS are ultrastructurally distinct from any known virus particles. As demonstrated by digestion experiments, TRS are resistant to digestion by trypsin and by bovine pancreatic ribonuclease (RNase) and deoxyribonuclease (DNase) and are thus cytochemically believed to be complexes of phospholipid membranes and glycoprotein components (17, 18).

The formation of TRS can be induced in lymphoid cells by halogenated pyrimidines, which are known to activate latent virus infections (19, 20, 21). Also leucocyte (α)- and fibroblast (β)-interferons, but not immune (γ)-interferon, can stimulate the development of TRS (22). There seems to be no direct correspondence between the presence of TRS and serum interferon levels in patients with AIDS (23). Further investigation on the role of interferon in TRS formation is thus essential.

The chemical nature and the pathophysiological function of TRS in AIDS is not yet completely understood. It cannot be said with certainty if TRS are merely host cell products, defective viruses or a host cell reaction pattern in response to different stimuli.

There can be little doubt that the presence of innumerable TRS together with the serological demonstration of HTLV-III antibodies and other immunological parameters is of diagnostic relevance. This is especially so in diagnosing the early stages of AIDS and AIDS-related disorders.

ACKNOWLEDGEMENTS

The technical assistance of Ms S. Csegezi, Ms E. Wieser, and Mr H. Gaudek is gratefully acknowledged.

REFERENCES

1. Kaposi M. Idiopathisches multiples Pigmentsarkom der Haut. Arch Dermatol Syphil 1872; 4: 265-273.
2. Ghadially FN. Ultrastructural pathology of the cell and matrix. 2nd ed. London: Butterworths, 1982.
3. Grimley PM, Schaff Z. Significance of tubuloreticular inclusions in the pathobiology of human diseases. In: Joachim HL. Pathobiology annual. New York: Appleton-Century Crofts, 1976: 221-257.
4. Gyorkey F, Sinkovics JG, Gyorkey P. Tubuloreticular structures in Kaposi's sarcoma. Lancet 1982; ii: 984-985.
5. Hashimoto K, Lever WF. Kaposi's sarcoma. Histochemical and electron microscopic studies. J Invest Dermatol 1964; 43: 539-549.
6. Mottaz JH, Zelickson AS. Electron microscope observations of Kaposi's sarcoma. Acta Derm Venereol (Stockh) 1966; 46: 195-200.
7. Niemi M, Mustakallio KK. The fine structure of the spindle cell in Kaposi's sarcoma. Acta Pathol Microbiol Scand 1965; 63: 567-575.
8. Anderson MG, Dixey J, Key P, Ellis DS, Tovey G, McCaul TF, Murray-Lyon IM, Gazzard B, Lawrence A, Evans B, Byrom N, Zuckerman AJ. Persistent lymphadenopathy in homosexual men: a clinical and ultrastructural study. Lancet 1984; i: 880-882.
9. Dobbins WO, Weinstein WM. Electron microscopy of the intestine and rectum in acquired immunodeficiency syndrome. Gastroenterol 1985; 85: 738-749.
10. Kostianovsky M, Kang YH, Grimley PM. Disseminated tubuloreticular inclusions in acquired immunodeficiency syndrome (AIDS). Ultrastruct Pathol 1983; 4: 331-336.
11. Onerheim RM, Wang NS, Gilmore N, Jothy S. Ultrastructural markers of lymph nodes in patients with acquired immune deficiency syndrome and in homosexual males with unexplained persistent lymphadenopathy. Am J Clin Pathol 1984; 82: 280-288.
12. Klippel JH, Grimley PM, Decker JL, Michelitch HJ. Lymphocyte tubuloreticular structures in lupus erythematosus. Correlation with disease activity. Ann Intern Med 1974; 81: 355-357.
13. Baringer JR. Tubular aggregates in endoplasmic reticulum in herpes simplex encephalitis. N Engl J Med 1971; 285: 943-945.
14. Tandler B, Erlandson RA, Southam CM. Unusual membrane formations in HEP-2 cells infected with Ilheus virus. Lab Invest 1973; 28: 217-223.
15. Arnold W, Huth F. Viren virusähnliche und auf Viren hinweisende Strukturen beim Karzinom des Nasopharynx. Arch Otorhinolaryngol 1979; 222: 295-317.
16. Shamoto M, Murakami S, Zenke T. Adult T-cell leukemia in Japan: an ultrastructural study. Cancer 1981; 47: 1804-1811.
17. Schaff Z, Heine U, Dalton AJ. Ultramorphological and ultracytochemical studies on tubuloreticular structures in lymphoid cells. Cancer Res 1972; 32: 2696-2706.

18. Schaff Z, Barry DW, Grimley PM. Cytochemistry of tubuloreticular structures in lymphocytes from patients with systemic lupus erythematosus and in cultured human lymphoid cells. Comparison to a paramyxovirus. *Lab Invest* 1973; 29: 577-586.
19. Grimley PM, Barry DW, Schaff Z. Induction of tubular structures in the endoplasmic reticulum of human lymphoid cells by treatment with 5-bromo-2'-deoxyuridine. *J Natl Cancer Inst* 1973; 51: 1751-1760.
20. Hulanicka B, Barry DW, Grimley PM. Induction of tubuloreticular inclusions in human lymphoma cells (Raji line) related to S-phase treatment with halogenated pyrimidines. *Cancer Res* 1977; 2105-2113.
21. Splinter TAW, Helder AW, Lucas CJ, Feltkamp-Vroom TM. Tubuloreticular structures in human lymphoid cell lines. A cell biological study. *Br J Exp Pathol* 1975; 56: 124-132.
22. Rich SA, Owens TR, Bartholomew LE, Gutterman JU. Immune interferon does not stimulate formation of alpha and beta interferon induced human lupus-type inclusions. *Lancet* 1983; i: 127-128.
23. Grimley PM, Kang YH, Frederick W, Rook AH, Kostianovsky M, Sonnabend JA, Macher AM, Quinnan GV, Friedman RM, Masur H. Interferon-related leukocyte inclusions in acquired immune deficiency syndrome: localization in T cells. *Am J Clin Pathol* 1984; 81: 147-155.