

Malignancy in Seborrheic Keratoses

O. J. CLEMMENSEN and K.-E. SJØLIN

Department of Pathology, Sundby Hospital, Copenhagen, Denmark

Clemmensen O J, Sjølin K-E. Malignancy in seborrheic keratoses. *Acta Derm Venereol (Stockh)* 1986; 66: 158-161.

Among 5 500 seborrheic keratoses 3 were found with marked squamous cell atypia. Clinically they were seborrheic keratoses. Even though they were incompletely removed, no recurrences were observed. In contrast to some reports in the literature we regard these lesions as biologically benign, and suggest that they be treated accordingly. *Key words: Seborrheic keratosis; Squamous cell carcinoma.* (Received June 12, 1985.)

Ole J. Clemmensen, Department of Pathology, Sundby Hospital, Italiensvej 1, DK-2300 Copenhagen S, Denmark.

In 1926 Freudenthal pointed out the histologic differences between actinic keratoses ("senile Keratome") and seborrheic keratoses ("senilen Warzen"), which had till then been regarded as identical (1). While the former type of lesion was still accepted as potentially malignant an important consequence of this distinction was the classification of seborrheic keratoses as wholly benign lesions without any potential for malignancy. This view is still widely accepted, but reports have appeared which state that seborrheic keratoses occasionally may evolve into squamous cell carcinoma in situ (2-6) or into metastasizing squamous cell carcinoma (7). We question the concept that squamous cell carcinoma in situ do more often arise in seborrheic keratoses than in any other normal epithelial structure of the epidermis.

MATERIAL AND METHODS

Among seborrheic keratoses drawn from our files, lesions with squamous cell carcinoma in situ like features were collected. Clinical information of the patients was achieved from the records of the referring dermatologists and comprised the morphology and location of the lesion, the procedure of removal, possible additional excision and follow-up of the patients. Formalin fixed tissue was embedded in paraffin and sections were cut and stained with hematoxylin and eosin.

RESULTS

Among 5 500 seborrheic keratoses collected between 1959 and 1984, 3 were found with features which satisfied our criteria of atypia: irregular arrangement of the cells which show loss of polarity, marked variation in nuclear size and shape with large, often bizarre, irregular, hyperchromatic nuclei. Many mitoses, often abnormal, tripolar and ring-shaped, dyskeratotic cells scattered singly or in small aggregates. The overall clinical appearance of the lesions was that of seborrheic keratoses; a slightly papillated surface, an even colour of tan or somewhat darker brown, and a "stuck on" appearance. In one case a differential diagnosis of a basal cell carcinoma was proposed. Two of the keratoses were situated on sun exposed skin.

The clinical data are presented in Table I.

All lesions showed the histologic architecture of a typical seborrheic keratosis with a papillated surface covered with a hyperkeratotic stratum corneum composed of delicate horn, a hyperplastic epidermis with basaloid cells, and scattered "pseudohornocysts" (Fig. 1a). In juxtaposed areas, however, the stratum corneum was parakeratotic and the

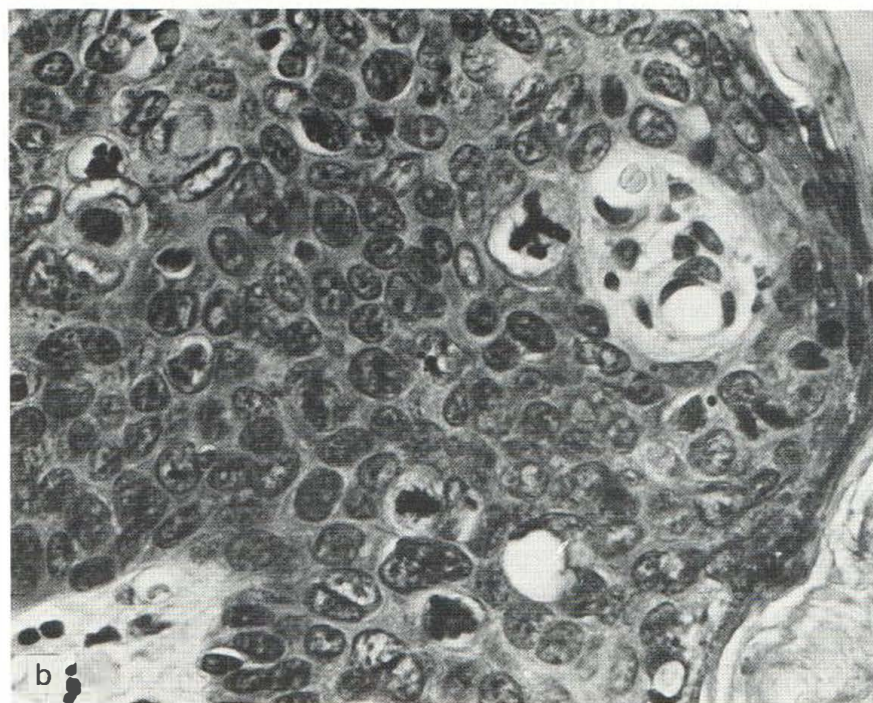
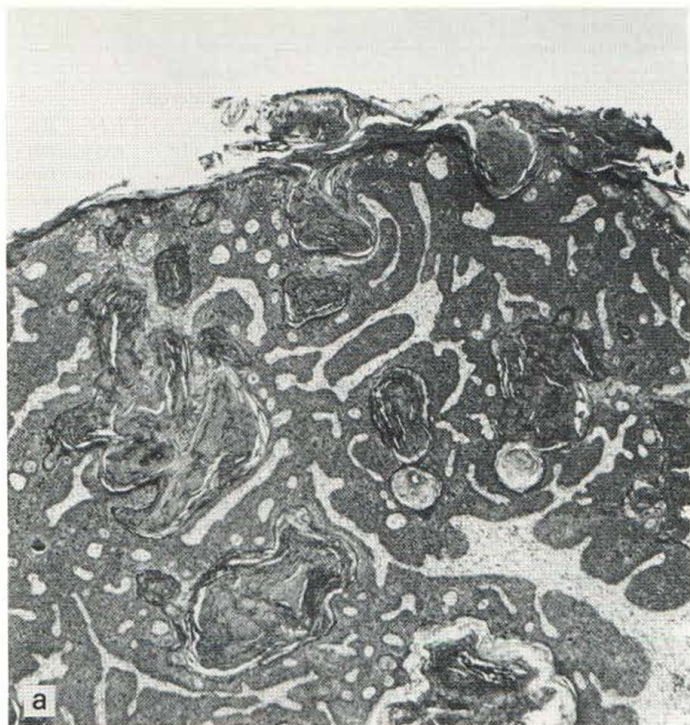

Fig. 1. Lesion from patient 2. Hyperkeratosis, epidermal hyperplasia, pseudohorn cysts, and sharply defined dermoepidermal junction (*a*). Cellular atypia with nuclear polymorphism, atypical mitoses and dyskeratosis (*b*).

Table I.

	Sex	Age	Location of tumor	Duration of tumor	Clinical diagnosis	Technique	Removal considered clinically radical	Removal considered histologically radical	Re-excision	Re-currence
Patient 1	f	67	Wrist, dorsal aspect	1-5 years	Seborrheic keratosis	Shave biopsy	Yes	Yes	No	No
Patient 2	f	63	Back of hand	4-5 years	Verrucous keratosis, seborrheic	Curettage	Yes	No	No	No
Patient 3	f	54	Posterior axillary fold	3-4 years	Verrucous keratosis, basal cell carcinoma?	Curettage	Yes	No	No	No

underlying epithelium displayed marked atypia (Fig. 1b). In some areas full thickness atypia of the epithelium was demonstrated. The dermoepidermal junction was well defined and no invasive growth was demonstrated. A lymphohistiocytic perivascular or lichenoid infiltrate was found in the dermis. Clinically the lesions appeared to be totally removed, but the biopsies showed that the atypical epithelial changes extended to lateral margins. Follow-up have so far shown no recurrences (Table I).

DISCUSSION

The keratoses removed from our patients are histologically identical to those previously described as squamous cell carcinoma in situ arising in seborrheic keratoses (2-6): Typical seborrheic keratoses with foci of cellular atypia. Based on his series of 14 patients with histologic atypia in seborrheic keratoses, but without signs of invasive growth or metastases, Kwittken states that "malignant transformation of a seborrheic keratosis contrary to the opinion of some authors, does take place" (3).

In the literature there is only one report, however, on true malignant behaviour, that is, metastasis, from a seborrheic keratosis with associated squamous cell carcinoma in situ (7), but the patient was lost for follow-up, and the possibility of an extracutaneous primary tumor was not excluded.

Clinically the seborrheic keratosis with cytologic atypia has no specific characteristics and is usually submitted as bona fide seborrheic keratosis, e.g. 9 of the 14 cases of Kwittken's (3). Notably, even though the atypia of the lesions in our patients extended to lateral margins, no recurrences have been observed during follow-up for 2 years (1-2 years). How should one act? Should all seborrheic keratoses be removed? Should a patient with atypia in one seborrheic keratosis have all his remaining (often dozens) of seborrheic keratoses excised? Should reexcisions of atypical lesions be performed in case of incomplete or even a complete primary procedure? It seems at present that the biologic behaviour of this type of lesion is benign (8) and specifically that no persuasive evidence for a malignant potential has been provided.

Consequently we find that no further steps need to be taken in long term control or reexcision. A single one-year-reexamination, when incomplete excision has been performed, may be appropriate.

ACKNOWLEDGEMENTS

We are grateful to the referring dermatologists, Dr Birgit Albrechtsen and Dr Hans W. Rothenborg for providing the clinical information. The skilful care of Mrs Birgitte Leisner in preparing the manuscript is greatly appreciated.

REFERENCES

1. Freudenthal W. Verruca senilis und Keratoma senile. Arch Dermatol Syph 1926; 152: 505-528.
2. Civatte MA. Un cas de verrue seborrhéique cancérisée. Bull Acad Mat Med (Paris) 1954; 138: 30-32.
3. Kwittken J. Malignant changes in seborrheic keratoses. Mt Sinai J Med 1974; 41: 792-801.
4. Bloch P. Transformation of seborrheic keratosis into Bowen's disease. J Cutan Pathol 1978; 5: 361-367.
5. Rahbari H. Bowenoid transformation of seborrheic verrucae (keratoses). Br J Dermatol 1979; 101: 459-463.
6. Baer RL, Garcia RL, Partsalidou V, Ackerman AB. Papillated squamous cell carcinoma in situ arising in a seborrheic keratosis. J Am Acad Dermatol 1981; 5: 561-565.
7. Christeler PA, Delacrétaz J. Verrues séborrhéiques et transformation maligne. Dermatologica 1966; 133: 33-39.
8. Booth JC. Atypical seborrheic keratosis. Aust J Dermatol 1977; 18: 10-14.

Numerous Papular Glomus Tumors Localized on the Abdomen: A Report of a Case and an Ultrastructural Study

N. HATCHOME, T. KATO and H. TAGAMI

Department of Dermatology, Tohoku University School of Medicine, Sendai, Japan

Hatchome N, Kato T, Tagami H. Numerous papular glomus tumor localized on the abdomen: A report of a case and an ultrastructural study. Acta Derm Venereol (Stockh) 1986; 66: 161-164.

Numerous, painless, dark-red small papules approximately 300 in number developed in a localized area of the left abdomen of a 16-year-old Japanese male in a course of 4 years. Histologically, there were dilated vascular spaces surrounded by one to three layers of cuboidal cells in the upper and mid dermis. Electron microscopic examination revealed the characteristic muscle cell structure of the tumour cells. To our knowledge there is no other report in the literature of such a case of localized multiple glomus tumors with numerous small papules and we think that this case represents a unique type in the multiple glomus tumor. *Key words: Glomus tumor; Multiple type.* (Received October 8, 1985.)

N. Hatchome, Department of Dermatology, Tohoku University School of Medicine, 1-1 Seiryomachi, Sendai 980, Japan.

Glomus tumor, first described by Masson in 1924 as a lesion arising from the specialized cutaneous arteriovenous shunts (cutaneous glomus), most commonly occurs as a painful firm purplish solitary nodule which appears on the extremities, especially in the nail bed. Multiple glomus tumors which consist of soft and compressible, bluish nodules occur with less frequency than solitary tumors (1). In some instances they are inherited as an autosomal dominant pattern.

We present here a unique case of multiple glomus tumors in which about 300 painless, small, red papules grouped on the left abdomen.