

Dermatitis herpetiformis: Selective Deposition of Immunoglobulin A1 in Granular Deposits in Clinically Normal Skin

TORBJÖRN EGELRUD

Department of Dermatology, University Hospital, Umeå, Sweden

Egelrud T. Dermatitis herpetiformis: Selective deposition of immunoglobulin A1 in granular deposits in clinically normal skin. *Acta Derm Venereol (Stockh)* 1986; 66: 11-15.

The subclass composition of IgA in granular deposits in the papillary dermis of clinically normal skin taken from 12 patients with dermatitis herpetiformis (DH) was determined using monoclonal IgA-subclass specific antibodies and immunofluorescence microscopy. In skin from one patient with extensive deposits of IgA minute amounts of IgA2 could be detected whereas IgA1 was found in all the biopsies examined. These findings favour the postulation that properties of certain IgA-molecules other than their antigen-binding specificity may cause their deposition in DH. *Key words: Skin; IgA; Subclasses.* (Received June 6, 1985.)

T. Egelrud, Department of Dermatology, University Hospital, S-901 85 Umeå, Sweden.

Many hypotheses regarding the mechanisms of IgA-deposition in clinically normal skin in dermatitis herpetiformis (DH) have been put forward (for review see 1). The suggestion that the antigen specificity of the IgA-molecules in some way or other directs them to the papillary dermis is common to all these hypotheses. However, there are other possibilities. One is that there are IgA-molecules produced in DH with special chemical properties in other parts of the peptide chains than in those making up the antigen binding site, that merely cause them to aggregate under the physico-chemical conditions prevailing in papillary dermis. Another possibility is suggested by the pronounced tendency for IgA-molecules to form aggregates other than antigen-antibody complexes. This aggregation occurs both with other IgA-molecules, giving rise to polymers of various sizes (2), and with other proteins such as serum albumin and α_1 -antitrypsin (2, 3). Most of these aggregates are stabilized by disulphide bonds which are broken by reduction but a non-reducible complex between α -chains and a non-immunoglobulin protein has also been described (4). Complexes other than antigen-antibody complexes with skin components or with components with special affinity for the skin can be envisaged.

The IgA in granular skin deposits in DH is polyclonal (1, 5). The finding of J-chains in the deposits (6) as well as biochemical characterization (7) show that part of the IgA is of the secretory polymeric type, indicating an origin in the intestine. There are two main subclasses of IgA: IgA1 and IgA2 (8). The structural differences between these subclasses are situated in the constant parts of the α -chains (2). 10-20% of the total serum IgA is IgA2, secretory IgA on the other hand consists of approximately equal amounts of IgA1 and IgA2 (8). About 50% of the IgA-producing cells in the small intestinal mucosa secrete IgA2, the remainder IgA1 (9, 10).

The work presented in this paper was based on the following assumption: If the IgA in granular deposits of DH-skin originates in the intestine as a result of polyclonal activation of IgA-producing cells with specificity for certain antigens, and if this antigen specificity directs the IgA to the skin as autoantibodies, crossreacting antibodies or in immunocomplexes with antigens with affinity for the skin, significant amounts of both IgA-subclasses should be found in the dermal deposits.

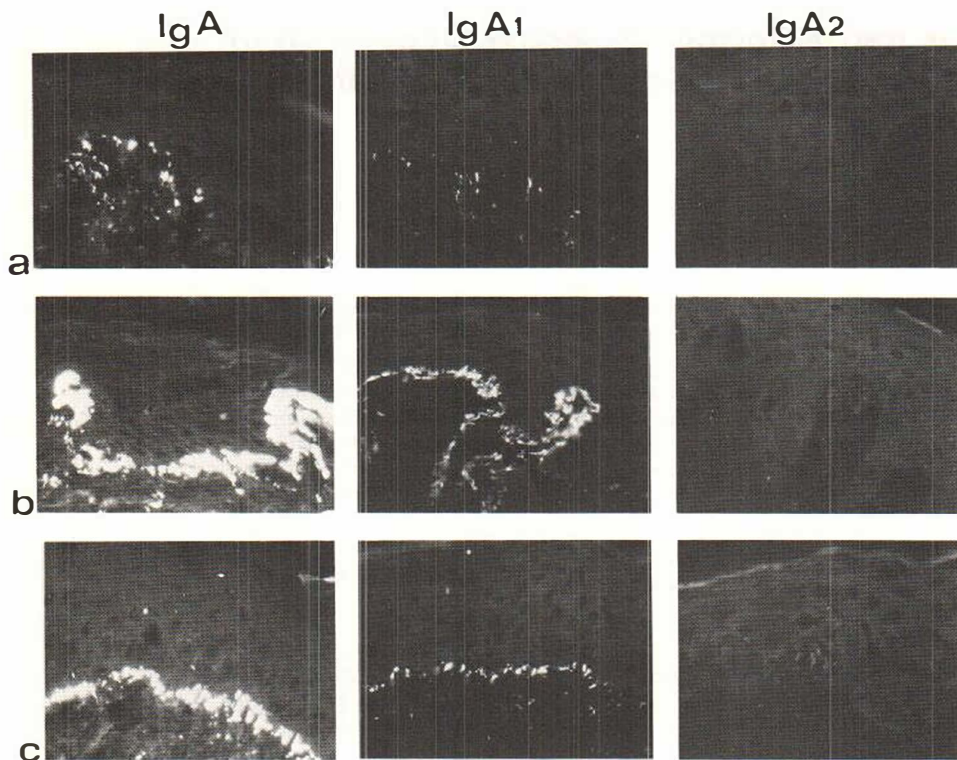


Fig. 1. Immunofluorescence microscopy. Total IgA, IgA1 and IgA2 in clinically normal skin from three different DH-patients. Monoclonal antibody dilution 1/10. Exposure times 120 sec. All photographs identically processed. *a*, *b* and *c* = patients 11, 10 and 8 respectively (see Table I). Reduced from $\times 400$.

We undertook a determination of IgA-subclasses in skin biopsies from twelve DH-patients. Minute amounts of IgA2 were found in one biopsy only whereas IgA1 was found in all the biopsies examined. The possible implications of these findings are discussed.

MATERIALS AND METHODS

Four mm punch biopsies were taken from patients with known DH, snap frozen and stored at -70°C . All patients had the granular pattern of IgA-staining.

Antibodies

Fluorescein-labelled rabbit anti-human α -chains were obtained from DAKOPATTS, Glostrup, Denmark and were used at a dilution of 1/10. Mouse monoclonal antibodies against human IgA1 (clone 1-155-1) and human IgA2 (clone 14-3-26) and fluorescein-labelled goat anti-mouse IgG (catalogue No. 99031) used in dilution 1/50 were from Becton Dickinson, Mechelen, Belgium. The two monoclonal antibodies stained individual cells in freeze sections of human pharyngeal tonsils, treated in the same way as the skin sections, with apparently similar intensities. Staining of these cells was positive at dilutions $1/5$ – $1/160$ for both antibodies.

Immunofluorescence microscopy

Four μ freeze sections of skin biopsies were fixed in acetone at room temperature for 10 min before staining. The time for incubation at room temperature with antibodies was 30 min and for washings 2×10 min. Phosphate buffered saline was used for dilutions and washings. Immunofluorescence

Table I. Total IgA and subclasses of IgA in granular deposits in papillary dermis from DH-patients

Results of immunofluorescence microscopy. Dilutions of first antibodies for IgA1 and IgA2 1/10

Biopsy from patient no.	IgA	IgA1	IgA2
1	++*	+	-
2	+++	++	-
3	++++	+++	-
4	++++	+++	-
5	++	+	-
6	+++	+	-
7	+++	++	-
8	++++	+++	+
9	++	++	-
10	++++	+++	-
11	++	++	-
12	+++	++	-

* +=positive fluorescence detectable at magnification 400 \times . ++=positive fluorescence detectable at magnification 160 \times . +++=positive fluorescence detectable at magnification 63 \times . ++++=positive fluorescence detectable at magnification 25 \times .

microscopy with incident light and photographing was performed as previously described (11). The lowest magnification at which fluorescing granular IgA-deposits could be seen was recorded in order to get a semiquantitative measure of the amount of bound antibodies.

RESULTS

Biopsies of clinically normal skin from 12 patients with DH were subjected to immunofluorescence microscopy after staining with polyclonal rabbit anti-human α -chains and with monoclonal antibodies specific for subclass-determinants of IgA. The results are summarized in Table I and Fig. 1. The biopsies were deliberately chosen to give a wide variation of the intensities of IgA-fluorescence. All 12 biopsies, even those with the weakest reactions for IgA, stained positively for IgA1 in a pattern similar to that obtained with the polyclonal rabbit antiserum to α -chains. In contrast, only one biopsy with extensive IgA-staining produced a weak positive reaction for IgA2. IgA1-positive stainings were obtained with antibody dilutions 1/5–1/160 (tested on biopsies from patients 8, 10 and 11). The IgA2-positive reaction for the biopsy from patient 8 was positive at dilution 1/40 but not at 1/80. Fig. 1 shows the results for one biopsy with a rather weak IgA-staining, one biopsy with extremely extensive IgA-staining and the biopsy positive for IgA2.

DISCUSSION

If the IgA2-determinant 'seen' by the used monoclonal antibody was not hidden in the examined skin biopsies (as it was not in the positive controls from pharyngeal tonsils) and if any deposited IgA2 is not selectively removed *in vivo* or during the experimental procedures, our results would suggest that IgA1 is selectively deposited in the papillary dermis of clinically normal skin in DH.

This situation is analogous to what has been reported for mesangial IgA-deposits in

different forms of IgA-nephritis where IgA1 is exclusively found (12). IgA-nephritis is often preceded by inflammatory mucosal conditions (13, 14) with increased production of secretory IgA, and if the antigen-binding properties of this IgA were the only essential requisites for part of it being deposited in the kidneys, both IgA-subclasses should be found in the deposits. Mesangial IgA-deposits, with or without signs of nephritis, have also been reported in celiac disease and DH (15, 16).

We have recently reported on the biochemical characterization of granular IgA-deposits in DH (7). We found significant amounts of monomeric as well as polymeric IgA which, upon reduction, yielded α -chains and light chains. In addition, however, a major fraction of the IgA-like material was found to be made up of complexes that retained their high molecular weight after reduction and alkylation in the presence of sodium dodecyl sulphate, suggesting that this IgA was present as complexes with itself or with other proteins stabilized by other covalent bonds than S-S bonds (7). Since the IgA-deposits are found in clinically normal skin, where capillary permeability should be normal, the most plausible explanation seems to be that these high molecular weight complexes containing IgA are being formed *in situ*, possibly from smaller aggregates from the blood stream.

Taken together, our previous findings (7), the findings in this report that the granular IgA-deposits contain almost exclusively IgA1 and the known tendency of IgA to form covalent complexes, reducible as well as non-reducible, with itself and with other proteins (2-4), offer an alternative mechanism for the formation of granular IgA-deposits in DH-skin.

Existing hypotheses about DH assume that the antigen-binding properties of certain IgA-molecules in some way or other direct them to the skin. Proof for these hypotheses must be based on the demonstration of specific antigens to the deposited IgA. Until such antigens are found, mechanisms of deposition based on the special properties of other parts of the IgA-molecules than their antigen-binding sites should be further considered.

ACKNOWLEDGEMENTS

The skillful technical assistance of Ms Astrid Lundgren is gratefully acknowledged. Financial support was obtained from the University of Umeå, the Edvard Welander Foundation and the Finsen Foundation.

REFERENCES

1. Katz SI, Strober W. The pathogenesis of dermatitis herpetiformis (review). *J Invest Dermatol* 1978; 70: 63-75.
2. Heremans JF. Immunoglobulin A. In: Sela, M, ed. The antigens, vol 2. New York: Academic Press, 1974: 365-522.
3. Laurell C-B, Thulin E. Complexes in human plasma between α_1 -antitrypsin and IgA, and α_1 -antitrypsin and fibrinogen. In: Axelsen, NH, ed. Quantitative immunoelectrophoresis. Oslo: Universitetsforlaget, 1975: 7-12.
4. Grubb AO, López C, Tejler L, Mendez E. Isolation of human complex-forming glycoprotein, heterogeneous in charge (protein HC) and its IgA-complex from plasma. *J Biol Chem* 258: 14698-14707.
5. Meer JB van der. Dermatitis herpetiformis: a specific (immunopathological?) entity. Leiden: Univ. Bookshop C. Kooyker, 1972.
6. Unsworth DJ, Payne AW, Leonard JN, Fry L, Holborow EJ. IgA in dermatitis herpetiformis skin is dimeric. *Lancet* 1982; i: 478-480.
7. Egelrud T, Bäck O. Dermatitis herpetiformis: Biochemical properties of the granular deposits of IgA in papillary dermis. Characterization of SDS-soluble IgA-like material and potentially antigen-binding IgA fragments released by pepsin. *J Invest Dermatol* 1985; 84: 239-245.
8. Grey HM, Abel CA, Yount WJ, Kunkel HG. A subclass of γ A-globulins (γ A2) which lacks the disulfide bonds linking heavy and light chains. *J Exp Med* 1968; 128: 1223-1236.

9. André C, André F, Fargier C. Distribution of IgA1 and IgA2 plasma cells in various normal tissues and in jejunum of plasma IgA-deficient patients. *Clin Exp Immunol* 1978; 3: 327-331.
10. Crago SS, Kutteh WH, Prince SJ, Radl J, Haaijman JJ, Mestecky J. Distribution of IgA1 and IgA2 subclasses in human tissue: Correlation with the presence of J-chain. *Ann New York Acad Sci* 1983; 409: 803-805.
11. Egelrud T, Bäck O. Dermatitis herpetiformis: Preparation of papillary dermis and the effect of proteolytic enzymes on the IgA-deposits. *J Invest Dermatol* 1984; 82: 501-505.
12. Conley ME, Cooper MD, Michael AF. Selective deposition of immunoglobulin A1 in immunoglobulin A nephropathy, anaphylactoid purpura nephritis, and systemic lupus erythematosus. *J Clin Invest* 1980; 66: 1432-1436.
13. Berger J. IgA glomerular deposits in renal disease. *Transplant Proc* 1969; 1: 939-944.
14. Finlayson G, Alexander R, Juncos L, Schlein E, Teague P, Waldman R, Cade R. Immunoglobulin A glomerulonephritis, a clinicopathological study. *Lab Invest* 1975; 32: 140-148.
15. Helin H, Mustonen J, Reunala T, Pasternack A. IgA nephropathy associated with celiac disease and dermatitis herpetiformis. *Arch Pathol Lab* 1983; 107: 324-327.
16. Reunala T, Helin H, Pasternack A, Linder E, Kalimo K. Renal involvement and circulating immune complexes in dermatitis herpetiformis. *J Am Acad Dermatol* 1983; 9: 219-223.