

HLA-DR-Antigen Bearing Keratinocytes in Various Dermatologic Disorders

JOSEF SMOLLE

Department of Dermatology, and Venerology, University of Graz, Graz, Austria

Smolle, J. HLA-DR-antigen bearing keratinocytes in various dermatologic disorders. *Acta Derm Venereol (Stockh) 1985; 65: 9-13.*

In normal human epidermis HLA-DR-antigen is only present on Langerhans' cells and the acrosyringeal epithelium. We investigated the distribution of HLA-DR-antigen in 78 specimens of various skin diseases by an immunoperoxidase method using a monoclonal anti-HLA-DR antibody. HLA-DR-antigen bearing keratinocytes were not only found in lichen planus and mycosis fungoides, as it has been referred previously, but were also observed in some cases of cutaneous B-cell lymphoma, pseudolymphoma, lupus erythematosus, parapsoriasis en plaque, bullous pemphigoid, drug reaction, contact dermatitis, actinic keratosis and verrucous carcinoma. Direct contact of lymphoid cells with keratinocytes was not necessary for Ia-antigen expression. (Received June 13, 1984.)

J. Smolle, Department of Dermatology and Venerology in Graz, University of Graz, Auenbruggerplatz 8, A-8036 Graz, Austria.

The major histocompatibility complex region in man codes for two different types of antigens. Class I antigens (HLA-A, -B, and-C) are expressed on almost all cells, whereas class II antigens have a restricted distribution. The class II antigens are also called HLA-DR antigens or—in analogy to the mouse system—Ia-antigens. They are commonly considered to play a role in antigen presentation and elicitation of immune response (1).

HLA-DR-antigen was primarily observed in immune competent cells, such as B-cells, activated T-cells, macrophages, and Langerhans' cells. However, further investigations revealed HLA-DR-antigen on vascular endothelia (2), lactating breast epithelium (3), acrosyringeal epithelium (4) and melanoma cell lines (5).

Within the normal epidermis Langerhans' cells regularly express HLA-DR-antigen, whereas keratinocytes acquire this antigen only in disease state: Lichen planus (6), mycosis fungoides (7, 8), graft-versus-host disease (8-11), and tuberculin reaction (12) have been reported up to now. The aim of our study was to investigate the expression of class II antigens on keratinocytes in various inflammatory and neoplastic skin diseases.

MATERIAL AND METHODS

Specimens. A total of 78 specimens was evaluated. The diagnoses were as follows: 48-hour patch test reaction (3 cases), acute allergic contact dermatitis (2), chronic allergic contact dermatitis (15), lichen planus (5), lupus erythematosus (2), bullous pemphigoid (2), dermatitis herpetiformis (1), parapsoriasis en plaque (3), pseudolymphoma (7), mycosis fungoides (6), Sézary's syndrome (3), T-cell chronic lymphocytic leukemia (1), polymorphic immunocytoma (1), B cell-chronic lymphocytic leukemia (3), centrocytic-centroblastic lymphoma (1), drug reaction (3), milker's nodule (1), purpuric lichenoid eruption (1), seborrheic dermatitis (1), atopic dermatitis (1), scleroderma (1), lymphocytic infiltration (1), foreign body granuloma (1), chronic myeloid leukemia (1), chronic pyoderma (2), trichophytosis (1), basaloma (1), verrucous carcinoma (1), actinic keratosis (1), cutaneous metastases of bronchial carcinoma (1).

Biopsies were obtained under local anesthesia. Material was processed for routine histology (paraffin sections) and immunohistochemistry (frozen sections).

Staining procedure. 5 µm cryostat sections were air dried, fixed in acetone for 10 min and mounted with anti-HLA-DR mouse monoclonal antiserum (OKIa1; Ortho Pharmaceutical Corporation) diluted

1:100 in PBS containing 1% bovine serum albumin. After an incubation of 30 min slides were rinsed and a peroxidase conjugated rabbit anti mouse immunoglobulin (Dako) was applied as secondary reagent for another 30 min. Slides were washed again and the staining reaction was achieved by aminoethylcarbazole and hydrogen peroxide. The sections were counterstained with Mayer's hematoxylin and coverslipped using glycerine gelatine. For further details see Huber et al. (13).

Controls. Human tonsils served as positive controls. For negative controls, the primary antibody was omitted. Parallel sections of each skin biopsy were additionally stained with a panel of other monoclonal antibodies: OKT 11, OKT 6 (Ortho Pharmaceutical Corporation); Leu 2a, Leu 3a, Leu 12 (Becton Dickinson).

RESULTS

In all sections Langerhans' cells and a remarkable portion of the dermal infiltrate stained positive for HLA-DR-antigen. It was also regularly detected on the acrosyringium of eccrine sweat glands. Besides this, 24 out of 78 specimen (31%) revealed a remarkable staining of keratinocytes, which was either confined to the basal and suprabasal layer or involved the whole stratum spinosum and occasionally the granular layer too. In a few cases a cytoplasmic staining reaction of keratinocytes was evident.

The number of positive cases in each diagnosis is listed in Table 1. In contact dermatitis, 2 out of 20 cases were positive (Fig. 1). Lichen planus lesions regularly revealed an intercellular staining pattern, which in areas of basal cell damage involved the whole epidermis. Both cases of lupus erythematosus (chronic discoid and systemic) showed small foci of HLA-DR-antigen bearing keratinocytes. From 3 specimens of parapsoriasis en plaque one was plainly positive. This case clinically appeared as large plaque type with more than 20 years duration.

HLA-DR-positive keratinocytes were also detected in pseudolymphoma, T-cell chronic lymphocytic leukemia (Fig. 2), mycosis fungoides, B-cell chronic lymphocytic leukemia, and polymorphic immunocytoma (Fig. 3). Positive results were additionally found in the following diagnoses: chronic persistent drug reaction (Fig. 4), foreign body granuloma, actinic keratosis, and verrucous carcinoma.

A dermal infiltrate consisting of mononuclear cells was present in each case. The relative amount of lymphocyte subsets as defined by monoclonal antibodies (OKT 11, Leu 2a, Leu 3a, and Leu 12) varied according to the diagnosis, but, remarkably, a considerable number of T-helper-inducer cells (Leu 3a+) occurred in all cases including B-cell lymphomas and pseudolymphomas. There was no correlation between the expression of HLA-DR-antigen on keratinocytes and the epidermotropism of the lymphocytes.

Table 1. *HLA-DR-antigen bearing keratinocytes in 78 biopsy specimens*

Diagnosis	Number of specimens positive/total
Contact dermatitis	2/20
Lichen planus	5/5
Lupus erythematosus	2/2
Bullous dermatoses	1/3
Parapsoriasis en plaque	1/3
Pseudolymphoma	2/7
T-cell lymphoma	3/11
B-cell lymphoma	3/9
Others	5/18
Total	24/78

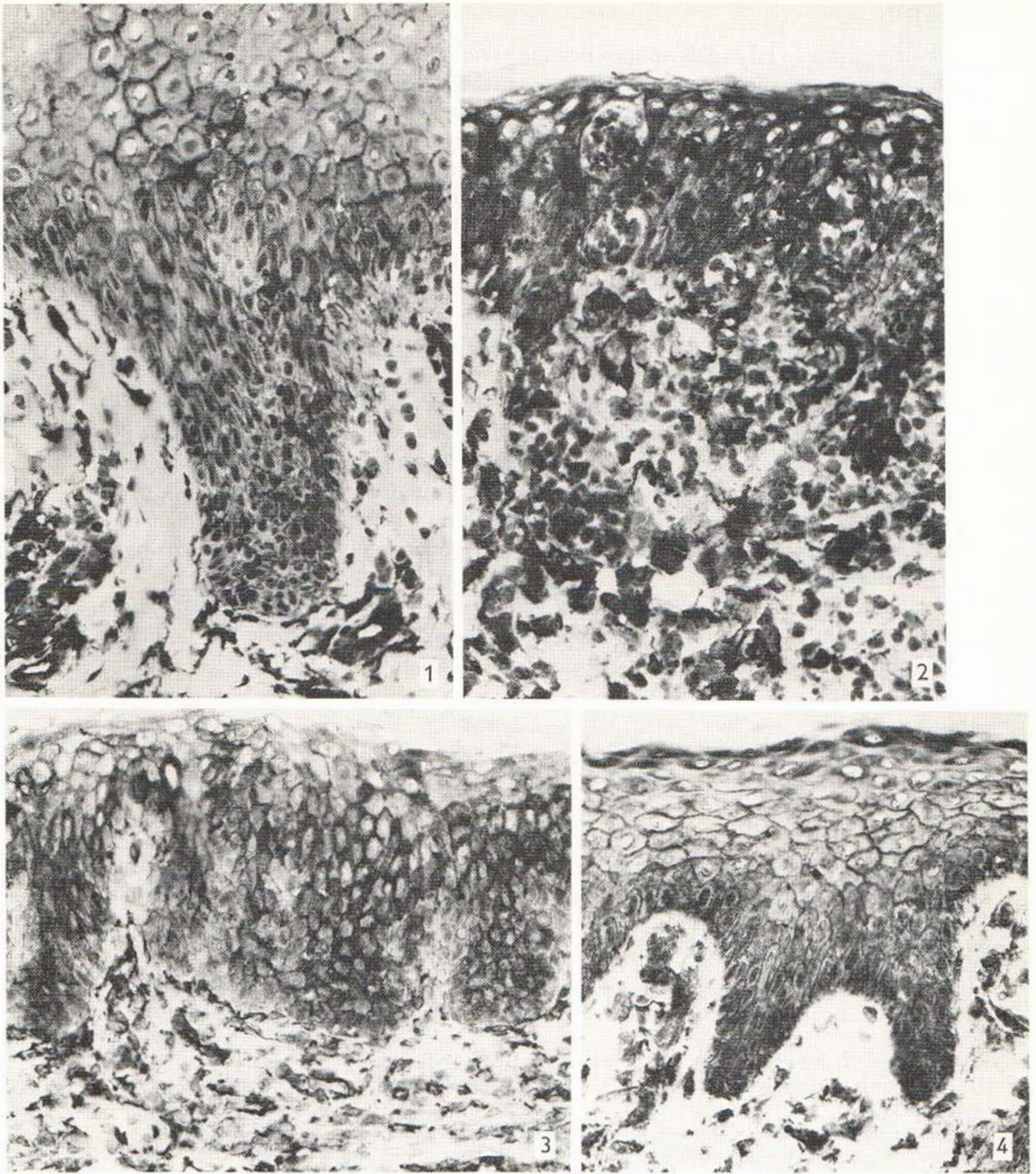


Fig. 1. Chronic allergic contact dermatitis, immunohistological demonstration of HLA-DR-antigen: Keratinocytes of the basal and suprabasal layer are stained. $\times 250$.

Fig. 2. T-cell chronic lymphocytic leukemia, immunohistological demonstration of HLA-DR-antigen: Marked epidermotropism and formation of Pautrier's microabscesses are evident. There is strong staining of keratinocytes up to the stratum corneum. $\times 250$.

Fig. 3. Polymorphic immunocytoma, immunohistological demonstration of HLA-DR-antigen: There is no epidermotropism, but a free "grenz zone" underneath the epidermis. Keratinocytes of the basal, suprabasal and of the lower spinous layer bear HLA-DR-antigen. $\times 250$.

Fig. 4. Chronic persistent drug reaction, immunohistological demonstration of HLA-DR-antigen: Keratinocytes are positive up to the granular layer. $\times 250$.

DISCUSSION

Our study demonstrates HLA-DR-antigen bearing keratinocytes in a variety of inflammatory skin diseases including lupus erythematosus, drug reaction, bullous pemphigoid, parapsoriasis en plaque, and pseudolymphoma. The regular appearance of HLA-DR-antigen on keratinocytes in lichen planus is confirmed by our observations.

We also found HLA-DR-antigen positive keratinocytes in some neoplastic skin diseases: The occurrence in mycosis fungoides has already been observed by other investigators (7, 8). Additionally, we detected HLA-DR-positive keratinocytes also in a case of T-cell chronic lymphocytic leukemia and 3 B-cell lymphomas.

HLA-DR-antigen bearing keratinocytes also appeared in actinic keratosis and in verrucous carcinoma. As there was a mononuclear infiltrate in both cases, the expression of HLA-DR-antigen might either be due to this infiltrate or associated with the degree of differentiation of the neoplastic cells.

Our study shows, that direct contact between inflammatory cells and keratinocytes is no prerequisite for epidermal HLA-DR-antigen expression. However, an infiltrate containing T-helper-cells was always present in the dermis. These findings indicate, that a soluble factor produced in the mononuclear infiltrate could be responsible for HLA-DR expression. Recent experimental data suggest a possible role of gamma-interferon, which is synthesized by T-helper cells and stimulates HLA-DR production in both T-cells (15) and cultured keratinocytes (16).

We conclude that HLA-DR-antigen bearing keratinocytes appear in pathologic conditions more frequently than previously suggested. A factor derived from the dermal infiltrate might be responsible for HLA-DR-positive keratinocytes.

ACKNOWLEDGEMENT

Mrs A. Blaser is kindly thanked for excellent technical assistance.

REFERENCES

1. Resch K, Hemsä D. Immunsystem. In: *Immunologie: Grundlagen-Klinik-Praxis*. (Vorlaender KO, ed.) Stuttgart, New York: Georg Thieme Verlag 1983; 2-43.
2. Hirschberg H, Braathen LR, Thorsby E. Antigen presentation by vascular endothelial and epidermal Langerhans cells. The role of HLA-DR. *Immunol Rev* 1982; 66: 57-77.
3. Wiman K, Curman B, Forsum U, Klareskog L, Malmnäs-Tjernlund U, Rask L, Trägårdh L, Peterson PA. Occurrence of Ia antigens on tissues of non-lymphoid origin. *Nature* 1978; 276: 711-713.
4. Murphy GF, Shepard RS, Harrist TJ, Bronstein BR, Bhan AK. Ultrastructural documentation of HLA-DR antigen reactivity in normal acrosyringeal epithelium. *J Invest Dermatol* 1983; 81: 181-183.
5. Winchester RJ, Wang C-Y, Gibowsky A, Runkel HG, Lloyd KO, Old LJ. Expression of Ia-like antigens on cultured human malignant melanoma cell lines. *Proc Natl Acad Sci USA* 1978; 75: 6235.
6. Malmnäs-Tjernlund U. Ia-like antigens in lichen planus. *Acta Derm Venereol (Stockh)* 1980; 60: 309.
7. Malmnäs-Tjernlund U. Epidermal expression of HLA-DR antigens in mycosis fungoides. *Arch Dermatol Res* 1978; 261: 81.
8. Volc-Platzer B, Majdic O, Knapp W, Wolff K, Hinterberger W, Lechner K, Stingl G. Evidence of HLA-DR antigen biosynthesis by human keratinocytes in disease. *J Exp Med* 1984; 159: 1784-1789.
9. Daynes RA, Emam M, Kreuger GG, Roberts LK. Expression of Ia antigen on epidermal keratinocytes after the grafting of normal skin to nude mice. *J Immunol* 1983; 130: 1536-1539.
10. Lampert IA, Suitters AJ, Chisholf PM. Expression of Ia antigen on epidermal keratinocytes in graft versus host disease. *Nature* 1981; 293: 149-150.

11. Mason DW, Dallman M, Barclay AN. Graft versus host disease induces expression of Ia antigen in rat epidermal cells and gut epithelium. *Nature* 1981; 293: 5828.
12. Sheynius A, Tjernlund U. Human keratinocytes express HLA-DR antigens in the human tuberculin reaction. *Scand J Immunol* 1984; 19: 141-147.
13. Huber H, Portner B, Gabl F. Laboratoriumsdiagnose hämatologischer Erkrankungen. I. Hämatologie und Immunhämatologie. Berlin. Heidelberg, New York, Tokyo: Springer-Verlag, 1983: 464-467.
14. Suitters AJ, Lampert IA. Expression of Ia antigen on epidermal keratinocytes is a consequence of cellular immunity. *Br J Exp Pathol* 1982; 63: 207-213.
15. Basham TY, Merigan TC. Recombinant interferon increases HLA-DR synthesis and expression. *J Immunol* 1983; 130: 1492.
16. Volc-Platzer B, Luger Th, Leibl H, Zahn G, Stingl G. Human epidermal cells synthesize HLA-DR alloantigens in vitro upon stimulation with γ -interferon. Submitted for publication.