

# Diffuse Fasciitis with Eosinophilia Associated with Morphea and Lichen sclerosus et atrophicus

HARTWIG MENSING and KLAUS-ULLRICH SCHMIDT

*Department of Dermatology, University of Hamburg, Hamburg, Federal Republic of Germany*

Mensing H, Schmidt KU. Diffuse fasciitis with eosinophilia associated with morphea and lichen sclerosus et atrophicus. *Acta Derm Venereol (Stockh)* 1985; 65: 80-83.

Diffuse fasciitis with eosinophilia (DFE) is a well described syndrome, among the connective tissue disorders. However, DFE is not commonly accepted as an own entity, because of its rare evolvement in scleroderma and the often indistinguishable histological pattern of both diseases. Here we report on the association of DFE and morphea in two patients and an additional lichen sclerosus in one of them. This points to a close relationship of DFE and other connective tissue diseases. *Key words: Shulman syndrome; Connective tissue diseases.* (Received June 1, 1984).


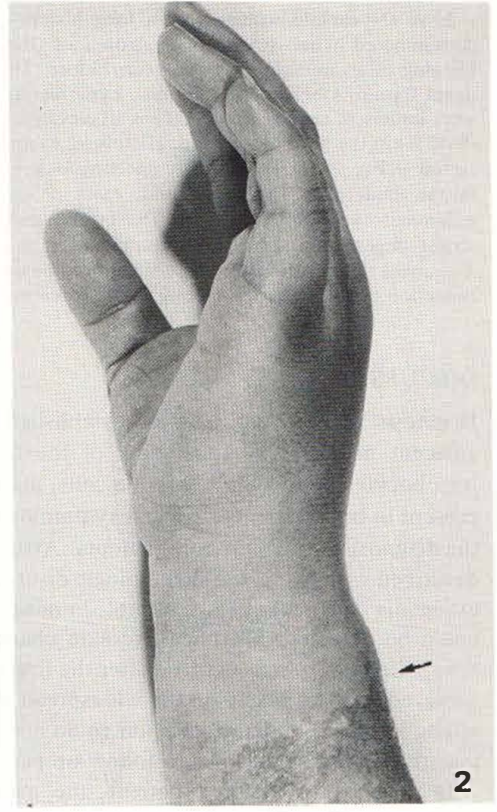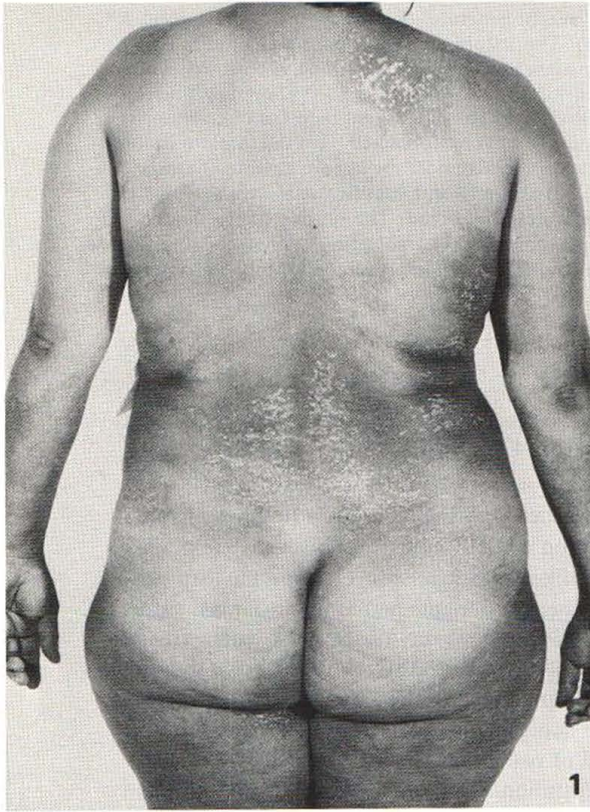
H. Mensing, Universitäts-Hautklinik Hamburg, Martinistr. 52, D-2000 Hamburg 20, West-Germany.

Diffuse fasciitis with eosinophilia (DFE) was first described as an entity 1974 by Shulman et al. (1). Since then nearly 100 cases have been reported in the world literature (2, 3, 4). Although some negative criteria of DFE are suitable to separate this disease from progressive systemic scleroderma (PSS), there is so far no general agreement to classify the disease within the group of connective tissue diseases. We report here on two cases of DFE, both associated with morphea, in one case additionally linked with lichen sclerosus et atrophicus.

## CASE REPORT

1. A 45-year-old woman suddenly became aware of swollen forearms. A short time later the edema was replaced by a more indurated, fibrous hardening of the tissue. The indurations spread during the next months over nearly the whole body leaving only the face unaffected. She had never recognized periods of Raynaud's phenomenon, nor had she subsequently developed any internal manifestation as seen in PSS. Laboratory examinations uncovered an increased ESR (40-70/lh) and 15-25% eosinophilic granulocytes in the differential blood count. Other findings were in normal range. The diagnosis of DFE was ensured by a deep biopsy including the fascia and adjacent muscle. One year later morphea-like lesions appeared in the region of the breast and neck. The forearms and thighs developed a lilac-coloured inflammation resembling linear morphea in this area and the histological examination confirmed the diagnosis of morphea.

At the same time overall induration of the skin increased and a low-dose corticosteroid therapy (40 mg prednisolone/day) was started. All indurated lesions as well as both types of morphea-like lesions improved. Some weeks after finishing the steroid therapy a slow impairment of the lesions was observed. Relapses occurred for several times after increasing and reducing the dose of steroids.



*Fig. 1.* Back of patient 2. Widespread burned-out morphea plaques and disseminated "white spot disease" (lichen sclerosus).

*Fig. 2.* Forearm and hand of patient 2. Swelling of the forearm and handwrist. Arrow: site of biopsy.

*Fig. 3.* Biopsy specimen obtained from the forearm of patient 2 (see arrow Fig. 2). Inflammatory reaction in the adjacent muscle consisting of lymphocytes, neutrophils and eosinophils (arrows). In part complete destruction of the muscle architecture by the inflammatory process.

2. A 41-year-old woman had a long history of nearly generalized, burned-out morphea and a disseminated lichen sclerosus et atrophicus (Fig. 1). The nature of both lesions was confirmed by histological examination several years before. This patient now developed swelling of both wrists and distal forearms behind the circular, hyperpigmented morphea lesions (Fig. 2). Laboratory findings were largely in normal range except an elevated ESR (35 mm/h) and a slight increase of eosinophils (6–12 %) in the periphery blood. Histologic examination of a biopsy obtained from the forearm lesion (arrow in Fig. 2) showed a nearly unchanged dermis and subcutis under the hyperpigmented basal line of the epidermis. The fascia and, more pronounced, the adjacent muscle were involved by an inflammatory infiltrate (Fig. 3). The fascia was moderately thickened. The muscle fibers showed a strong degeneration. Only the empty cover of the sarcolemma was sometimes traceable (Fig. 3). Treatment with corticosteroids (20 mg prednisolone/day) lead to an improvement of the swelling and reduction of the strangled feeling in the forearms.

## DISCUSSION

Diagnosis of DFE can only be established by a deep skin biopsy including fascia and adjacent muscle (2). Thickening of the fascia and inflammatory reactions containing lymphocytes, neutrophils, plasma cells, mast cells and (not necessarily) eosinophils were present in both patients. Clinical symptoms together with the laboratory findings ensured the diagnosis of DFE in both patients. Association of DFE with other diseases are mainly described with respect to hematologic disorders like aplastic anemia (5), immune thrombocytopenia or Hodgkin's disease (6). In none of the two patients hematologic abnormalities could be detected. Morphea-like skin changes were, however, observed in each. In the first patient morphea occurred after the first manifestation of DFE. Corticosteroid therapy achieved positive results in the widespread DFE and morphea lesions. On the other hand, a long lasting complete remission could not be achieved as relapses of morphea and DFE occurred several times over a follow-up period of two years.

In contrast to the first patient, the manifestation of a nearly generalized morphea appeared in the second patient long before the DFE lesions were noted. Simultaneously with the morphea, lichen sclerosus et atrophicus was observed in this patient. To our knowledge only one case of coincidence of DFE and severe generalized morphea has been reported previously (7). But in spite of undeniable, clinical and laboratory findings the authors did not believe that their patient really suffered from DFE. Recently the direct transformation of previously DFE-like appearing lesions into PSS within three months has been described (7). Accordingly late occurring internal involvement cannot be ruled out in other cases (8). There are, however two facts that distinguish DFE from PSS: the good prognosis in most of the reported patients without involvement of internal organs during a long-time follow-up and the above mentioned better response to therapy. This supports the assumption of an exceptional position of DFE in the class of connective tissue disorders. Moreover, the findings in nailfold capillaroscopy (9) and the proof of eosinophilic chemotactic factor in the serum of DFE patients (10) support its position as an own entity. The two patients suffered from symptoms clearly connected with DFE. The association with morphea and lichen sclerosus, two other disorders of connective tissue with unknown etiology, points to a close relationship between disorders affecting the connective tissue. Therefore DFE as an own entity should be kept in mind in discussions until further evidence will be presented allowing to give an affirmative answer to the question of Shulman in his first report (1): Diffuse fasciitis with eosinophilia and hypergammaglobulinemia— a new syndrome?

## ACKNOWLEDGEMENT

This work was supported by Deutsche Forschungs-Gemeinschaft, Me 766-2/1.

## REFERENCES

1. Shulman L. Diffuse fasciitis with eosinophilia and hypergammaglobulinemia: a new syndrome? *J Rheumatol* 1974; 1: 46.
2. Barnes L, Rodnan GP, Medsger TA, Short D. Eosinophilic fasciitis. *Am J Pathol* 1979; 96: 493-507.
3. Mensing H, Meigel W, Jänner M. Diffuse fasciitis with eosinophilia. *Z Hautkr* 1981; 57: 707-717.
4. Michet CJ, Doyle JA, Ginsburgh JW. Eosinophilic fasciitis: report of 15 cases. *Mayo Clin Proc* 1981; 56: 27-34.
5. Shulman LE, Hoffmann R, Dainiak N, Negbitt J, Adelman AM. Antibody-mediated aplastic anemia and thrombocytopenic purpura in diffuse fasciitis. *Clin Res* 1979; 27: 514 A.
6. Michaels RM. Eosinophilic fasciitis complicated by Hodgkin's disease. *J Rheumatol* 1982; 9: 473-476.
7. King DF, Dore RK, Gilbert DJ, Gurevitch AW, Hirose FM. Generalized morphea with peripheral eosinophilia, fasciitis and myositis. *Int J Dermatol* 1980; 19: 149-153.
8. Jarratt M, Bybee JB, Ramsdell W. Eosinophilic fasciitis—an early variant of scleroderma. *J Am Acad Dermatol* 1979; 221-226.
9. Rozboril MB, Maricq HR, Rodnan GP, Jablonska S, Bole RG. Capillary microscopy in eosinophilic fasciitis. *Arthritis Rheum* 1983; 26: 617-622.
10. Wasserman SJ, Seibold JR, Medsger TA, Rodnan GP. Serum eosinophilotactic activity in eosinophilic fasciitis. *Arthritis Rheum* 1982; 25: 1352-1356.