

Retinoid Dermatitis Mimicking Progression in Mycosis Fungoides: A Report from the Scandinavian Mycosis Fungoides Group

LARS MOLIN,¹ KRISTIAN THOMSEN,² GUNNAR VOLDEN³
and GUNHILD LANGE WANTZIN²

Departments of Dermatology, ¹University Hospital, Linköping, Sweden. ²Finsen Institute, Copenhagen, Denmark, and ³University Hospital, Tromsø, Norway

Molin L, Thomsen K, Volden G, Lange Wantzin G. Retinoid dermatitis mimicking progression in mycosis fungoides. *Acta Derm Venereol* (Stockh) 1985; 65:69-71.

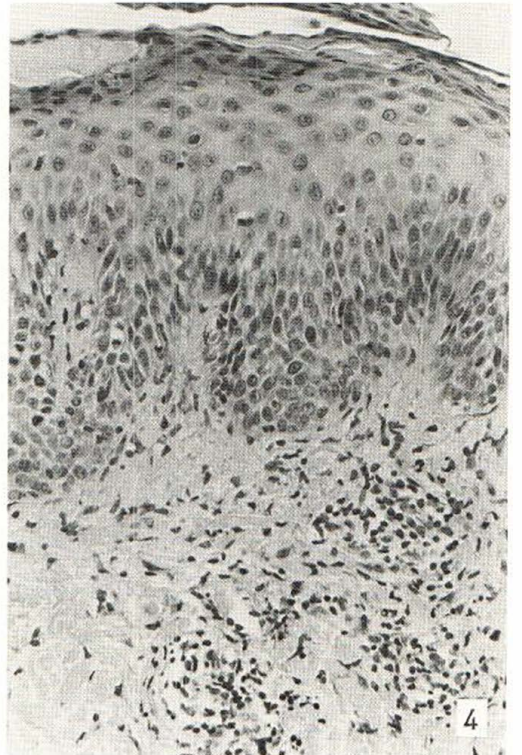
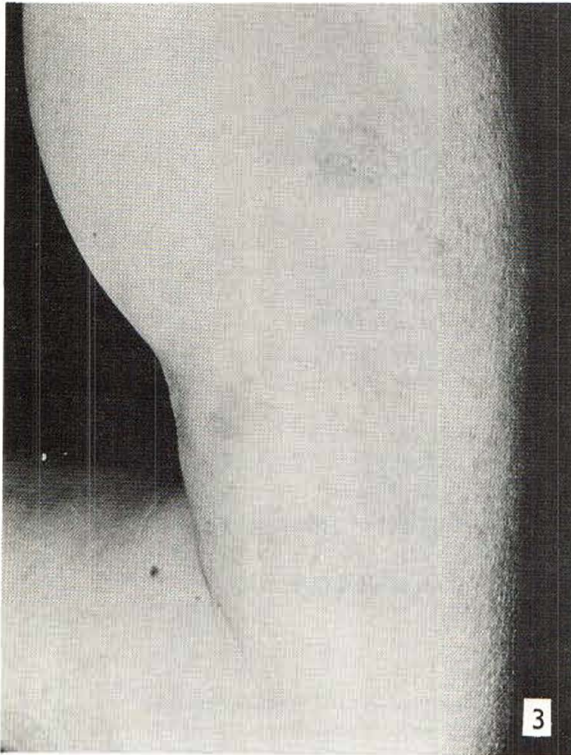
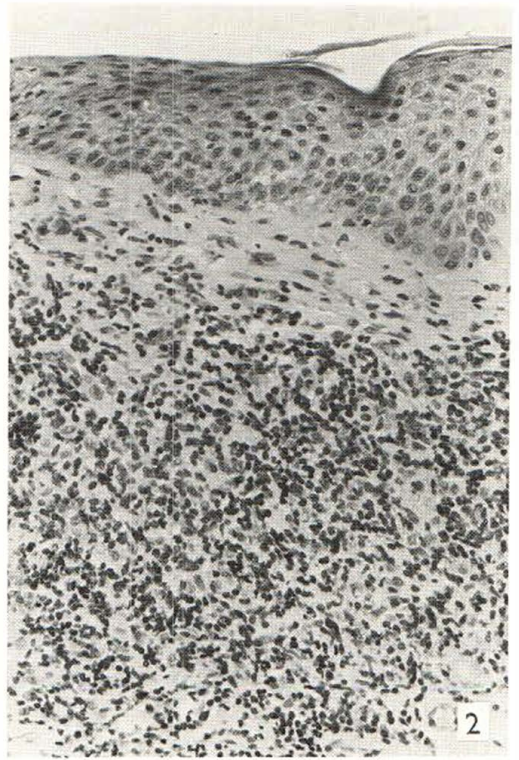
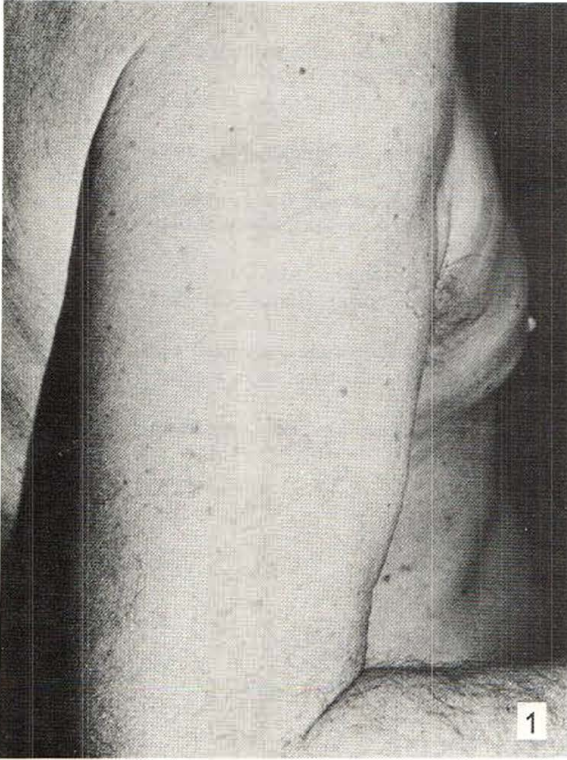
A dermatitis occurring during the treatment of mycosis fungoides with A vitamin analogues (13-cis-retinoic acid and etretinate) and mimicking a progression of the disease is described. It is considered to be a skin reaction due to the treatment. Its benign nature is revealed by histology showing a lymphocytic infiltrate without any atypical sign. *Key words: Mycosis fungoides; Retinoid; Retinoid dermatitis.* (Received July 24, 1984.)

L. Molin, Department of Dermatology, University Hospital, S-581 85 Linköping, Sweden.

The therapeutic value of retinoids in mycosis fungoides is at present in a process of being established, in particular regarding 13-cis-retinoic acid, Roaccutan® (1, 2, 3), but also etretinate, Tigason® (4, 5). When using these A vitamin analogues side effects such as skin erythema, dryness and scaling are well-known. During the treatment of a series of mycosis fungoides patients we have encountered a skin reaction, which might be misinterpreted as a progression of the disease and thus result in erroneous withdrawal of treatment.

CASES

Eight cases with histologically verified mycosis fungoides plaque stage (age 46 to 85 years of age, four females and four males) are presented. Seven were treated with 13-cis-retinoic acid (Roaccutan®) 1 to 2 mg per kg body weight, and one with etretinate (Tigason®) 1 mg per kg body weight. After 4 to 8



weeks of treatment, when the mycosis fungoides lesions almost had disappeared, the skin again became reddish, dry, scaling and infiltrated with an appearance similar to eczema craquelé. Biopsy revealed a dermal scattered infiltrate consisting mainly of mature lymphocytes and histiocytes without any sign of atypia (Figs. 1-4). The dosage of retinoid was reduced to approximately half of the initial dose and the dry lesions disappeared completely within two to three weeks.

DISCUSSION

We think this skin reaction, consisting of increased desquamation, redness and infiltration localized to areas previously involved by mycosis fungoides, to be unique and strictly related to the retinoid treatment. Histologically there is a discrete and predominantly lymphocytic inflammation without the presence of atypical cells. The skin changes are quite unlike the more generalized exfoliative dermatitis seen in etretinate as well as in 13-cis-retinoic acid treated cases of psoriasis. Therefore we consider the described phenomenon as being confined to the particular constellation of retinoids and mycosis fungoides. The observation has so far only been made in plaque stage.

It is of importance to be aware of this apparently not uncommon skin reaction in order to avoid misinterpretation of the phenomenon as a progression of mycosis fungoides due to therapeutic failure. The reactive pattern of the lesions should be confirmed histologically. The non-malignant nature is also further confirmed by the rapid disappearance of the lesions after dosage reduction.

ACKNOWLEDGEMENTS

This work was supported by the Norwegian Cancer Society (Landforening mot Kreft) and the Edvard Welander Foundation. We wish to thank Med Dr Bertil Gustafsson for kindly preparing the microphotographs.

REFERENCES

1. Kessler JF, Meyskens Jr FL, Levine N, Lynch PJ, Jones SE. Treatment of cutaneous T-cell lymphoma (mycosis fungoides) with 13-cis-retinoic acid. *Lancet* 1983; i: 1345-1347.
2. Thomsen K, Molin L, Volden G, Lange Wantzin G. 13-cis-retinoic acid effective in mycosis fungoides. *Acta Derm Venereol (Stockh)* 1984; 64: 563-566.
3. Warrell Jr RP, Coonley CJ, Kempin SJ, Myskowski P, Safai B. Isotretinoin in cutaneous T-cell lymphoma. *Lancet* 1983; ii: 629.
4. Claudy AL, Rouchouse B, Boucheron S, Le Petit JC. Treatment of cutaneous lymphoma with etretinate. *Br J Dermatol* 1983; 109: 49-56.
5. Zachariae H, Grunnet E, Thestrup-Pedersen K, Molin L, Schmidt H, Starfeldt F, Thomsen K. Oral retinoid in combination with bleomycin, cyclophosphamide, prednisone and transfer factor in mycosis fungoides. *Acta Derm Venereol (Stockh)* 1982; 62: 162-164.

Fig. 1. Mycosis fungoides plaque lesions in a 62-year-old male patient.

Fig. 2. Histology of plaque lesions shown in Fig. 1: slight acanthosis, a dense lymphocytic-histiocytic dermal infiltrate with scattered large atypical hyperchromatic cells.

Fig. 3. Eczema craquelé-like dermatitis after 7 weeks of 13-cis-retinoic acid treatment.

Fig. 4. Histology of the lesions shown in Fig. 3: acanthosis and slight spongiosis with a dense infiltrate of mature lymphocytes and histiocytes without atypia.