

Macromelanosomes in X-Linked Ocular Albinism (XLOA)

TAKASHI YOSHIIKE,¹ MOTOMU MANABE,¹
MUTSUKO HAYAKAWA², and HIDEOKI OGAWA¹

¹*Department of Dermatology, and* ²*Department of Ophthalmology,
Juntendo University, Tokyo, Japan*

Yoshiike T, Manabe M, Hayakawa M, Ogawa H. Macromelanosomes in X-linked ocular albinism (XLOA). *Acta Derm Venereol (Stockh)* 1985; 65: 66-69.

A case of X-linked ocular albinism is reported. Characteristic Masson-Fontana positive and Dopa positive giant melanin granules were found in keratinocytes, melanocytes and upper dermis. Ultrastructurally the macromelanosome was composed of a dense core and a less dense surrounding mantle. (Received July 17, 1984.)

T. Yoshiike, Department of Dermatology, School of Medicine, Juntendo University, 2-1-1 Hongo, Bunkyo-ku, Tokyo 113, Japan.

The classical form of X-linked ocular albinism (XLOA) reveals symptoms and manifestations mainly limited to the eyes, such as reduced visual acuity, translucent irides, congenital nystagmus, photophobia, hypopigmentation of the fundi with absent foveal reflexes, and a high incidence of strabismus. Although XLOA frequently involves skin lesions such as hypopigmented macules or patches, this condition was until recently considered to be confined to the eyes. After the documentation of giant melanosomes (macromelanosomes) within the epidermis (1), skin biopsy has become a relatively easy procedure in order to define the diagnosis of XLOA. This is of the same importance as steroid sulfatase assay for dermatologists in the definitive diagnosis of X-linked ichthyosis.

Dermatologists rarely have a chance to see patients with XLOA due to the fact that the symptoms are usually limited to the eyes. Therefore, to our knowledge, this disorder has not yet been reported in journals of dermatology. However, dermatologists will certainly become more involved with this disorder due to probable consultations from ophthalmologists. We report here briefly on a typical case of XLOA.

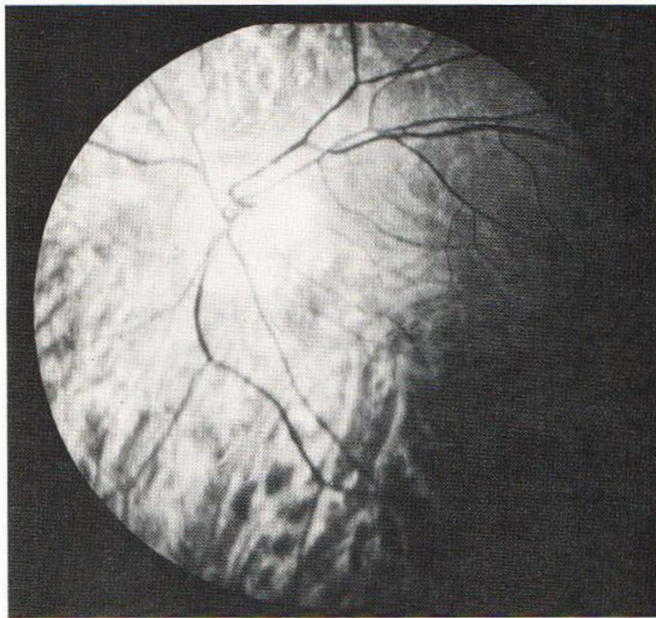


Fig. 1. Fundus photograph: hypopigmented fundus.

PATIENT AND METHOD

A 25-year-old male had squint and nystagmus since his early childhood. Visual acuity was reduced in both eyes, which had typical albinotic fundi (Fig. 1). A biopsy of his skin was examined by light and electron microscopy. HE stain, Masson-Fontana stain and Dopa reaction were performed for light microscopy.

RESULTS

Skin specimens showed Masson-Fontana stained and Dopa positive giant melanin granules up to 5 μm both in keratinocytes and melanocytes, and in the upper dermis (Fig. 2). Electron microscopy revealed that the giant melanin granules, which corresponded to those observed by light microscopy, had a variably dense core with a surrounding mantle consisting of slightly less dense material (Fig. 3).

DISCUSSION

Macromelanosomes have been demonstrated in the epidermis (1-5), retinal pigment epithelium and uveal tract (1) of patients with XLOA and their heterozygotes. It is now known that XLOA is a widespread melanosomal disorder, and detection of macromelanosomes by skin biopsy is essential for the diagnosis of XLOA. Therefore, it would be practical if dermatologists became familiar with this structural abnormality of melanosomes, even though complaints from patients with XLOA do not involve the skin.

Besides the skin and eyes of patients with XLOA, macromelanosomes occur most frequently in the café-au-lait spots of neurofibromatosis and in the pigmented macules of xeroderma pigmentosa. Although the significance of macromelanosomes in those lesions is still unclear, Jimbow et al. (6) suggested, through electron microscopic study, that macromelanosomes in the above genetic disorders were not formed solely by autophagic degradation of melanosomes as has been proposed in studies of the lentigo simplex (7), but by genetically coded aberrant melanogenesis.

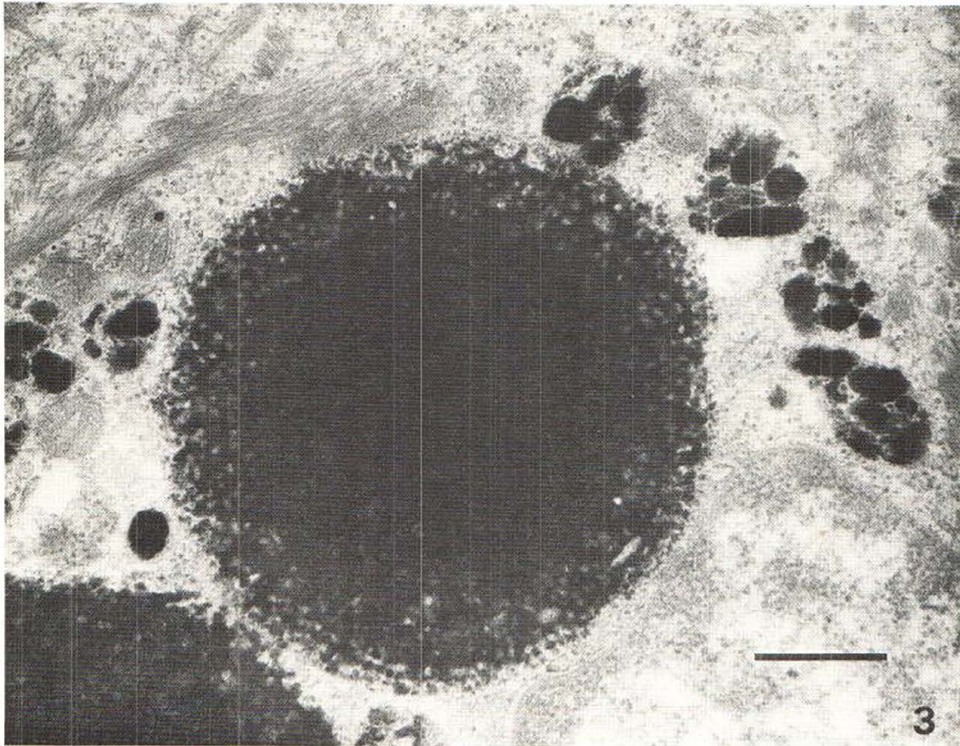
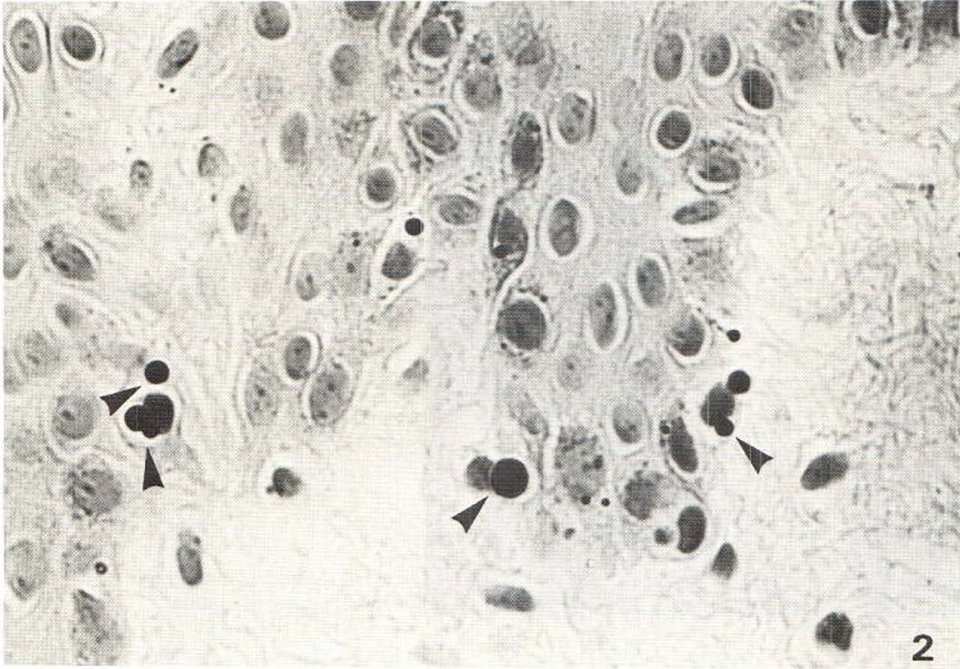


Fig. 2. Giant pigment granules of various sizes (arrows) in epidermis (original magnification $\times 200$).
Fig. 3. Large dense granules at the center and smaller, less dense granules at the periphery of macromelanosome (bar: $0.5 \mu\text{m}$).

REFERENCES

1. O'Donnel FE, Hambrick GW, Green WR, Iliff WJ, Stone DL. X-linked ocular albinism. An oculocutaneous macromelanosomal disorder. *Arch Ophthalmol* 1976; 94: 1883-1892.
2. O'Donnel FE, Green WR, Fleischman JA, Hambrick GW. X-linked ocular albinism in blacks. Ocular albinism cum pigmento. *Arch Ophthalmol* 1978; 96: 1189-1192.
3. Garner A, Jay BS. Macromelanosomes in X-linked ocular albinism. *Histopathology* 1980; 4: 243-254.
4. Cortin P, Tremblay M, Lemagne M. X-linked ocular albinism. Relative value of skin biopsy, iris transillumination and fundoscopy in identifying affected males and carriers. *Can J Ophthalmol* 1981; 16: 121-123.
5. Jaeger C, Jay B. X-linked ocular albinism. A family containing a manifesting heterozygote, and an affected male married to a female with autosomal recessive ocular albinism. *Hum Genet* 1981; 56: 299-304.
6. Jimbow K, Horikoshi T. The nature and significance of macromelanosomes in pigmented skin lesions. Their morphological characteristics, specificity for their occurrence, and possible mechanism for their formation. *Am J Dermatopathol* 1982; 4: 413-420.
7. Hirone T, Eryu Y. Ultrastructure of giant pigment granules in lentigo simplex. *Acta Derm Venereol (Stockh)* 1978; 58: 223-229.