

SHORT REPORTS

Increase of Mast Cells in the Alopecia Lesion of Mice

TSUKASA TANII,¹ TADASHI OKADA,² KAZUYOSHI FUKAI,¹
KOICHI NAKAGAWA¹ and TOSHIO HAMADA¹

¹Department of Dermatology and ²Department of Physiology,
Osaka City University Medical School, Osaka, Japan

Tanii T, Okada T, Fukai K, Nakagawa K, Hamada T. Increase of mast cells in the alopecia lesion of mice. *Acta Derm Venereol (Stockh)* 1985; 65: 64-66.

A histological investigation was made of the quantitative behavior of mast cells in bald areas on mice and in human alopecia areata. C57BL.W/W^y and +/+ mice with alopecia lesions were examined. In C57BL mice and +/+ mice, the number of dermal mast cells (per square mm) in the bald areas was greater than that in controls. The mean number of mast cells was slightly higher in human alopecia areata than in the controls. Since W/W^y mice lacking mast cells developed alopecia lesions, it seems that mast cells are not necessary for the onset of alopecia areata but could play some part in regrowth. *Key words: C57BL mouse; W/W^y mouse.* (Received August 24, 1984.)

T. Tanii, Department of Dermatology, Osaka City University Medical School, 1-5-7, Asahimachi, Abeno-ku, Osaka 545, Japan.

Histopathological studies of alopecia areata have disclosed an increase in the number of mast cells in connective tissue below the epidermis and in surrounding hair follicles (1). We studied the appearance of transient alopecia in C57BL mice (2), and discovered histologically an increase in the number of mast cells in the bald area. We also observed alopecia lesions in W/W^y mice lacking mast cells (3) and in +/+ mice. The aim of this investigation was to study changes in the numbers of mast cells in the bald area of mice and also in human alopecia areata.

MATERIALS AND METHODS

Mice with alopecia lesions were as follows: seven C57BL/10-H-2^d mice (C57BL mouse), two WBB6F₁ ((WB-W/+) \times (C57BL/6-W^y/+))F₁-W/W^y mice (W/W^y mouse) and three WBB6F₁ mice (+/+ mouse). In the mice with alopecia lesions (Fig. 1), biopsies were taken from the bald areas.

For control purposes, hairy skin was taken from the same mice.

In 6 patients with alopecia areata, biopsies were taken from the bald areas of the scalp. Control specimens were taken from marginal normal skin at the excision of seven sebaceous nevi of the scalp. The specimens were fixed in 10% formalin, mounted in paraffin wax, and cut at a thickness of 7 μ m.




Fig. 1. +/+ mouse with alopecia lesions.

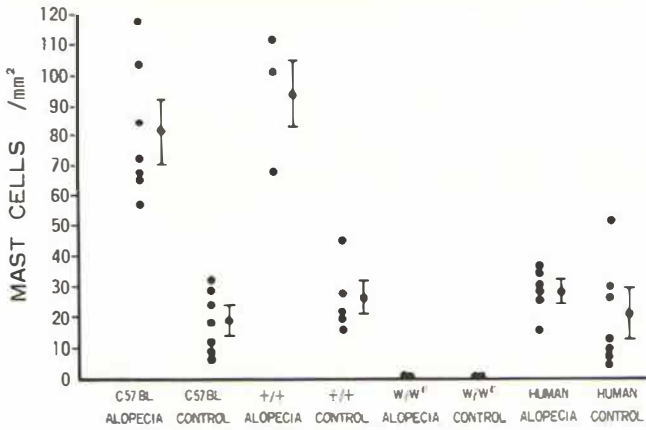


Fig. 2. Numbers of mast cells in the bald and hairy areas.

followed by staining with toluidine blue. Measurements were made of four sections of the dermis in each specimen. The counting of mast cells in each section was made on a specimen of dermis 2000 μm wide and 500 μm deep from just below the epidermis. The mean value was expressed as the number of mast cells per square mm of dermis.

RESULTS

The mast cell populations (mean value/mm²) in the dermis of the bald and hairy areas are shown in Fig. 2. Mast cells in the bald area were considerably more numerous than in controls in C57BL mice (bald area: 81.1 ± 22.3 , hairy area: 18.6 ± 10.1) and in +/+ mice (bald area: 94.7 ± 22.9 , hairy area: 26.0 ± 11.5). Mast cell numbers were increased throughout the dermis of the lesions (Fig. 3) and were numerous around the hair follicles. Mast cells were not present in W/W^v mice. The mean mast cell count was slightly higher in the lesions of human alopecia areata than in the controls, though the difference was not significant.

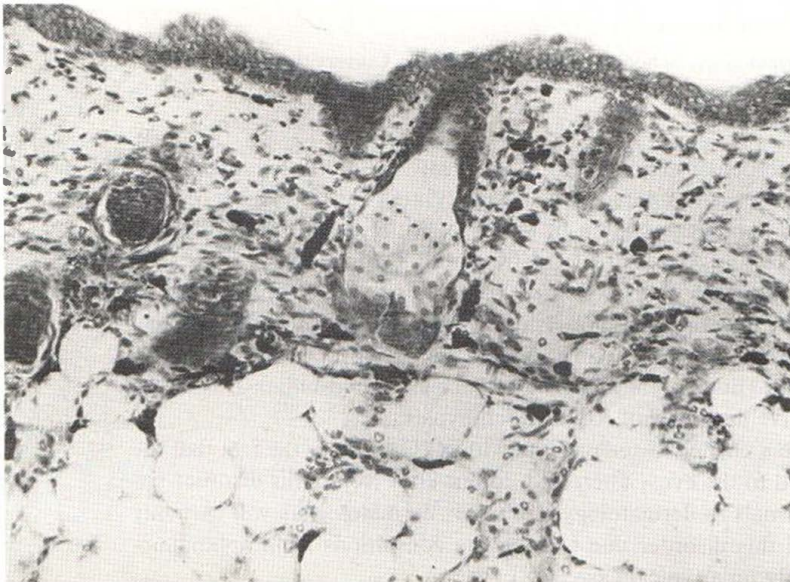

Fig. 3. Numerous mast cells are present in the dermis. Alopecia lesion on C57BL mouse. Toluidine blue staining, $\times 150$.

DISCUSSION

It has been reported that mast cell numbers are increased in human alopecia areata (1), and also in mice during a period of the telogen stage to the early anagen stage of the hair cycle (4). The present study showed that the mast cells increased markedly in the bald area of mice but not significantly in human alopecia areata. The reason might be that the 6 humans had alopecia of both short and long duration. Since W/W^v mice lacking mast cells developed alopecia lesions, it seems that mast cells are not involved in the onset of alopecia, but could be involved when the lesions regrow.

REFERENCES

1. Juhlin L. Reactions to infusion of a histamine liberator. *Arch Dermatol* 1963; 88: 771-778.
2. Staats J. Standardized nomenclature for inbred strains of mice. Third listing. *Cancer Res* 1964; 24: 147-168.
3. Kitamura Y, Go S, Hatanaka K. Decrease of mast cells in W/W^v mice and their increase by bone marrow transplantation. *Blood* 1978; 52: 447-452.
4. Moretti G, Reborà A, Giacometti C, Boido V, Rampini E, Cipriani C. The quantitative behavior of cutaneous histamine and mast cells in the hair cycles of rats. *J Invest Dermatol* 1966; 46: 231-239.