

## LETTER TO THE EDITOR

### Retinoid Dermatitis Mimicking "Eczéma craquelé"

The report by Molin et al. of an erythematous-squamous rash following treatment with oral retinoids (1) prompts us to report a similar case occurring in an 18-year-old male treated with 13-cis-retinoic acid for severe nodulocystic acne.

The treatment started with 13-cis-retinoic acid (1 mg/kg/day) on February 4, 1985, and gave good results. Six weeks later, he developed an erythematous-squamous rash of the dorsum of hands and forearms (Fig. 1), with illdefined borders. Biopsy showed a mild acanthosis, orthokeratosis, dilated capillaries in the papillary dermis, and a sparse perivascular mononuclear infiltrate. The dosage of the retinoid was reduced to 0.5 mg/kg/day and the rash cleared completely within 15 days.

We think that the psoriasiform rash affecting our patient was similar to what is termed "eczéma craquelé" by Molin et al. Histologic findings are non-specific. We have not found the parakeratosis which is demonstrated in their photographic material.

Our patient was on a single drug regimen and had no previous history of dermatitis. Thus, it is probable that this side effect was caused by 13-cis-retinoic acid, as a dosage-related phenomenon. Finally, it appears that this type of rash is not uniquely "a phenomenon confined to the particular constellation of retinoids and mycosis fungoides" as stated by the authors.

## REFERENCE

1. Molin L, Thomsen K, Wolden G, Lange Wantzin G. Retinoid dermatitis mimicking progression in mycosis fungoides: a report from the Scandinavian mycosis fungoides group. *Acta Derm Venereol* (Stockh) 1985; 65: 69-71.

*Received June 12, 1985*

Alain Taïeb and Jean Maleville, Centre Hospitalier Régional, Hôpital des Enfants, Department of Dermatology, 168, Cours de l'Argonne, F-33077 Bordeaux Cedex, France.

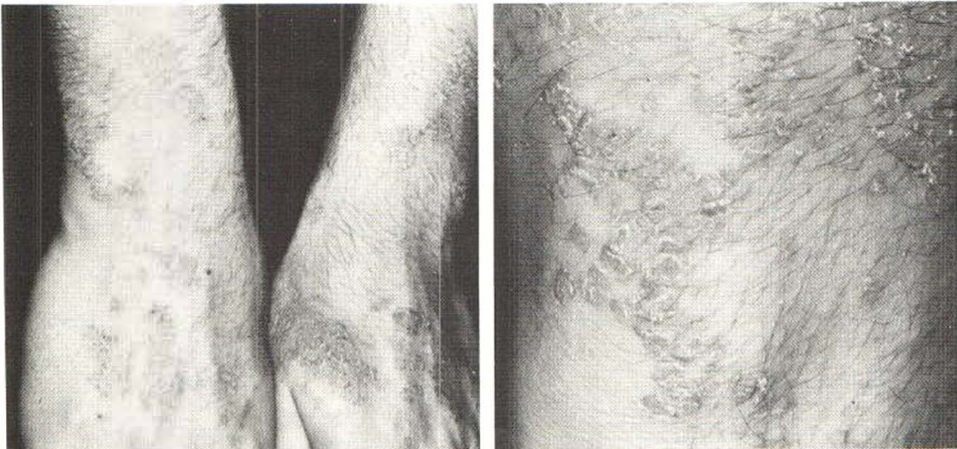


Fig. 1