

Hematologic Disease in Scleroderma Syndromes

JOHN A. DOYLE,¹ SUZANNE M. CONNOLLY²
and H. CLARK HOAGLAND²

¹Department of Dermatology and the ²Division of Hematology and Internal Medicine,
Mayo Clinic and Mayo Foundation, Rochester, Minnesota, USA

Doyle JA, Connolly SM, Hoagland HC. Hematologic disease in scleroderma syndromes. *Acta Derm Venereol (Stockh)* 1985; 65: 521-525.

Review of 4 430 patients with a diagnosis of scleroderma, morphea, or eosinophilic fasciitis has revealed 16 patients with one of a variety of serious hematologic diseases. Although it is not possible to comment on the exact relationship between the dermatologic disease and the hematologic disorder, in seven patients there appeared to be a close temporal relationship between the onset of the two conditions. The development of a serious hematologic disease, especially a lymphoproliferative process, may rarely be seen not only in patients with eosinophilic fasciitis but also in those with systemic or localized scleroderma. *Key words: scleroderma; morphea; eosinophilic fasciitis; leukemia.* (Received November 7, 1984.)

J. A. Doyle, Mayo Clinic, 200 First Street SW, Rochester, MN 55905, USA.

Eosinophilic fasciitis was first described by Shulman (1) in 1974. Although the exact nature of this condition remains unclear, it has been suggested that it may represent a special variant of scleroderma or morphea (localized scleroderma) (2). Recently, there have been reports of hematologic disease, especially aplastic anemia, developing in patients with eosinophilic fasciitis (see reference 3 for additional references).

To explore further a possible relationship between eosinophilic fasciitis and scleroderma and hematologic diseases, we have recently reviewed the hematologic diseases in patients seen at the Mayo Clinic in whom a diagnosis of either scleroderma or eosinophilic fasciitis was made.

MATERIALS AND METHODS

The diagnostic index file at the Mayo Clinic Department of Medical Records was reviewed for patients seen since 1950 who had a diagnosis of scleroderma, morphea, or eosinophilic fasciitis. This group of patients was then reviewed for an additional diagnosis of aplastic anemia, leukopenia, thrombocytopenia, multiple myeloma, leukemia, or lymphoma.

RESULTS

From January 1950 to July 1981, 4 430 patients were seen at the Mayo Clinic in whom a diagnosis of morphea, scleroderma, or eosinophilic fasciitis was made. Within this group were 16 patients who had a second diagnosis of aplastic anemia, leukopenia, thrombocytopenia, multiple myeloma, leukemia, or lymphoma. Characteristics of these patients and their diseases are summarized in Table I.

Systemic scleroderma was the most common type of scleroderma seen (10 patients) and was of the CREST variety in 7 patients; 3 other patients with systemic scleroderma had pulmonary involvement (Table I). Three patients had localized cutaneous variants of scleroderma—that is, facial hemiatrophy, linear morphea, and localized plaque morphea.

The three remaining patients had eosinophilic fasciitis. Two of these patients have been previously reported (4).

Table I. Hematologic disease in scleroderma syndromes

SS = systemic scleroderma; CREST = CREST syndrome; C = cutaneous calcinosis; R = Raynaud's phenomenon; E = esophageal dysmotility; S = sclerodactyly; T = telangiectasia

Patient no.	Age at onset of skin disease (yr)	Sex	Skin disease	Hematologic disease	Age at onset of hematologic disease (yr)	Follow-up
1	51	F	SS	Thrombocytopenia, Coombs-positive hemolytic anemia	56	Alive
2	20	F	SS	Hodgkin's disease	21	Alive
3	51	M	SS	Malignant lymphoma	52	Died, nonbacterial endocarditis, coronary embolism
4	34	F	RES	Thrombocytopenia	36	Died during repair of fracture of hip
5	72	F	RS	Lymphosarcoma	68	Died, progressive lymphoma
6	31	F	CRST	Hodgkin's disease	40	Died, progressive Hodgkin's disease
7	70	F	REST	Malignant lymphoma	79	Alive
8	54	F	REST	Multiple myeloma	58	Died, progressive myeloma
9	10	F	CREST	Chronic lymphocytic leukemia	67	Alive
10	22	F	CRST	Multiple myeloma	62	Died, advanced myeloma, necrotizing colitis, pulmonary embolus
11	26	F	Facial hemiatrophy	Hodgkin's disease	36	Died, brainstem compression by Hodgkin's disease
12	55	F	Linear morphea	Nodular lymphocytic lymphoma	48	Alive
13	44	F	Localized plaque morphea	Nodular lymphocytic lymphoma	32	Alive
14	55	M	Eosinophilic fasciitis	Chronic lymphocytic leukemia	56	Alive
15	69	F	Eosinophilic fasciitis	Pancytopenia ?Evolving myeloproliferative process	70	Alive
16	48	F	Eosinophilic fasciitis	Pancytopenia ?Smoldering myelomonocytic leukemia	51	Died, intracerebral hemorrhage

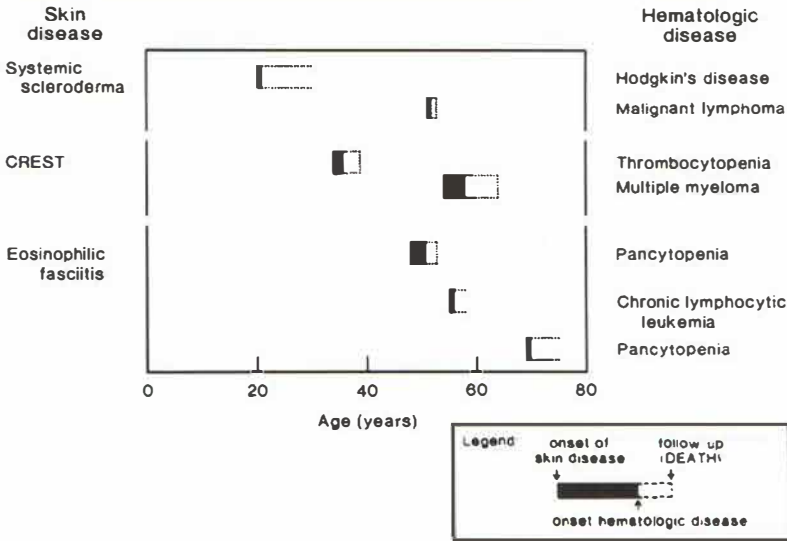


Fig. 1. Temporal association of scleroderma and hematologic disease.

The types of hematologic diseases seen included non-Hodgkin's lymphoma (five patients), Hodgkin's disease (three patients), thrombocytopenia (two patients, one of whom also had a Coombs-positive hemolytic anemia), multiple myeloma (two patients), and chronic lymphocytic leukemia (two patients). Two patients developed a pancytopenia. Hematologic evaluation including bone marrow biopsy did not permit a more definitive diagnosis but suggested the presence of smoldering myelomonocytic leukemia (one patient) and an evolving myeloproliferative disease (one patient) (4).

Follow-up of the patients showed that half (8 of 16) were still alive after a mean interval from the time of hematologic diagnosis of 10 years. Eight of the patients had died after a mean survival of 4 years. In six of these patients, death was attributed to the hematologic disease.

In the majority of patients (13 of 16), recognition of the sclerodermatous process preceded the diagnosis of the hematologic disease by an average of 11 years. In three patients (nos. 5, 12, and 13), the hematologic disease was diagnosed an average of 9 years before the scleroderma.

Although the exact onset of both the skin disease and the hematologic disease is difficult to define in a retrospective review, in seven patients (nos. 2-4, 8, and 14-16) there appeared to be a close temporal relationship between the onset of the two conditions (Fig. 1).

DISCUSSION

Eosinophilic fasciitis is a recently recognized condition that is said characteristically to have a benign course. However, patients with this condition have now been described in whom there have been changes in the hematopoietic system such as pancytopenia (*), anemia and thrombocytopenia (*), thrombocytopenia (*), hemolytic anemia (*), or lymphadenopathy (*). The aplastic anemia (*), anemia and thrombocytopenia (*), and anemia (*) may be antibody-mediated, but four patients have now been reported with

* See reference 3 for additional references.

evidence of a lymphoproliferative disorder (*). In four other patients, bone marrow biopsies were not diagnostic but did raise the possibility of a leukemic or pre-leukemic process in three (*, 4) and a myeloproliferative process in the fourth (4).

Hematologic changes in systemic scleroderma are usually limited to a mild anemia (5–7), but patients with systemic scleroderma have been reported to also have pancytopenia (8), marrow aplasia (9), hemolytic anemia (9–13), hemolytic anemia with thrombocytopenia (14), and hemolytic anemia with leukopenia (15). Antibodies to erythrocytes and platelets have been demonstrated (8–15), and two of the patients who were treated with systemic corticosteroids were noted to have had improvement in their scleroderma (8, 10) similar to what might be expected in eosinophilic fasciitis. One of the patients in the review by Frayha et al. (6) had scleroderma and lymphosarcoma, and another study has demonstrated that lymphoma and leukemia constitute one of the most common groups of malignancies seen in association with scleroderma (16). We are aware of only one previous report of hematologic disease (thrombocytopenia) in two patients with localized scleroderma (17).

This study was designed only to identify individual patients with both scleroderma and hematologic disease and not to calculate a frequency of hematologic disease in a specific population. Thus, it is not possible to ascertain if the coexistence of the cutaneous and hematologic diseases in our patients reflects anything more than a greater likelihood of individuals with multiple diseases being seen at a major medical referral center. In seven patients there was at least a close temporal relationship between the onset of the two conditions (Fig. 1), suggesting a possible common cause. However, the overall frequency of hematologic malignancy in this group of patients with scleroderma in fact is lower than the nationwide frequency (16).

In summary, review of our data suggests that serious hematologic diseases may be seen in patients with localized and systemic scleroderma as well as eosinophilic fasciitis. While the exact relationship of the two conditions has yet to be determined, their coexistence may have serious prognostic implications for the patient.

REFERENCES

1. Shulman LE. Diffuse fasciitis with hypergammaglobulinemia and eosinophilia: a new syndrome? (abstract). *J Rheumatol (Suppl)* 1974; 1: 46.
2. Doyle JA, Connolly SM, Winkelmann RK. Cutaneous and subcutaneous inflammatory sclerosis syndromes. *Arch Dermatol* 1982; 118: 886–890.
3. Doyle JA. Eosinophilic fasciitis: extra cutaneous manifestations and associations. *Cutis* 1984; 34: 259–261.
4. Michet CJ Jr, Doyle JA, Ginsburg WW. Eosinophilic fasciitis: report of 15 cases. *Mayo Clin Proc* 1981; 56: 27–34.
5. Tuffanelli DL, Winkelmann RK. Systemic scleroderma: a clinical study of 727 cases. *Arch Dermatol* 1961; 84: 350–371.
6. Frayha RA, Shulman LE, Stevens MB. Hematologic abnormalities in scleroderma: a study of 180 cases. *Acta Haematol (Basel)* 1980; 64: 25–30.
7. Leinwand I, Duryee AW, Richter MN. Scleroderma (based on a study of over 150 cases). *Ann Intern Med* 1954; 41: 1003–1041.
8. Carcassonne Y, Gastaut JA. Pancytopenia and scleroderma. *Br Med J* 1976; 1: 1446.
9. Westerman MP, Martinez RC, Medsger TA Jr, Totten RS, Rodnan GP. Anemia and scleroderma: frequency, causes, and marrow findings. *Arch Intern Med* 1968; 122: 39–42.
10. Fudenberg H, Wintrobe MM. Scleroderma with symptomatic hemolytic anemia: a case report. *Ann Intern Med* 1955; 43: 201–206.
11. Chaves FC, Rodrigo FG, Franco ML, Esteves J. Systemic sclerosis associated with auto-immune haemolytic anaemia. *Br J Dermatol* 1970; 82: 298–302.
12. Rosenthal DS, Sack B. Autoimmune hemolytic anemia in scleroderma. *JAMA* 1971; 216: 2011–2012.
13. Jacobsen BB, Pedersen M, Herting SE. Generalized scleroderma. *Acta Med Scand* 1972; 192: 107–111.

14. Ivey KJ, Hwang Y-F, Sheets RF. Scleroderma associated with thrombocytopenia and Coombs-positive hemolytic anemia. *Am J Med* 1971; 51: 815-817.
15. Steiner H, Haeger-Aronsen B, Nilsson G, Waldenström J. Porphyria cutanea tarda, Sklerodermie, Leukopenie und hämolytische Anämie: Klinische, biochemische und pathologisch-anatomische Analyse eines ungewöhnlichen Syndroms. *Schweiz Med Wochenschr* 1967; 97: 538-546.
16. Duncan SC, Winkelmann RK. Cancer and scleroderma. *Arch Dermatol* 1979; 115: 950-955.
17. Neucks SH, Moore TL, Lichtenstein JR, Baldassare AR, Weiss TD, Zuckner J. Localized scleroderma and idiopathic thrombocytopenia. *J Rheumatol* 1980; 7: 741-744.