

## Psoriasis Infiltrating Cell Immunophenotype: Changes Induced by PUVA or Corticosteroid Treatment in T-cell Subsets, Langerhans' Cells and Interdigitating Cells\*

J. D. BOS and S. R. KRIEG

*Departments of Dermatology and Pathology, University of Amsterdam, Academisch Medisch Centrum, Amsterdam, The Netherlands*

Bos JD, Krieg SR. Psoriasis infiltrating cell immunophenotype: changes induced by PUVA or corticosteroid treatment in T cell subsets, Langerhans' cells and interdigitating cells. *Acta Derm Venereol (Stockh) 1985; 65: 390-397.*

The effects of PUVA or corticosteroid treatment on the distribution pattern of immunocompetent cells in psoriasis symptomatic skin were investigated. A total of 29 biopsies, taken before and at regular intervals during treatment, were studied in a two-stage immunoperoxidase technique using monoclonal antibodies directed against T cells, their major subsets, interdigitating cells, and Langerhans' cells. T cell exocytosis was not affected by PUVA or corticosteroid treatment. Instead, both treatment regimens led to an initial increase in interbasally localized T8+ suppressor/cytotoxic T cells. Increased T4/T8 ratios within the subepidermal infiltrates were restored to normal except in one case, who did not respond to PUVA-treatment. Epidermal and dermal T6+ Langerhans' cells decreased to almost absent. RFD1+ interdigitating cells had the same tendency, except in the PUVA-non-responding patient. Treatment of psoriasis with PUVA or corticosteroids thus results in a normalization of an initial immune imbalance in infiltrating immunocompetent cells. A working hypothesis on psoriasis immunopathogenesis and its restoration by treatment is presented. (Received March 25, 1985.)

J. D. Bos M.D., Department of Dermatology, University of Amsterdam, Academisch Medisch Centrum, Meibergdreef 9, 1105 AZ Amsterdam, The Netherlands.

Psoriasis is a genetically determined chronic skin disease with an as yet enigmatic etiology. Several observations have suggested immune mechanisms to be centrally involved (reviews: 1, 2). Two possible immunogens have been suggested: non-histone proteins (3, 4) and stratum corneum antigens (5).

The subepidermal infiltrating cells in psoriasis skin lesions have been identified recently by the use of monoclonal antibodies (McAb) defining immunocompetent cell subsets (6-10). *In situ* ratios of helper/inducer versus cytotoxic/suppressor T-cells vary with the clinical type of psoriasis studied. Chronicity seems to be characterized by a relative decrease in the suppressor/cytotoxic T-cell subset as may be concluded from the results summarized in table I.

Other studies have indicated these T-cells to be activated, as a substantial part of them express HLA-DR (7, 11, 12). Intense staining of the subepidermal infiltrates with anti-HLA-DR could be partly explained by the presence of these activated T-cells, in combination with T6+ Langerhans' cells (LC's) and some sporadic monocytes. We suggested that the remainder of HLA-DR staining of these subepidermal infiltrates was due to the presence of dendritic antigen presenting cells with the immunophenotype of interdigitating (ID) cells (7); a hypothesis that could subsequently be confirmed (10). The presence of ID-

---

\* Presented in part at the Third International Symposium on the Treatment of Psoriasis & Psoriasis-Arthritis, Oct. 28-Nov. 2, 1984, Herzlia, Israel.

Table I. *In situ* T4/T8 ratios in subepidermal infiltrates of various clinical types of psoriasis

Clinical type of skin lesions	In situ T4/T8 ratio	Reference
Exacerbating guttate	Normal	7
Early guttate	Normal	8
Late guttate	Increased	8
Chronic plaque	Increased	8
Chronic plaque	Increased	The present study
Various types together	Increased	6

cells is interesting, as these cells were more abundant in psoriasis than in other immune/inflammatory skin diseases.

Immunocompetent cell abnormalities within the epidermis of psoriatic symptomatic skin have also been described. A decrease and abnormal clustering of LC's was demonstrated by ATP-ase staining (13), monoclonal anti-Ia (2) and anti-HLA-DR (7, 11) as well as anti-T6 (7, 14) antibodies. Next, exocytic infiltration of symptomatic epidermis by T-lymphocytes of both major subsets has been described (7, 15).

In this report, we wish to present the results of studies dealing with the effects of PUVA or corticosteroid treatment on the immunophenotype of the inflammatory cells present within psoriasis symptomatic skin. Profound changes in the distribution of T-cells and their major subsets as well as in antigen presenting cells were observed.

## PATIENTS

A total of 10 patients (29 biopsies) were selected for this study. All had relapsing plaque psoriasis. Patients were withheld treatment for a period of at least 2 weeks prior to their first (pre-treatment) biopsy. Patient number, type of treatment given and times of biopsies may all be found in Table II. In all cases but one, one biopsy could be obtained before, and two during treatment. All biopsies were taken from the edge of a plaque.

PUVA treatment consisted of either rectal (patient A) or oral (patients B-F) 8-methoxy-psoralen (8-MOP) in a dosage of 0.5 mg/kg/day, twice weekly, followed by UVA radiation in a dosage that was started at 0.5-2.0 Joules/m<sup>2</sup> (depending on skin type). UVA dosage was increased by 10-20% each time. The interval between psoralen intake and UVA irradiation was determined by pre-treatment monitoring of 8-MOP serum levels. Biopsies were always taken just before UVA-irradiation.

Table II. *Number, type of treatment, time of biopsies and pre-treatment T4/T8 ratios of 10, patients included in the study*

Patient	Type of treatment	Biopsies at days	T4/T8 ratio
A	PUVA	1, 4, 8	3
B	PUVA	1, 4, 8	5
C	PUVA	1, 14, 28	4
D	PUVA	1, 14, 28	5
E	PUVA	1, 14, 28	7
F	PUVA	1, 14, 28	10
G	Corticosteroids	1, 4, 15	5
H	Corticosteroids	1, 8, 15	3
I	Corticosteroids	1, 8, 15	3
J	Corticosteroids	1, 4,	4

Corticosteroid treatment consisted of local application of betamethasonedipropionate 0.5% with 5% salicylic acid in an ointment base (Diprosalic-R-). It was given either as pulse therapy in which patients were allowed to use it once daily under plastic occlusion for 4 consecutive days per week (patients G and H), or as a continuous twice-daily treatment schedule without occlusion (patients I and J).

All patients except one (F) responded favourably to their treatment. Patient F was later found to be non-responding and patient E was later found to be a slow-responder to PUVA-treatment.

## METHODS

A two-stage monoclonal antibody peroxidase conjugated rabbit-anti-mouse Ig staining system with 3-amino-9-ethyl-carbazol (AEC) as staining reagent was employed as the principal immunophenotyping procedure. Processing of tissue specimens, identification of cell types, immunoperoxidase technique and the controls used were essentially the same as described before (7). In short, fresh frozen (-196°C) skin specimens were sectioned (6 µ), fixed in fresh pure acetone, and incubated with the McAb for 60 min in a humidified atmosphere. Next, sections were incubated with peroxidase conjugated rabbit anti-mouse Ig for 30 min in a humidified atmosphere. Staining was achieved by incubation of sections in a freshly prepared acetate buffer solution (pH 4.9) containing AEC, dimethylformamide and hydrogen peroxide. The staining reaction was visually controlled and stopped by washing in acetate buffer. Slides were fixed in formaline (4%) and counter staining was achieved by passage through Mayer's haematoxylin for 2 min, to give a slight nuclear visualisation. Finally, sections were mounted with aquamount.

Enumeration of positively stained T-cells in the infiltrates was semiquantitative, similar to Synkowski & Provost (16), and they express the number of positively stained cells as a percentage of the total number of infiltrating mononuclear cells: - = no positive cell observed; ± = sporadic; + = 1-25%; ++ = 26-50%; +++ = 51-75%; ++++ = 76-99%; +++++ = 100%. In selected cases, a more precise number was estimated.

## MONOCLONAL ANTIBODIES (McAb)

McAb employed in this study were those against lymphocyte markers T1 (Leu-1), T3 (Leu-4), T4 (Leu-3a+b), T8 (Leu-2a); LC marker T6 (OKT-6); ID-cell marker RFD1; and finally anti-HLA-DR.

Leu-1 and Leu-4 stain 95% of thymocytes and over 95% of peripheral T-lymphocytes. Leu-3a+b stain 95% of thymocytes and T-helper/inducer cells, whereas Leu-2a reacts with 85-95% of thymocytes and with suppressor/cytotoxic T cells (references: 7). OKT-6 stains corticothymocytes and Langerhans' cells (17, 18) while RFD1 reacts with interdigitating cells and a small subpopulation of B-cells (19). Finally, anti-HLA-DR reacts with activated T cells, Langerhans' cells, interdigitating cells, B-lymphocytes, endothelial cells and monocytes/macrophages.

OKT-6 was obtained from Orthoclone. All other McAb were provided by Becton Dickinson Laboratories (Sunnyvale, Carlifornia), with the exception of RFD1 which was a generous gift from L. W. Poulter (London).

## RESULTS

### *T cells and T-cell subsets (Fig. 1a)*

(a) *Epidermal changes.* In this series of patients, untreated biopsies showed exocytosis of both major T-cell subsets in all cases. The majority of these exocytic T cells were of the T8+ suppressor/cytotoxic immunophenotype. They could be found scattered throughout the epidermis but some preferential localization was observed in between the basal cells, especially at the top of the elongated papillae.

A slight increase in interbasal exocytosis was found in both treatment groups during the initial stages of their therapy. Interbasal localization at sites of protruding papillary dermis became more marked, again especially of T8+ suppressor/cytotoxic T cells.

Clearing of exocytosis was observed in 2 of 6 PUVA-treated patients (A and B) and in 1 of 4 corticosteroid-treated patients (G).

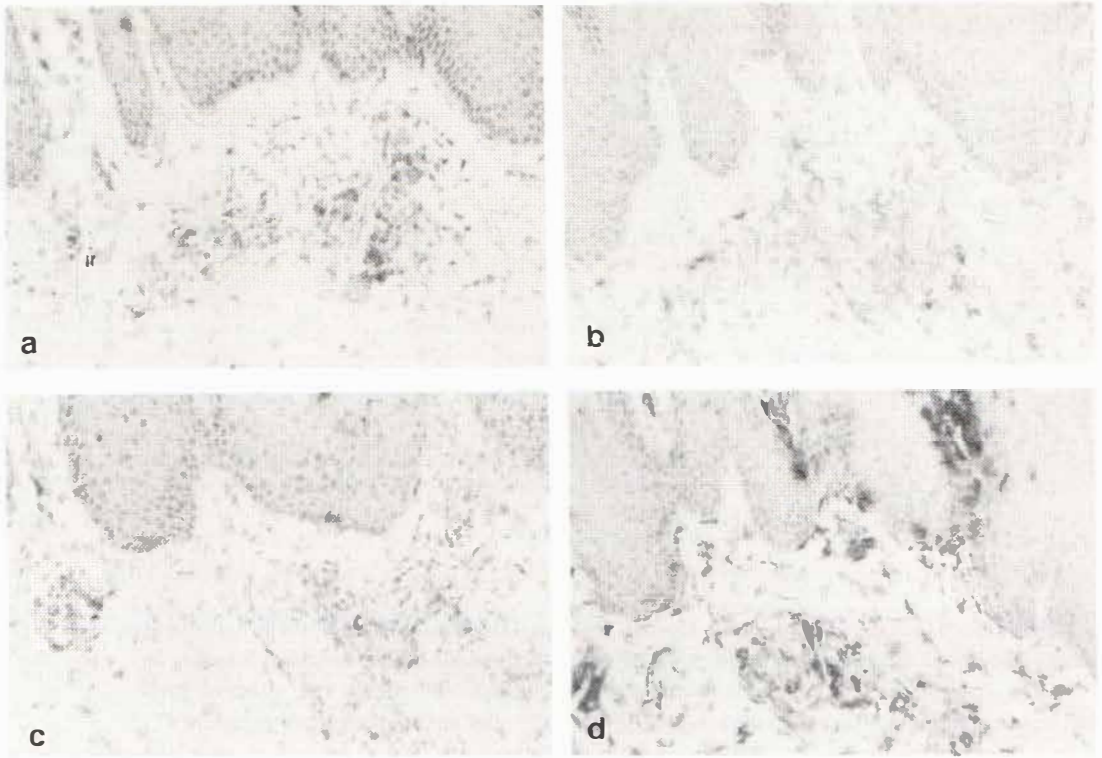


Fig. 1. Patient B: biopsy from the edge of a plaque of untreated symptomatic psoriasis. (a) T-lymphocytes as stained with anti-Leu-4 (T3) form the majority of infiltrating cells. (b) RFD1 positive interdigitating cells are presenting within the subepidermal infiltrate. (c) OKT6 (T6) positive Langerhans cells are also present. (d) HLA-DR staining, which by subtraction analysis, indicates part of T-cells to be activated. Note Fig. a-d are all serial sections from the same biopsy (X180).

(b) *Subepidermal changes.* T-cells were the major infiltrating type of cells in all untreated lesions studied (Fig. 1 a). Pre-treatment T4/T8 ratios in this series of relapsing plaque psoriasis patients were always increased (Table II) and ranged from 3 to 10 (median 4.5).

The corticosteroid-treated patients responded with an impressive diminishment in the number of subepidermal T-cells. As a consequence, in situ T4/T8 ratios could not be determined after two weeks of corticosteroid treatment due to a lack of cells to be counted.

In the PUVA-treated patients, such a decrease also occurred but much less substantial. As may be read from Fig. 2, PUVA treatment resulted in a decrease in in situ T4/T8 ratios, with a tendency towards normal in 5 of the 6 patients studied. Patient E, who was a slow responder, had a relatively high initial ratio, which did not become normal within the period of this study. Patient F, whose T4/T8 ratios did not decrease significantly, was later found to be PUVA-non-responding.

#### *Interdigitating cells*

RFD1+ cells were observed in all biopsies prior to treatment (Fig. 1 b). As we have described before (7), B-cells are extremely rare or absent within psoriasis symptomatic skin. Therefore, positive RFD1 staining was taken as evidence for the presence of interdigitating cells. The partly dendritic morphology of RFD1+ cells justified this as-

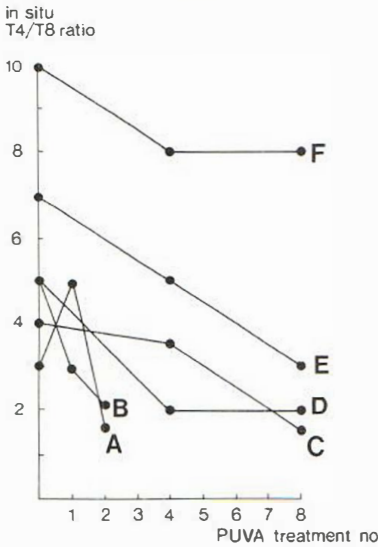


Fig. 2. Effects of PUVA treatment on in situ T4/T8 ratios in relapsing plaque psoriasis. A-F indicate patients.

sumption. In 1 out of 10 untreated lesions (patient H), the density of these cells was extremely low in comparison to the distribution pattern of all other untreated lesions. In untreated psoriasis, RFD1+ cells were arranged in clusters within the subepidermal infiltrates, making contact with well over 50% of the locally accumulated mononuclear (T) cells. They were especially apparent within the papillary layers extending into the acanthotic epidermis. At these sites, exocytosis of RFD1+ cells could be observed in 7 of 10 cases.

Upon treatment their presence within these dermal papillae diminished, together with a simultaneous decrease in their number in the dermal infiltrates. Large clusters of these cells disappeared, although in 2 out of 6 cases treated with PUVA, no such clear-cut decrease was observed. One of these 2 patients (F) did not respond to PUVA. In his case, virtually no change in RFD1+ cell distribution either epidermally or subepidermally, could be observed. In all other cases, RFD1+ cells were only observed sporadically and were diffuse within the remainders of the subepidermal infiltrates during treatment. These results were most apparent in the corticosteroid-treated group.

#### Langerhans' cells (Fig. 1c)

Epidermal LC's were found to be present in clusters in all pre-treatment biopsies. Their number diminished during both corticosteroid and PUVA treatment regimens, becoming rare in most cases.

A similar phenomenon was observed within the subepidermal infiltrates. Whereas LC's are normally present in these infiltrates of untreated symptomatic psoriasis skin, both corticosteroid- and PUVA therapy led to a decrease in these dermally localized LC's. In all cases except one (C) they became sporadical. These changes in epidermal and dermal LC distribution also occurred in patient F, who did not respond to PUVA-treatment.

## DISCUSSION

Dermatotropism or selective recruitment of the helper/inducer lymphocyte subset in situ has now been observed in a wide variety of, mostly chronic, immune/inflammatory skin

diseases. In lupus erythematosus, we previously noted a possible relation between duration of the skin lesion and an increase in the T4/T8 ratio (20). A similar increase in the in situ T4/T8 ratio with duration of clinical symptoms has been suggested in psoriasis (Table I). In lichen planus, spontaneous resolution seems to be accompanied by a relative increase in the percentage of the T8+ suppressor/cytotoxic subset, when early versus late lichen planus lesions were compared (21). A relative increase in the T8+ subset during treatment was also noted in the peribulbar infiltrates of alopecia areata (22).

In the present study, this tendency of increasing percentages of suppressor/cytotoxic lymphocytes, is now also described to occur during PUVA treatment of psoriasis. It seems justified to conclude that the chronicity of immune/inflammatory skin disorders is accompanied by a relative excess of T-lymphocytes with the helper/inducer immunophenotype. Functional studies of these infiltrating cells will have to be performed in order to make the definite conclusion that chronicity is the result of a lack of suppressor mechanisms. Spontaneous or treatment-induced clearing of lesions may then be the result of a restoration of suppressor mechanisms. In this respect, the preferential increase of T cells with the immunophenotype of suppressor/cytotoxic cells in between the basal cells during treatment may be important. Influx of T8+ cells has been described during spontaneous fading of psoriasis lesions (15).

Another interesting result of this study deals with the distribution patterns of antigen presenting cells with the immunophenotype of Langerhans' cells and interdigitating cells. In untreated lesions, RFD1+ cells were detected in substantial numbers both intra-epidermally as well as in the subepidermal infiltrates (Fig. 1 *b*). Treatment with corticosteroids or PUVA rapidly diminishes their numbers. Interdigitating cells are normally present in the T cell areas of the reticulo-endothelial system. Apart from in psoriasis, accumulations of these ID-cells have now been described in the inflamed synovial lining layers of rheumatoid arthritis (23), the granulomata of sarcoidosis (24) and leprosy (25) and in the lesional skin of atopic dermatitis (26) and pityriasis rosea (27). Juxtaposition with T cell concentrations was always found and it is suggested that this combination may be indicative for T cell mediated immune reactions.

A similar decrease in LC staining during treatment was also observed. Exact numbers of these dendritic cells are generally difficult to count within inflammatory infiltrates. Nevertheless, previous observations could be confirmed, for example that in untreated psoriasis, LC's are regularly present within almost each perivascular infiltrate (Fig. 1 *c*). Upon initial treatment procedures, LC's were only rarely present. Most T cell accumulations that were still present at that time were not accompanied by LC's nor ID-cells. Our PUVA-non-responding patient (F) was especially interesting, as in his case, LC numbers did decrease, whereas T cell subset and ID-cell distribution remained virtually unchanged. The effects of treatment on LC distribution patterns might thus not be related to clinical efficacy of the treatment given.

Taken together, our results indicate the normalization of several hallmarks of the psoriasis dermal immunophenotype prior to clinical remission. Langerhans' cell and interdigitating cell densities in the epidermis and superficial perivascular dermis diminished. Increased T4/T8 ratios in situ were restored to normal. These events possibly reflect the beneficial effect of treatment on a local immune imbalance. These results have led us to develop a working hypothesis on the pathogenesis of psoriasis and the effects of treatment: Treatment of psoriasis results in a decrease of RFD1+ interdigitating cells. This decrease is either the result of, or results in, an increase of T8+ suppressor/cytotoxic T cells and this in turn produces a normalisation of initially increased T4/T8 ratios. In this way a T cell mediated response towards epidermal immunogens is halted, so bringing epidermal hyperproliferation to an end.

## ACKNOWLEDGEMENTS

We wish to thank Dr L. W. Poulter (London) for providing monoclonal antibody RFD1. We also wish to express our gratitude to the Chanfleury van Ijsselstein Foundation for providing financial support.

## REFERENCES

1. Cormane RH. Immunopathology of psoriasis. *Arch Dermatol Res* 1981; 270: 201–215.
2. Krueger GG. Psoriasis: current concepts of its etiology and pathogenesis. In: Dobson RL, Thiers BH, eds. *The year book of dermatology*. Chicago, London: Year Book Medical Publishers, 1981: 13–70.
3. Reimer G, Leonhardi G, Schwulera U.. DNA-binding proteins of psoriatic scales. III. Biochemical characterisation as non-histone proteins. *Arch Dermatol Res* 1978; 262: 185–189.
4. Ashgar SS, Ali-Briggs EF, Reimer G, Cormane RH. Interaction of psoriasis scale non-histone proteins with the antibodies eluted from lymphocytes of psoriasis patients reactive with basal cell nuclei. *Acta Derm Venereol (Stockh)* 1984; Suppl 113: 50–54.
5. Beutner EH, Binder WL, Jablonska S, Kumar V. Immunofluorescence findings on stratum corneum antibodies, antigens and their reaction in vitro and in vivo as related to repair and psoriasis. In: Beutner EH, ed. *Autoimmunity in psoriasis*. Boca Raton, Florida: CRC Press, 1982: 51–79.
6. Bjerke JR. Subpopulations of mononuclear cells in lesions of psoriasis, lichen planus and discoid lupus erythematosus studied using monoclonal antibodies. *Acta Derm Venereol (Stockh)* 1982; 62: 477–482.
7. Bos JD, Hulsebosch HJ, Krieg SR, Bakker PM, Cormane RH. Immunocompetent cells in psoriasis: in situ immunophenotyping by monoclonal antibodies. *Arch Dermatol Res* 1983; 275: 181–189.
8. Baker BS, Swain AF, Valdimarsson H, Fry L. T cell subpopulations in the blood and skin of patients with psoriasis. *Br J Dermatol* 1984; 110: 37–44.
9. Kaudewitz P, Braun-Falco O, Kind P, Galosi A, Rieber P, Riethmuller G. Distribution of T cell subsets as defined by monoclonal antibodies in skin lesions of psoriasis vulgaris. *Arch Dermatol Res* 1984; 276: 33–35.
10. Poulter LW, Russell Jones R, Hobbs S. The significance of antigen presenting cells in psoriasis vulgaris. In: MacDonald DM, ed. *Immunodermatology*. Kent: Butterworth, 1984: 185–188.
11. Morhenn VB, Abel EA, Mahrle G. Expression of HLA-DR antigen in skin from patients with psoriasis. *J Invest Dermatol* 1982; 78: 165–168.
12. Bjerke JR, Matre R. Demonstration of Ia-like antigens on T lymphocytes in lesions of psoriasis, lichen planus and discoid lupus erythematosus. *Acta Derm Venereol (Stockh)* 1983; 63: 103–107.
13. Lisi P. Investigation on Langerhans' cells in pathological human epidermis. *Acta Derm Venereol (Stockh)* 1973; 53: 425–428.
14. Haftek M, Faure M, Schmitt D, Thivolet J. Effect of aromatic retinoid treatment on epidermal Langerhans cells in psoriasis. A quantitative study. *J Invest Dermatol* 1982; 78: 327 A.
15. Baker BS, Swain AF, Fry L, Valdimarsson H. Epidermal T lymphocytes and HLA-DR expression in psoriasis. *Br J Dermatol* 1984; 110: 555–564.
16. Synkowski DR, Provost TT. Enumeration of T-cell subpopulations in lupus erythematosus lesions using monoclonal antibodies. *Clin Res* 1982; 30, 611 A.
17. Fithian E, Kung P, Goldstein G, Rubinfeld M, Fenogeio C, Edelson R. Reactivity of Langerhans cells with hybridoma antibody. *Proc Natl Acad Sci USA* 1981; 78: 2541–2544.
18. Murphy GF. Monoclonal anti-T6 antibody and Langerhans cells. *Br J Dermatol* 1982; 107: 487–489.
19. Poulter LW. Antigen presenting cells in situ: their identification and involvement in immunopathology. *Clin Exp Immunol* 1983; 53: 513–520.
20. Bos JD, Emsbroek JA, Krieg SR. T cell subsets and Langerhans cells in cutaneous lupus erythematosus. In: MacDonald DM ed. *Immunodermatology*. Kent: Buterworths, 1984: 261–266.
21. Panfilis G de, Manara G, Ferrari C, Manfredi G, Allegra F. Imbalance in phenotypic expression of T cell subpopulations during different evolutionary stages of lichen planus lesions. *Acta Derm Venereol (Stockh)* 1983; 63: 369–375.
22. Wiesner-Menzel L, Happle R. Contact allergens change the composition of the peribulbar infiltrate in alopecia areata. *Arch Dermatol Res* 1984; 276: 257–258.
23. Poulter LW, Duke O, Hobbs S, Janossy G, Panayi G, Seymour G. The involvement of interdigitating (antigen presenting) cells in the pathogenesis of rheumatoid arthritis. *Clin Exp Immunol* 1983; 51: 247–251.

24. Mishra BB, Poulter LW, Janossy G, Geraint James D. The distribution of lymphoid and macrophage like cell subsets of sarcoid and Kveim granulomata: possible mechanism of negative PPD reaction in sarcoidosis. *Clin Exp Immunol* 1983; 54: 705–715.
25. Poulter LW, Collings LA, Tung KS, Waters MFR. Parasitism of antigen presenting cells in hyperbacillary leprosy. *Clin Exp Immunol* 1984; 55: 611–617.
26. Sillevs Smitt JH, Bos JD, Hulsebosch HJ, Krieg SR. Antigen presenting cells and T cell subsets in atopic dermatitis: in situ imbalance in immunophenotype. Submitted for publication, 1985.
27. Bos JD, Huisman PM, Krieg SR, Faber WR. Pityriasis rosea (Gibert): imbalance in antigen presenting cells in situ. *Acta Derm Venereol (Stockh)* 1985; 65: 132–137.