

## Candidiasis: The Isomorphic Response

JOSEPH A. WITKOWSKI<sup>1</sup> and LAWRENCE CHARLES PARISH<sup>2</sup>

<sup>1</sup>Department of Dermatology, University of Pennsylvania School of Medicine, Philadelphia, and <sup>2</sup>Department of Dermatology, Jefferson Medical College, The Thomas Jefferson University, Philadelphia, Pennsylvania, USA

Witkowski JA, Parish LC. Candidiasis: the isomorphic response. *Acta Derm Venereol* (Stockh) 1985; 65: 355-358.

Two uncontrolled insulin dependent diabetic patients had *Candida albicans* infection with the unique manifestation of erythematous scaling papulopustules at the sites of excoriation. In one patient, the clinical presentation suggested herpes zoster. Recognition of this picture and the contributing factors, i.e. *Candida* infected finger nails and elevated blood sugar will permit early use of appropriate antifungal therapy. *Key words: Insulin dependent diabetes; Onychomycosis; Excoriations.* (Received October 8, 1984.)

J. A. Witkowski, M.D., 3501 Ryan Ave., Philadelphia, PA 19136. USA.

*Candida albicans* has a predisposition for infecting skin of patients with diabetes mellitus. The usual varieties of *Candida* infection are thrush, angular cheilitis, vaginitis, balanitis,

paronychia and intertrigo involving the axillary, submammary, inguinal, intergluteal, and interdigital areas. We describe for the first time two patients with diabetes mellitus who developed cutaneous candidiasis on skin sites excoriated with onychomycosis nails producing an isomorphic response.

## CASE REPORTS

Q.L., a 72-year-old obese white man was admitted to the hospital because of uncontrolled diabetes mellitus, arteriosclerotic cardiovascular disease, anemia, urinary tract infection, and diabetic retinopathy. He was treated with papaverine hydrochloride 150 mg BID, digoxin 0.125 mg OD, thiamine 50 mg TID, trimethoprim sulfamethoxazole 160/800 BID, NPH insulin 26 units, regular insulin, and 2 units of packed red blood cells. Pertinent admission laboratory tests included a random blood sugar of 349 mg/dl, Hgb 7.9, WBC 8,500, Polys 55, Stab 1, Lymph 27, Monos 16, serum iron 265, T.I.B.C. 302, saturation 88%, reticulocyte count 0.8%.

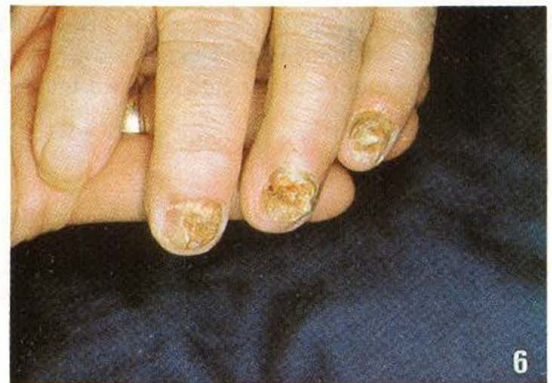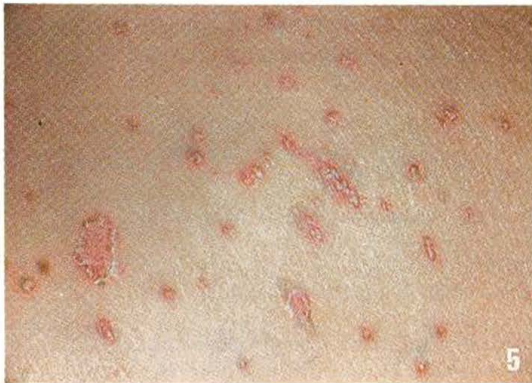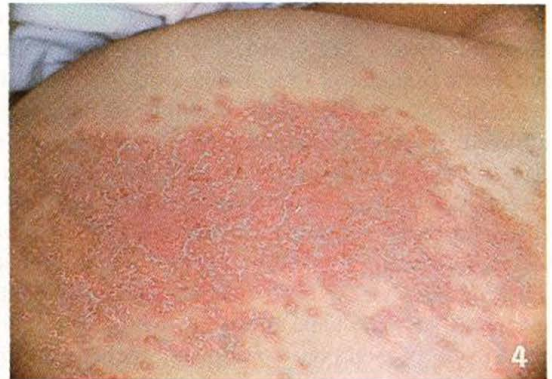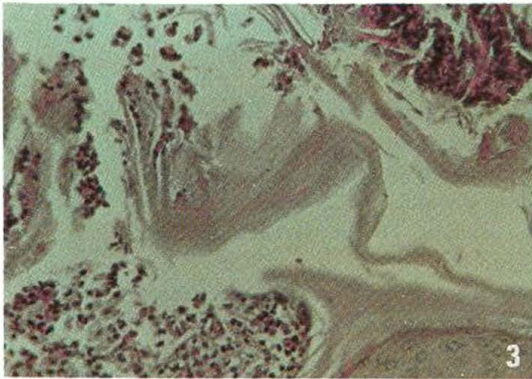
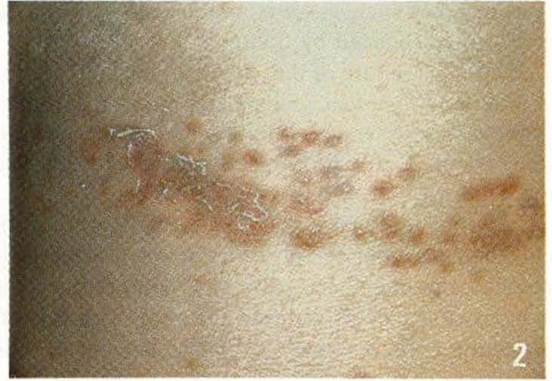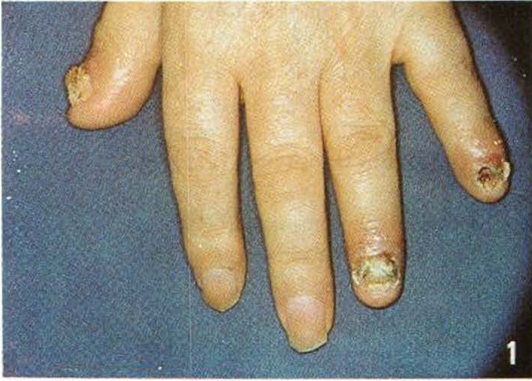On the fourth hospital day, he was seen because of a chronic nail infection. Examination revealed erythema and edema of the lateral and posterior nail folds of all the fingers on the right hand, the thumb, 4th and 5th fingers of the left hand, and all the toes of the left foot. The nail beds of several of the affected fingers and toes were yellowish and hyperkeratotic, the other nails were thinned and grooved (Fig. 1). Microscopic examination of KOH wet mounts of material obtained from beneath the posterior nail folds and the nail beds showed numerous pseudo hyphae and budding cells. Culture in selective mycologic agar grew *Candida albicans*. On the tenth hospital day, he developed a linear band of erythematous papules, scaling and pustules having a dermatomal distribution corresponding to T 12 on the right side of the back (Fig. 2). Similar lesions occurring in scratch marks were present on the sacrum and buttocks. Microscopic examination of KOH wet mounts of scrapings from the lesions showed pseudo hyphae and budding cells. Culture on selective mycologic agar grew *Candida albicans*. A biopsy of the skin stained with H and E showed a subcorneal pustule and a sparse predominantly lymphocytic perivascular infiltrate in the upper dermis. PAS stain revealed some septate hyphae in the stratum corneum overlying the pustule (Fig. 3). Skin test with *Candida albicans* extract 1:100 produced a delayed papular response. The patient was placed on ketoconazole (Nizoral, Janssen) 200 mg OD and clotrimazole (Lotrimin, Schering) cream 1%. The nails were debrided. The eruption gradually cleared, and the paronychial inflammation resolved.

E.S., an 82-year-old obese white woman, was admitted to the hospital because of uncontrolled diabetes mellitus, generalized pruritus, arteriosclerotic cardiovascular disease, conjunctivitis, diabetes retinopathy, and right hemipareses. She was treated with furosemide 40 mg OD, isosorbide dinitrate 5 mg. QID, levothyroxine sodium 0.1 mg OD, amoxapine 25 mg. TID, NPH insulin 40 units OD, regular insulin, and hydroxyzine hydrochloride 10 mg prn for itching. Pertinent admission laboratory tests included a random blood glucose of 353 mg/dl, Hgb 13.7, Hct 40%, WBC 6.1, polys 65%, stabs 6%, lymph 24%, eosin 1%, monos 1%. Culture of the conjunctivae revealed *S. epidermidis*.

Examination of the skin showed a fairly well defined patch of erythema and scaling studded with pustules covering most of the left hip and thigh (Fig. 4). Erythematous papules and pustules occurring discretely and in linear streaks were present on the surrounding skin (Fig. 5). There was erythema and edema of the posterior nail folds of the 3rd, 4th, and 5th fingers of the left hand. The nail beds on these fingers were yellowish and hyperkeratotic (Fig. 6). Fungal elements were found in microscopic examination of KOH wet mounts of the nail beds and skin scrapings and on a skin specimen stained with PAS. Culture of specimens from the nail beds and skin on selective mycologic agar grew *Candida albicans*. Intra-dermal skin test with *Candida albicans* extract 1:100 was positive for 48 hours. The cutaneous eruption and the periungual inflammation cleared on ketoconazol (Nizoral, Janssen) 200 mg OD and clotrimazole (Lotrimin, Schering) cream 1%. The nail beds were debrided.

## DISCUSSION

The isomorphic response, often called the Koebner phenomenon after the famous German dermatologist, denotes the induction by physical trauma of lesions of the very same form that are characteristic of the disease (1). This is most often seen in psoriasis, lichen planus, lichen nitidus, and nummular dermatitis. Conditions less commonly associated with the Koebner phenomenon are vitiligo, vasculitis, (2) and eruptive xanthoma (3). Some infec-



*Fig. 1.* Erythema and edema of the posterior and lateral nail folds with yellowish hyperkeratotic material covering the nail beds on the thumb, 4th and 5th fingers of the left hand.

*Fig. 2.* A zoster-like band of erythematous scaling, papules and pustules.

*Fig. 3.* Septate hyphae in the stratum corneum overlying a pustule.  $\times 400$  PAS.

*Fig. 4.* Fairly well defined patch of erythema and scaling studded with pustules.

*Fig. 5.* Erythematous papules and pustules occurring indiscretely and in linear streaks.

*Fig. 6.* Erythema and edema of the nail folds with yellowish hyperkeratotic material covering the nail beds of the 3rd, 4th and 5th fingers of the left hand.

tious diseases such as warts, molluscum contagiosum, and infected eczematoid dermatitis may also be induced by trauma.

The fungal nature of these patients' lesions was confirmed by microscopic examination, culture, and histological examination of the affected skin. The self induced nature of the process was underscored by the linear arrangement of the lesions and by the fact that in one patient (E. S.) all of the cutaneous changes were confined to the skin within reach of the hand with onychomycotic nails.

The constitutional susceptibility of diabetic patients to candidiasis is gradually being elucidated. Among the possible factors are anomalies of inflammation and immunity. The granulocytes of diabetic patients show decreased engulfment and decreased killing (4). The number of T-cells is reduced (5) and T-cell transformation when measured by phytohemagglutinin is decreased (5, 6). These defects are often mild in well controlled diabetes but become more pronounced when the diabetes is poorly compensated.

*Candida albicans* is rarely a member of the normal resident flora of the skin except when the fingers and intertriginous areas are cultured (7). The source of organisms in cutaneous candidiasis appears to be the gastrointestinal tract. In most persons, the natural resistance to infection with *Candida* is high; mere contamination of the skin is not sufficient to produce disease. In the clinical setting, certain sites appear vulnerable to disease. Those most often affected are intertriginous and thin skinned areas. The local susceptibility is related to the presence of relative occlusion which results in accumulation of moisture and subsequent hydration of the stratum corneum. The importance of these two factors is emphasized by experiments on human skin (8).

The apparent ease with which candidiasis could be produced in these two patients suggests that some local cutaneous factor was operative. Although the incidence of yeast on the skin of well controlled insulin dependent diabetic patients is no greater than that found on healthy adults (9), diabetics have an increased store of glucose in the dermis and the level of cutaneous free glucose is higher than in the general population. This is especially true when the blood glucose is over 180 mg/dl (10). Perhaps the increased levels of blood glucose in these patients provided the measure of difference.

## REFERENCES

1. Crissey JT, Parish LC. The dermatology and syphilology of the Nineteenth Century. New York: Praeger Scientific, 1981: 367-9.
2. Miller, RAW. The Koebner phenomenon. *Int J Dermatol* 1982; 21: 192-7.
3. Goldstein GD. The Koebner response with eruptive xanthomas. *J Am Acad Dermatol* 1984; 10: 1064.
4. Nolan CM, Beaty HN, Bagdade JD. Further characterization of the impaired bactericidal function of granulocytes in patients with poorly controlled diabetes. *Diabetes* 1978; 27: 889-94.
5. Eliashiv A, Olumide F, Norton L et al. Depression of cell mediated immunity in diabetics. *Arch Surg* 1978; 113: 1180-3.
6. MacCuish AC, Urbaniak SJ, Campbell CJ et al. Phytohemagglutinin transformation and circulating lymphocyte subpopulations in insulin dependent diabetics. *Diabetes* 1974; 23: 708-12.
7. Clayton YM, Nobel WC. Observations on the epidemiology of *Candida albicans*. *J Clin Pathol* 1966; 19: 76-8.
8. Rebora A, Marples R, Kligman AM. Experimental infections with *Candida albicans*. *Arch Dermatol* 1973; 108: 69-73.
9. Sommerville DA, Lancaster-Smith M. The aerobic cutaneous microflora of diabetic subjects. *Br J Dermatol* 1973; 89: 395-400.
10. Noble WC, Noble, Sommerville DA. Microbiology in human skin. *Major Probl Dermatol* 1981; 2: 370.