

# Spun Glass Hair: Two Cases Investigated with SEM and TEM

BO FORSLIND,<sup>1</sup> KRISTIAN THOMSEN,<sup>2</sup> and BERTIL ANDERSSON<sup>3</sup>

<sup>1</sup>*Department of Medical Biophysics, Experimental Dermatology Research Group, Karolinska Institutet, Stockholm, Sweden,* <sup>2</sup>*Department of Dermatology, Finsen Institute, Rigshospitalet, Copenhagen, Denmark,* and <sup>3</sup>*Department of Dermatology, Danderyd Hospital, Danderyd, Sweden*

Forslind B, Thomsen K, Andersson B. Spun glass hair: Two cases investigated with SEM and TEM. *Acta Derm Venereol (Stockh)* 1985; 65: 348–352.

Two cases of spun glass hair have been investigated with SEM and TEM. The SEM studies confirm previous findings by other authors. The TEM investigations reveal a completely normal cross section appearance. These findings stress the need for investigation of the time sequence of the keratinization process of the different layers of the inner root sheath. *Key words: Spun glass hair; SEM & TEM investigations.* (Received October 29, 1984.)

B. Forslind, Department of Medical Biophysics, Solnavägen 1, Box 60400, 104 01 Stockholm, Sweden.

Spun glass hair (synonyms: uncombable hair, *pili trianguli et canaliculi*) is a rare condition with apparently no manifestations from other tissues of ectodermal origin. It has not been associated with any mental deficiencies either. The afflicted subjects have very blond, almost depigmented hair (3, 4, 7, 8). The "glass wool" appearance of the hair is due to light reflexion on comparative flat segments of the hair fibre surface (Fig. 1). It has been suggested that the condition, the genetics of which is obscure, is caused by a prematurely occurring keratinization of the inner root sheath (6, 7). We here report on two young individuals which conform to previous reports in the literature.

## CASE REPORTS

*Case 1.* A 3-year-old girl, healthy and without skin disease. Her hair has always had a striking appearance, as it has been blond, shining, and completely unmanageable. With increasing length the hair now stands as an aura around the head (Fig. 1 a). Nails and teeth are normal, as are other organs of ectodermal origin. The mental status of the patient is normal. No skin disorders are found in the family. The parent and siblings have normal hair.

*Case 2.* A girl, age 4. Hair eruption took place at 18 months of age. Initially apparently depigmented and kinky it began to be somewhat pigmented at the age of 3. With increasing length of the hair it has become more unmanageable and uncombable. Cutting the hair short has accentuated the problems. There are no disorders related to hair and nail or any defects in the dentition. Siblings have normal hair and there are no skin disorders in the family (Fig. 1 b).

## MATERIAL AND METHODS

Small tufts of hair fibres were collected from the peripheral hair of the patients. Single hair strands were cut into 5 mm segments and mounted on SEM specimen stubs by means of double sided tape




Fig. 1. (a) Case I: Note the very blond appearance of the hair and its unmanageable character. Eyebrows and ciliae of eye-lids are normal. (b) Case II: Note same characteristics as in case I.

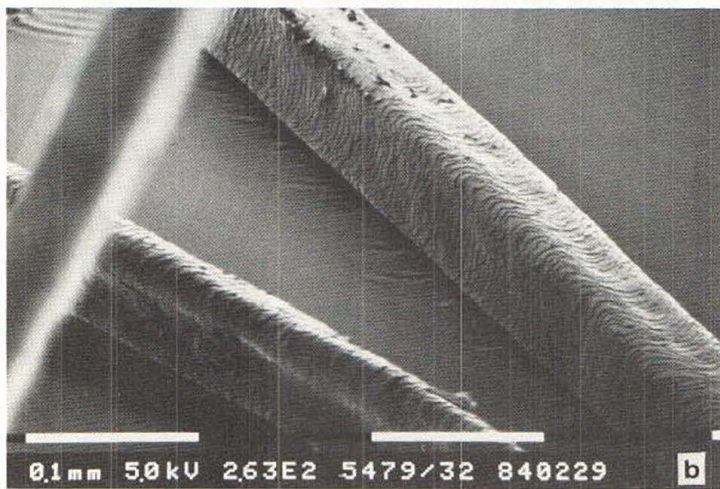
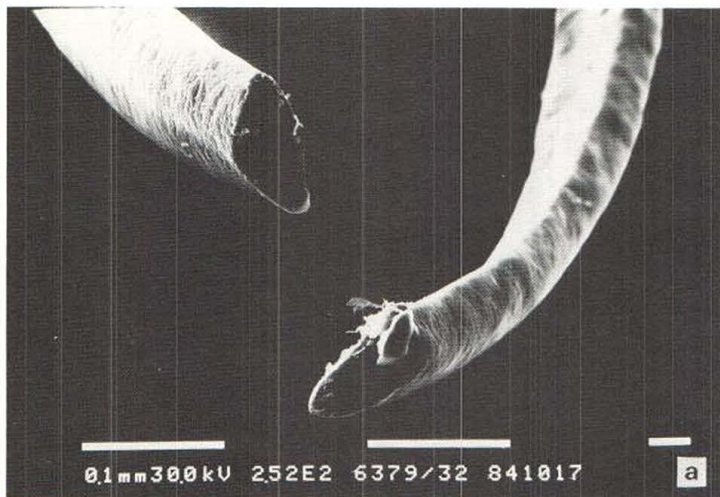and without any prior treatment. Subsequently the specimens were sputter-coated with gold to increase conductivity. Without prior fixation or staining a few hair strands were processed through ethanol gradients starting from 90% and subsequently introduced into an epon/propylene oxide mixture (1:1) for 24 h and subsequently embedded in epon. Sectioning was performed on an LKB Ultratome III fitted with a diamond knife and section were collected on carbon coated grids, and stained with saturated uranyl acetate (Forslind B, and Andersson M, unpublished observations). Scanning electron microscopy (SEM) was performed on a Philips SEM 505 at 5 kV at primary magnification of 40–700 $\times$ . Transmission electron microscopy (TEM) was performed on a Philips EM 301 G at 60 or 80 kV at primary magnifications of 200–22000 $\times$ .

## RESULTS

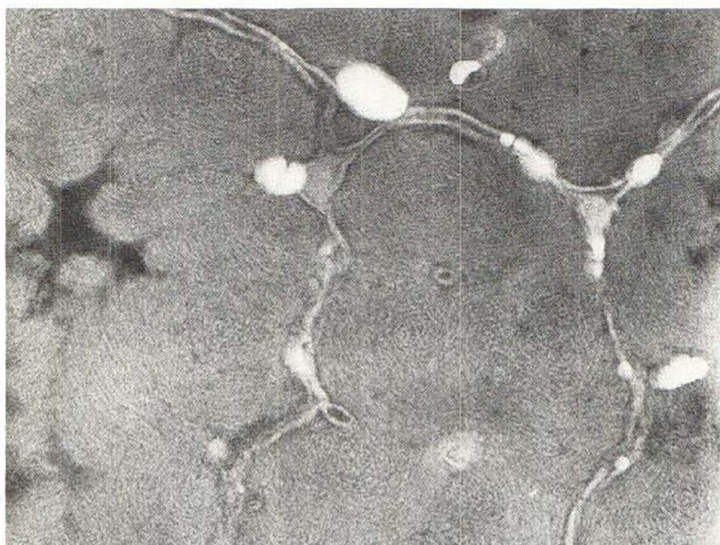
The results of the SEM investigation of the hair fibres conform to the findings of previous studies (3–8). Triangular or kidney shape of the hair cross section was found (Fig. 2) and the scales at the bottom of longitudinal grooves showed less evidence of mechanical wear compared to the cuticular edges at the convex surfaces. There were no other surface characteristics which single out the hair fibres of this condition. The transmission electron micrographs of unfixed, directly embedded hair fibres stained after sectioning reveal a normal ultrastructural morphology of a mature cortical cross section. Thus the characteristic "finger print whorl pattern" is a conspicuous finding (Fig. 3). Intercellular junctions between cortex cells and cuticular cells do not diverge from findings in normal, healthy hair fibres.

## DISCUSSION

The genetics of this congenital condition is obscure. The abnormality has been found in siblings without any other appearance in the remaining family (5, 6). So far afflicted individuals have been reported to be depigmented or very blond. No other accompanying



*Fig. 2 a and b.* Scanning electron micrographs of hair fibres from cases I and II. Note triangular and kidney form of the cross sections and the longitudinal groove (hence the term pili canaliculi). White bar: 0.1 mm.



*Fig. 3.* Cross section of spun glass hair (case I) seen in the transmission electron microscope. The "finger print whorl" pattern is conspicuous. This is a normal cortex cross section.  $\times 110\,000$ . Black bar: 0.1  $\mu\text{m}$ .

defects in organs of ectodermal origin have been discovered, nor are there any mental abnormalities associated with this condition.

The main complaint in the patients with glass wool hair is the difficulty to manage the hair. No complaints of brittleness or other dysfunction have been reported by our patients or in the literature (7). The only other abnormality is a tendency to "crimp" causing entanglement of the fibres. The longer the hair, the more manageable it appears to become. Thus, most patients no longer complain of entanglement when they have reached the "teens".

The result of our SEM study is completely in accordance with previous findings (3–8). Although light microscopic studies have not revealed any conspicuous characteristic of spun glass hair fibre cross sections except for the peculiar form no previous study has been undertaken to confirm this at electron microscopic resolution. In our two cases the TEM resolution morphology appears completely normal.

Biochemical analysis of hair samples obtained from the patients of Stroud & Mehregan (8) and Schoenfield & Lupulesco (7) and further one patient (1) have not revealed any significant divergence from a normal amino acid analysis. Also stress-strain analysis in water showed normal breaking strength in the glass wool hairs. The X-ray diffraction experiments gave normal patterns according to the investigation by Baden et al. (1). Stroud & Mehregan (8), Schoenfield & Lupulesco (7) and lately Stroud (9) have shown convincingly that the hair follicle cross section has the normal rounded appearance whereas the hair fibre contained within the follicle has an irregular shape. This may vary from a triangular to a kidney-like form in the cross section. The inner root sheath has a corresponding irregular form. In normal hair follicles the inner root sheath compensates for any irregularity from a circular cross section of the fibre by a process called complementation, i.e. the hair fibre proper and the inner root sheath in conjunction form a unit of circular appearance to which adheres the outer root sheath in the form of a cylinder with constant wall thickness. As opposed to this in cases of "spun glass" hair the outer root sheath fills in the irregularities of the central unit. The differentiation of the inner root sheath has reached maturity before the cortex. Hence, it is conceivable that the form of the hair fibre is modelled by a tough, mechanically resistant inner root sheath. It appears that serial cross sections of hair follicles from cases of "spun glass" hair are histologically normal up to the zone of keratinization where the deformation of the inner root sheath conforms to the irregular cross section of the hair fibre. Thus the condition has been regarded as a defect in the keratinization process (9).

The present report underlines the fact that further studies by TEM and quantitative methods such as electron probe microanalysis of the development of the condition in the hair follicle should be undertaken when biopsies are made available. This would probably throw some light on the keratinization process in the inner root sheath as related to the corresponding development in the cortex part of the hair fibre. Of special interest in this context is an analysis of the sulfur distribution over the root sheaths and the cortex in the zone of keratinization.

#### ACKNOWLEDGEMENTS

We are grateful for the preparative work done by Margaretha Andersson. Grants from the Karolinska Institutet supported these investigations.

#### REFERENCES

1. Baden HP, Schoenfield RJ, Stroud JD, Happle R. Physicochemical properties of "spun glass" hair. *Acta Derm Venereol (Stockh)* 1981; 61:441–4.

2. Birberck MSC, Mercer EH. The electron microscopy of the human hair follicle. I. Introduction and the hair cortex. *J Biophys Biochem Cytol* 1957; 3: 203-14.
3. Dupré A, Bonafé J-L, Litoux F, Victor M. Le syndrome des cheveux incoiffable. Pili trianguli et canaliculi. *Ann Dermatol Venereol (Paris)* 1978; 105: 627-30.
4. Ferrando J, Fonttarnau R, Gratacos MR, Mascaro JM. Pili canaliculi ("Cheveux incoiffable" ou "Cheveux en fibre de verre"). Dix nouveaux cas avec étude au microscope électronique à balayage. *Ann Dermatol Venereol (Paris)* 1980; 107: 243-8.
5. Goerz G, Busch P. Das Glaswoll-Haar ("Spun glass" hair). *Arch Dermatol Res* 1981; 270: 353-9.
6. van Neste D, Armijo-Subieta F, Tennstedt D, Mrena E, Marchal G, Lachapelle JM, Gengoux P, Dumont M, Decroix JM. The uncombable hair syndrome. Four non-familial cases of pili trianguli et canaliculi. *Arch Dermatol Res* 1981; 271: 223-7.
7. Schoenfeld RJ, Lupulescu AP. Crimped "Spun glass" hair in siblings: with twelve-year follow-up of an earlier case. In: Orfanos CE, Montagna W, Stüttgen G. *Hair research*. Berlin, Heidelberg, New York: Springer-Verlag, 1981: 424-9.
8. Stroud JD, Mehregan AH. "Spun glass" hair: A clinicopathologic study of an unusual hair defect. In: Brown AC. *The first human hair symposium*, Medcom Press, New York, 1973: 103-07.
9. Stroud JD. Complementation of the inner root sheath of human hair. In: Brown AC, Crouse RG. *Hair, trace elements and human illness*. New York: Praeger Scientific, 1980: 163-8.