

Petechiae and Vasculitis in Asymptomatic Primary Biliary Cirrhosis

HANS DIEDERICHSEN,¹ PAUL GADE SØRENSEN,¹ HANS MICKLEY,¹
ESTER HAGE² and FINN SCHULTZ-LARSEN³

¹*Department of Immunology and Blood Grouping,* ²*Department of Pathology and*

³*Department of Dermatology, Odense University Hospital, Odense, Denmark*

Diederichsen H, Sørensen PG, Mickley H, Hage E, Schultz-Larsen F. Petechiae and vasculitis in asymptomatic primary biliary cirrhosis. *Acta Derm Venereol (Stockh)* 1985; 65: 263–266.

Recurrent petechiae of the lower legs and signs of asymptomatic primary biliary cirrhosis have been found in three women. Large immune complexes were identified in the serum of three and cryoglobulin/cryofibrinogen in two. Histological examination of skin biopsies revealed a leukocytoclastic vasculitis in all three patients. Direct immunofluorescent studies showed deposits of IgM, C3 and fibrinogen in and around the walls of the small vessels of the skin of two and C3 as well as fibrinogen in one patient. It is suggested that leukocytoclastic vasculitis may be a microscopic feature of the systemic involvement in asymptomatic primary biliary cirrhosis, and petechiae the clinical manifestation. *Key words: Circulating immune complexes; Direct immunofluorescence; Leukocytoclastic vasculitis and purpura.* (Received May 15, 1984.)

H. Diederichsen, Department of Immunology and Blood Grouping, Odense University Hospital, DK-5000 Odense C, Denmark.

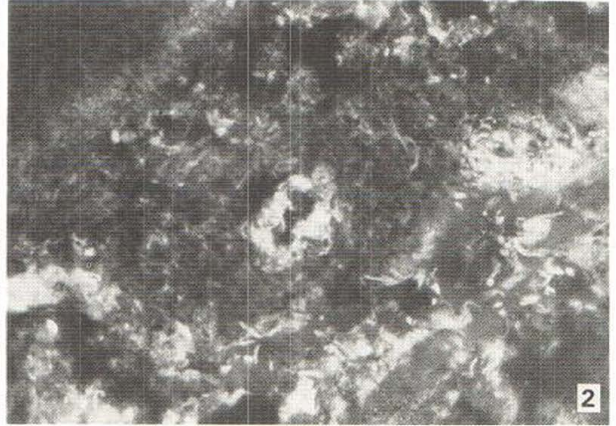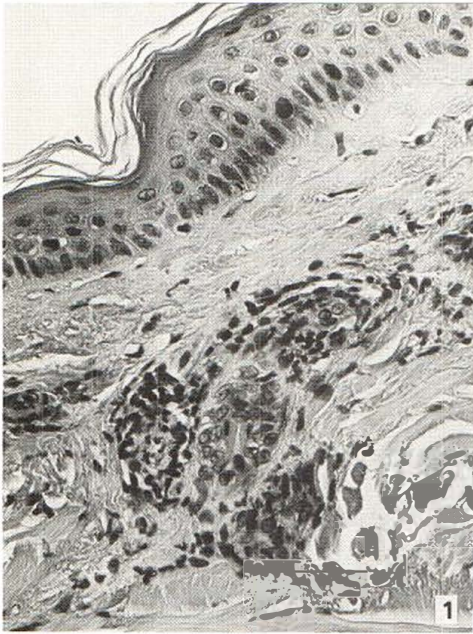


Fig. 1. Patient 1. Affected skin with leukocytoclastic vasculitis. $\times 900$.

Fig. 2. Patient 1. Complement C3 is seen by means of direct immunofluorescence in and around the wall of a small vessel.

Primary biliary cirrhosis (PBC) is a rare, chronic and slowly progressive disease of unknown etiology, characterized by non-suppurative destruction of the intrahepatic bile ducts. The disease frequently remains in an asymptomatic stage for many years (1). Multiple organ systems including the skin may be involved in PBC. Immunoglobulin and complement deposits have been demonstrated in apparently normal skin of patients with PBC (2, 3). However, recurrent purpura and cutaneous vasculitis do not appear to have been reported in such patients. Signs of asymptomatic PBC, with both petechial purpura of the lower legs and immunofluorescent as well as histological signs of vasculitis in the dermal vessels were found in three women.

MATERIAL AND METHODS

Case 1

J. E., female born in 1915. She has suffered from keratoconjunctivitis sicca since 1975. From 1976 she had a history of recurrent attacks on the lower legs of purpura of about four days' duration. The patient had no xerostomia or symptoms of liver disease. Platelet count, coagulation studies and bleeding time were normal. Examination for immune complexes (CIC), cryoglobulin and cryofibrinogen were positive several times. Biochemical liver tests were elevated in 1978 (Table I), and liver biopsy the same year revealed histological changes compatible with PBC, stage III-IV, according to Scheuer's criteria (4). Biopsy of the affected skin showed leukocytoclastic vasculitis (Fig. 1). Direct immunofluorescent studies of the skin showed deposits of IgM, C3 (Fig. 2) and fibrinogen in and around the walls of the small vessels.

Case 2

A. S., female born in 1910. In 1973 she had recurrent purpura, burning sensations and numbness of the lower legs. Initially the elements persisted for only a few days each time. In 1975 the patient was admitted to hospital because of petechiae and sensory neuropathy of the lower legs. She had never experienced dry eyes or dry mouth. Platelet count, coagulation and bleeding studies were normal. Her serum contained CIC. Testing for cryoglobulin and cryofibrinogen were negative at a time when no petechiae were present. Biochemical liver tests stayed elevated since 1971 (Table I). A liver biopsy was found compatible with PBC, stage I-II in 1975, and biopsy of the affected skin revealed

leukocytoclastic vasculitis. Direct immunofluorescence of the skin was performed for the first time in 1979, and this patient too showed deposits of IgM, C3 and fibrinogen in and around the small vessels of the upper dermis.

Case 3

I. N., female born in 1924. Biochemical liver tests have been elevated since 1976 (Table I). Recurrent petechiae of the lower legs were noticed from 1978, and the elements persisted for about a week each time. These attacks were accompanied by a few days of malaise and fever. There were no symptoms of liver disease otherwise, and she had no ocular or oral manifestations. Platelet count, coagulation factors and bleeding time were normal. The serum contained CIC. Testing for cryoglobulin was repeatedly negative, while cryofibrinogen was detected once. Liver biopsy was normal in 1976, but from 1979 revealed chronic granulomatous hepatitis, possibly developing into cirrhosis, most likely PBC. Biopsy of the affected skin showed a leukocytoclastic vasculitis in 1978. One year later, immunofluorescent studies of the skin showed deposits of C3 and fibrinogen in and around the walls of the small vessels of the dermis.

Method

The immunofluorescence investigation was performed on punch biopsies from involved skin. The skin biopsies were frozen in liquid nitrogen immediately after removal. Four μm thick sections were cut on a cryostat microtome. Unfixed sections were incubated with fluorescein isothiocyanate conjugated anti-human IgG, IgA, IgM, C3 and fibrinogen (Hoechst, Germany) for half an hour at room temperature. The molar F/P ratio was 1.4 and the working dilution 1/64. The sections were washed for three times five minutes in phosphate buffered saline pH 7.2 (PBS) and mounted with equal parts of glycerol and PBS. The slides were read in a Leitz fluorescence microscope with transmitted light, a barrier filter BG and an exciter filter 53. Punch biopsies from the skin were taken for histologic examination.

DISCUSSION

Our patients were all middle aged women with asymptomatic liver disease. Liver biochemical tests were abnormal with slightly increased aspartate aminotransferase, elevated glutamylpeptidase and markedly elevated alkaline phosphatase (Table I). Two of the patients had mitochondrial antibody and the liver biopsy was compatible with PBC in both cases. Liver biopsy in the third patient was indicative of PBC, although no mitochondrial antibody could be demonstrated.

PBC is a disease with multisystemic involvement. The principal dermatologic features are pruritus, hyperpigmentation, xanthelasmata and macular-papular exanthema (1, 2).

Table I. Biochemical liver test and immunological findings in serum from three patients with PBC and recurrent petechiae of the lower legs

	Case 1	Case 2	Case 3
Total bilirubin (3.8–20.3 $\mu\text{mol/l}$)	10.0	7.9	30.1
Alkaline phosphatase (80–275 U/l)	493	1 296	801
Aspartataminotransferase (10–35 U/l)	70	65	82
Gamma-glutamyltranspeptidase (below 40 U/l)	115	353	309
Cholesterol (3.2–8.2 mmol/l)	5.2	5.9	6.2
IgG (6.2–13.3 g/l)	19.2	19.1	22.2
IgA (0.4–2.80 g/l)	3.57	3.20	9.17
IgM (0.18–1.30 g/l)	1.59	1.16	0.99
CIC	C1q	C1q	C1q
Cryoglobulin	Positive	Negative	Negative
Cryofibrinogen	Positive	Negative	Positive
Mitochondrial antibody	IgG, IgM	IgG, IgM	Negative

Affection of the blood vascular system has previously been reported in PBC as arteriographically demonstrable vasculitis as shown by Thorel et Deshayes (5). Further, Randle et al. (2) and Hendricks et al. (3) have found deposition of immunoglobulin and complement around the vessels of the skin in patients with PBC.

Our three patients had recurrent eruptions of petechial purpura of the lower legs. Histological examination of the affected skin demonstrated in all our patients destruction of the vessel walls, characterized by infiltration of neutrophils, mononuclear cells, fibrin and nuclear dust. These findings are consistent with a leukocytoclastic vasculitis. In accordance with Randle et al. (2) and Hendricks et al. (3) our patients presented deposits of immunoglobulin and C3 in the walls of the dermal vessels, possibly as part of immune complexes with unidentified antigen. This assumption is supported by our findings of CIC in the serum of all three patients. In contrast to the above-mentioned studies (2, 3) no deposition at the basement membrane was found. Neither have we found immunoglobulin in the papillary dermis as shown by Lindgren et al. (6).

PBC is frequently associated with thyroid disease, rheumatoid arthritis, mixed connective tissue disease and Sjögren's syndrome (7). In PBC high level of CIC may reflect the association with autoimmune features (8). Furthermore, CIC is detected in a high proportion of patients with Sjögren's syndrome (9) and extraglandular features of Sjögren's syndrome may include vasculitis and purpura (10). However, only the patient in case 1 suffered from keratoconjunctivitis sicca and, thus, fulfilled two of the diagnostic criteria for Sjögren's syndrome. The remaining two patients had no oral or ocular symptoms, and no other connective tissue disease than PBC was suspected.

We suggest that leukocytoclastic vasculitis is a microscopic feature of the systemic involvement in asymptomatic PBC and that petechiae is the clinical manifestation.

REFERENCES

1. Fox RA, Scheuer PJ, Sherlock S. Asymptomatic primary biliary cirrhosis. *Gut* 1973; 14: 444-7.
2. Randle HW, Millns JL, Schroeter AL, Winkelmann RK. Cutaneous immunofluorescence in primary biliary cirrhosis. *JAMA* 1981; 246: 1679-81.
3. Hendricks AA, Hutcheon DF, Maddrey WC, Farmer ER, Provost TT. Cutaneous immunoglobulin deposition in primary biliary cirrhosis. *Arch Dermatol* 1982; 118: 634-37.
4. Scheuer PJ. Primary biliary cirrhosis. *Proc R Soc Lond Biol* 1967; 60: 1257-60.
5. Thorel JB, Deshayes P. Nécrose digitale révélatrice d'un syndrome de Reynolds (cirrhose biliaire primitive et sclérodémie) avec syndrome de Gougerot-Sjögren. *Nouv Presse Méd* 1981; 10: 2295-6.
6. Lindgren S, Eriksson S, Löfberg H, McKay J. IgM deposition in skin from patients with primary biliary cirrhosis. *Acta Med Scand* 1981; 210: 317-20.
7. James O, Watson AJ, Mecklon AF. Primary biliary cirrhosis—a revised clinical spectrum. *Lancet* 1981; i: 1278-81.
8. Gupta RC, Dickson ER, McDuffie FC, Baggenstoss AH. Immune complexes in primary biliary cirrhosis. Higher prevalence of circulating immune complexes in patients with associated autoimmune features. *Am J Med* 1982; 73: 192-8.
9. Fischbach M, Char D, Christensen M, Daniels T, Whaley K, Alspaugh M, Talal N. Immune complexes in Sjögren's syndrome. *Arthritis Rheum* 1980; 23: 791-5.
10. Alexander EL, Provost TT. Cutaneous manifestations of primary Sjögren's syndrome: A reflection of vasculitis and association with anti-RO(SSA) antibodies. *J Invest Dermatol* 1983; 80: 386-91.