

SHORT REPORTS

An Immunohistochemical Staining of Epidermal Langerhans' Cells in Tinea cruris

LENNART EMTESTAM, TAAVI KAAMAN, ANDERS HOVMARK
and EVA ÅSBRINK

*Department of Dermatology, and the Dermatological Laboratory,
Södersjukhuset, Stockholm*

Emtestam L, Kaaman T, Hovmark A, Åsbrink E. An immunohistochemical staining of epidermal Langerhans' cells in tinea cruris. *Acta Derm Venereol (Stockh)* 1985; 65: 240-243.

Epidermal Langerhans' cells (LC) were investigated in fresh cryostat sections of ten biopsies from patients with mycologically proven tinea cruris, using OKT6 monoclonal antibodies and avidin-biotin-immunoperoxidase. Compared to the controls, more epidermal LC and an increased number of LC in the upper half of the epidermis were found in the sections from tinea patients. In a double staining method for both OKT6-positivity and hyphae, a tendency towards a gathering of LC and fungal elements was found. The results of this study are in agreement with the theory that epidermal LC are responsible for the antigen uptake in dermatophytosis. *Key words: Antigen presentation; Dermatophytosis; Immunoperoxidase.* (Received October 3, 1984.)

L. Emtestam, Department of Dermatology, Södersjukhuset, S-10064 Stockholm, Sweden.

The Langerhans' cells (LC) are supposed to have an antigen presentation function in the human epidermis (1, 2). In electron microscopic studies, apposition of LC and lymphocytes has been described in allergic contact dermatitis (3) but also in non-allergic conditions, such as toxic patch tests and mere occluded skin (4, 5). Human epidermal LC may induce a T lymphocyte response to trichophytin (6). OKT6 monoclonal antibodies react specifically to LC in the human epidermis (7, 8). The purpose of the present investigation was to study epidermal OKT6 positive dendritic cells, and their relation to the hyphae, in patients with tinea cruris.

MATERIAL AND METHODS

The material consisted of untreated, male patients at the Department of Dermatology, Södersjukhuset, Stockholm, Sweden. Skin biopsies (4 mm punch) were taken from the margin of erythematous, scaly lesions of the inguinal region, in which mycological cultures from skin scrapings were positive with respect to dermatophytes. Their median age was 29 (19-50). Ten biopsies from eight patients were studied. Male medical students and venereologic out patients, with negative mycological cultures from the groins and without history of relevant skin disease, served as controls. The median age of the controls was 31 (18-60), and they were biopsied from macroscopically normal, inguinal skin. The skin biopsies were immediately frozen and stored at -70°C.

Staining procedure

Sections of the skin biopsies, 8 µm thick, were cut on a cryostat and stored overnight at -70°C. After thawing, the sections were fixed in ice-cold acetone and stained with OKT6 monoclonal antibodies (Ortho Diagnostic System Inc, Raritan NJ, USA) in a dilution of 1/100 for one hour and a Vectastain® ABC kit - mouse IgG PK 4002 (Vector Laboratories Inc, Burlingame, Calif., USA) (9). A double staining method for the visualization of both OKT6-positivity and hyphae in the same sections was performed as follows: After staining for OKT6-positivity as described above, a modified periodic acid Schiff (PAS) stain (10) immediately followed, where the initial xylene-alcohol steps were excluded. With this procedure the hyphae were stained dark red without interfering with the yellowish brown OKT6-positivity.

Each section was evaluated by, at least, two investigators in a light microscope using the same high

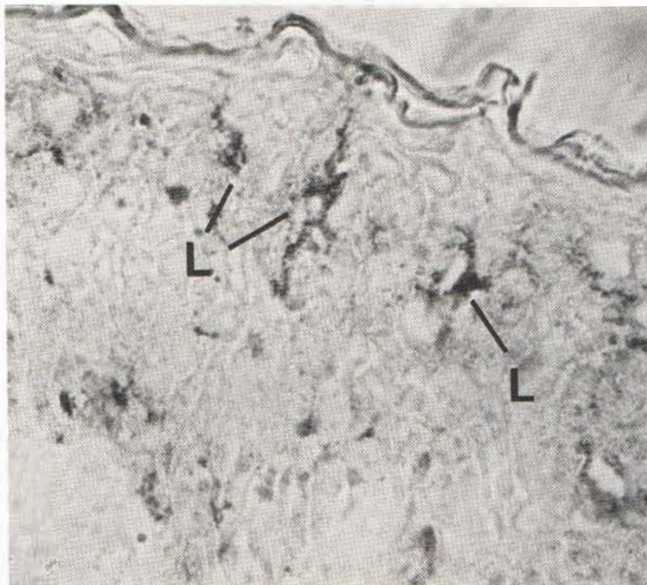


Fig. 1. Tinea cruris: sections stained with OKT6 monoclonal antibodies and immunoperoxidase. Three Langerhans' cells (L) are seen in the upper half of the epidermis.

power fields (microscopic magnification $\times 400$). The number of OKT6 positive dendritic cells were counted per 4 mm length of the epidermis. Folds and perifollicular parts of the epidermis were avoided. Each OKT6 positive dendritic cell in which a nucleus could be seen was counted. Both the total number, and the number in the upper half, of the OKT6 positive dendritic cells of the epidermis were counted.

The Student's *t*-test was used in the statistic calculations.

RESULTS

The mycological cultures revealed *Epidermophyton floccosum* in six cases and *Trichophyton rubrum* in two.

The results of the staining of the epidermal OKT6 positive dendritic cells in sections from patients with tinea cruris are shown in Table I. Compared to the controls, the total number of the epidermal OKT6 positive dendritic cells was increased in biopsies from the patients with tinea cruris. The number of these cells located in the upper half of the epidermis was also increased (Fig. 1). In the controls, the majority of the epidermal OKT6 positive dendritic cells had a suprabasal position. Fungal elements were found in two out of eight biopsies simultaneously with OKT6-positivity. In some sections where hyphae were abundant in the stratum corneum, many OKT6 positive dendritic cells were seen in the upper part of the epidermis (Fig. 2).

Table I. *Tinea cruris*: Average numbers OKT6 positive dendritic cells per 4 mm epidermis

Biopsies	Total number	Thereof located in the upper half
Patients ($n=10$)	94.7*	57.8* (61%)
Controls ($n=15$)	52.1	9.3 (18%)

* $p < 0.01$

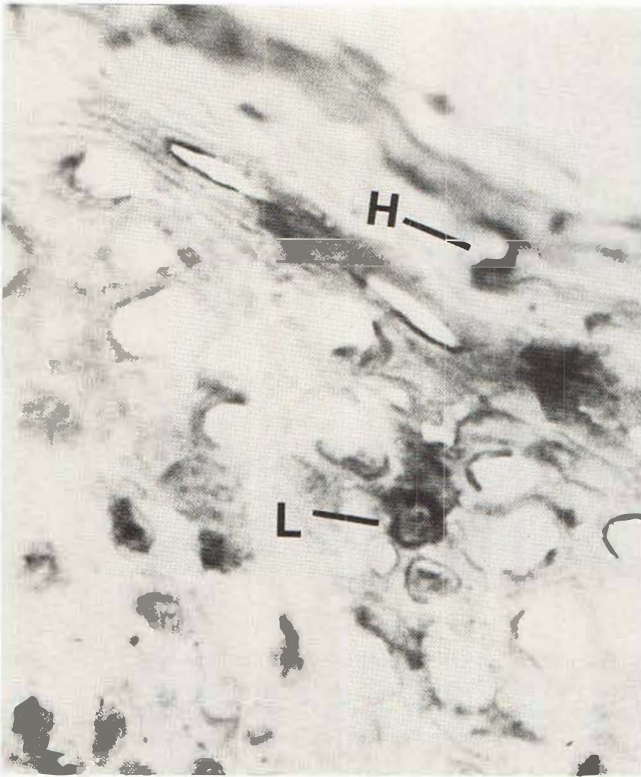


Fig. 2. Tinea cruris: sections double stained for OKT6-positivity and hyphae. Langerhans' cell (L) and hyphae (H).

DISCUSSION

In a recent review article the immunology of human dermatophyte infections was surveyed and the action of the cell-mediated immune response as a part of the host defence against dermatophytosis was discussed (11). An intact function of the cell mediated immune system is needed for effective eradication of infection, but mechanisms involved, such as, antigen uptake, presentation and delivery to the T lymphocytes in tinea infections are poorly understood. It is known that antigenic substances are present, not only in the hyphae invading the stratum corneum, but also around the fungal filaments, suggesting that diffusible products are liberated in situ (12). It has been suggested that the further handling of the antigenic material in the epidermis is taken care of by the LC (1, 2). With this working hypothesis human epidermal LC were investigated using an in vitro assay (6). It was shown that HLA-DR positive cells, i.e. both LC and macrophages, were able to induce a T lymphocyte response to trichophytin antigen. Consequently, the LC constitute one way to process and present the dermatophytic antigen in dermatophytosis in vitro. In the present study, biopsies from patients with tinea cruris were surveyed using OKT6 monoclonal antibodies and immunoperoxidase. In this study an increased number of LC in the epidermis from patients with tinea cruris was found. This increase was particularly prominent in the upper half of the epidermis. These changes could be secondary to unspecific, inflammatory factors or an increased epidermal thickness of tinea infected skin. Similar distribution of the LC may also be found in irritant contact patch reactions (unpublished data). However, the findings of an increased number of LC in the upper half of the epidermis, LC and dendritic staining near hyphae are in agreement with the

hypothesis that the LC are responsible for the initial uptake and processing of the antigen (13) before delivery to the T lymphocytes in dermatophytosis.

REFERENCES

1. Silberberg-Sinakin I, Thorbecke GJ, Baer RL, Rosenthal SA, Berezowsky V. Antigen-bearing Langerhans' cells in skin, dermal lymphatics and in lymph nodes. *Cell Immunol* 1976; 25: 137-151.
2. Wolff K, Stingl G. The Langerhans' cell. *J Invest Dermatol* 1983; 80: 17s-21s.
3. Silberberg I. Apposition of mononuclear cells to Langerhans' cells in contact allergic reactions. *Acta Derm Venereol (Stockh)* 1973; 53: 1-12.
4. Kanerva L, Ranki A-M, Mustakallio K, Lauharanta J. Langerhans' cell-mononuclear cell contacts are not specific for allergy in patch tests. *Br J Dermatol* 1983; 109 Suppl. 25: 64-67.
5. Lindberg M, Forslind B. The effects of occlusion of the skin on the Langerhans' cell and the epidermal mononuclear cells. *Acta Derm Venereol (Stockh)* 1981; 61: 201-205.
6. Braathen L, Kaaman T. Human epidermal Langerhans' cells induce cellular immune response to trichophytin in dermatophytosis. *Br J Dermatol* 1983; 109: 295-300.
7. Fithian E, Kung P, Goldstein G, Rubinfeld M, Fenoglio C, Edelson R. Reactivity of Langerhans' cells with hybridoma antibody. *Proc Natl Acad Sci USA* 1981; 78: 2541-2544.
8. Murphy G, Bhan A, Sato S, Mihm Jr M, Harrist T. A new immunologic marker for Langerhans' cells. *N Engl J Med* 1981; 304: 791-792.
9. Hsu S-M, Raine L, Fanger H. Use of avidin-biotin-peroxidase techniques: a comparison between ABC and unlabeled antibody (PAP) procedures. *J Histochem Cytochem* 1981; 29: 577-580.
10. Pinkus H, Mehregan AH. A guide to dermatohistopathology. New York: Meredith Corp., 1969: 61.
11. Ahmed AR. Immunology of human dermatophyte infections. *Arch Dermatol* 1982; 118: 521-525.
12. Holden CA, Hay RJ, McDonald DM. The antigenicity of *Trichophyton rubrum*: In situ studies by an immunoperoxidase technique in light and electron microscopy. *Acta Derm Venereol (Stockh)* 1981; 61: 207-211.
13. Shelley WB, Juhlin L. Langerhans' cells form a reticuloepithelial trap for external contact antigens. *Nature* 1976; 261: 46-47.