

## Pityriasis rosea (Gibert): Abnormal Distribution Pattern of Antigen Presenting Cells in Situ

J. D. BOS, P. M. HUISMAN, S. R. KRIEG<sup>1</sup> and W. R. FABER

*Departments of Dermatology and <sup>1</sup>Pathology, University of Amsterdam, Academic Medical Center, Amsterdam, The Netherlands*

Bos JD, Huisman PM, Krieg SR, Faber WR. Pityriasis rosea (Gibert): Abnormal distribution pattern of antigen presenting cells in situ. *Acta Derm Venereol (Stockh)* 1985; 65: 132-137.

Pityriasis rosea is a skin disease which is obscure in its etiology and pathogenesis. We studied its immunopathology by immunophenotyping the inflammatory cells in situ using monoclonal antibodies that define leukocyte subsets. Findings as to T-cells and their major subsets did not reveal disease-specific data. Monocytes stained only rarely. Neither natural killer cells, B-cells nor plasma cells were ever found. An unexpected finding was the presence within the infiltrates and rarely within the epidermis of cells having the immunophenotype of interdigitating cells (RFD1+). Intense and dendritic staining with anti-T6 and anti-HLA-DR indicated Langerhans cells to be present in the dermal infiltrates, in between these infiltrates in the papillary dermis, and focally within the parakeratotic horny layer. This Langerhans' cell pattern provides evidence for dermal Langerhans cell compartmentalization and transepidermal Langerhans' cell elimination. Such a distribution indicates a change in Langerhans' cell migration processes in pityriasis rosea pathogenesis. *Key words: Immunopathology; T-cell subsets; Interdigitating cells; Langerhans' cells.* (Received October 3, 1984.)

J. D. Bos, Department of Dermatology, Academic Medical Center, Meibergdreef 9, 1105 AZ Amsterdam, The Netherlands.

Pityriasis rosea (PR) is a self-limited, inflammatory skin disease characterized by oval, erythematopapulosquamous lesions distributed on the trunk, neck and proximal parts of the extremities. The natural history of the disease suggests it to be caused by an as yet unidentified infectious agent. Recent epidemiological findings (1, 2) gave support to this hypothesis.

The clinical appearance of PR has been described in detail by Björnberg & Hellgren (3) and its histopathology was reinvestigated recently by Panizzon & Bloch (4). The main characteristics were found to be the absence or decrease of the granular cell layer, the presence of erythrocytes in the epidermis and finally, homogenization of collagen in the papillary dermis. Other authors have observed dyskeratosis (5, 6) and cytolytic degeneration of keratinocytes adjacent to Langerhans' cells (6, 7).

The inflammatory infiltrate is generally described as lymphohistiocytic. However, a detailed description of the cells involved (aim of the present study) has as yet not been reported.

The availability of monoclonal antibodies (McAb) defining leucocyte subsets has enabled us to study the immunophenotype of inflammatory cells in PR lesions. A possibly disease-specific distribution of Langerhans' cells was observed. Next, the presence of cells showing the immunophenotype of interdigitating cells within these inflammatory infiltrates is also reported.

### PATIENTS

A total of 14 biopsies obtained from 11 patients with PR were studied. Age and sex of the patients as well as duration and type of the lesion(s) biopsied may all be found in Table I.

In 2 patients (E and I) biopsies of both the herald patch and a 'secondary' (peripheral) lesion could be analysed. In 1 patient (K) a second biopsy after 15 days was obtained. A diagnosis of PR was made on a combination of clinical and histopathological findings (3, 4).

## METHODS

A two-stage monoclonal antibody peroxidase conjugated rabbit-antimouse Ig staining system with 3-amino-9-ethyl-carbazol (AEC) as staining reagent was employed as the principal immunophenotyping procedure. Processing of tissue specimens, identification of cell types, immunoperoxidase technique and controls used were essentially the same as described before (8). In short, fresh frozen ( $-70^{\circ}\text{C}$ ) skin specimens were sectioned ( $6\ \mu\text{m}$ ), fixed in fresh pure acetone, and incubated with the McAb for 60 min in a humidified atmosphere. Next, sections were incubated with peroxidase conjugated rabbit anti-mouse Ig for 30 min in a humidified atmosphere. Staining was achieved by incubation of sections in a freshly prepared acetate buffer solution (pH 4.9) containing AEC, dimethylformamide and hydrogen peroxide. The staining reaction was visually controlled and stopped by washing in acetate buffer. Sections were fixed in formalin (4%) and counterstaining was achieved by passage through Mayer's haematoxylin in acetate buffer for 2 min giving a slight nuclear visualisation. Finally, sections were mounted with aquamount.

Enumeration of positively stained cells in the infiltrates was semi-quantitative, similar to Synkovski & Provost (9): - = no positive cell observed;  $\pm$  = sporadic; + = 1-25%; ++ = 26-50%; +++ = 51-75%; ++++ = 76-99%; +++++ = 100%. In selected cases, such as when determining percentages of infiltrating T-cell subsets, a more precise number was estimated.

## MONOCLONAL ANTIBODIES (McAb)

McAb employed in this study were those against lymphocyte markers T1 (Leu-1), T4 (Leu-3a), T8 (Leu-2a); monocyte markers OKM-1, Leu-M3 and NEI-043; Langerhans' cell

Table I. Characteristics of patients studied

? = unknown, + = 1-25%, ++ = 26-50%, +++ = 51-75%, p = peripheral, h = herald

Patient	Age (years)	Sex	Lesion type	Lesion age (days)	Leu-1+ (%)	T4/T8 ratio	HLA-DR+, T6+ material in parakeratosis
A	40	m	p	30	+++	2	Present
B	28	m	p	7	+++	8	Present
C	25	m	p	10	+++	4	Present
D	22	f	p	21	++	2	Present
E	31	m	h	14	++	2	Present
			p	14	+++	3	Present
F	23	f	p	?	++	2	Present
G	19	f	p	14	+++	2	Present
H	22	m	p	7	+++	2	Present
I	31	f	h	5	+++	2	Present
			p	5	+++	2	Present
J	20	f	p	?	++	1	Present
K	42	m	p	?	+++	2	Present
			p	?+15	+	1	Absent

marker T6 (OKT-6); interdigitating cell marker RFD1; natural killer cell marker HNK-1 (Leu-7); B- and plasma cell markers, anti-kappa and anti-lambda Ig light chains, and finally anti-HLA-DR.

Leu-1 stains 95% of thymocytes and over 95% of peripheral T-lymphocytes (10). Leu-3a stains 95% of thymocytes and T-helper/inducer cells, whereas Leu-2a reacts with 85–95% of thymocytes and with suppressor/cytotoxic T-cells (11). OKM-1 stains monocytes as well as granulocytes (12). Leu-M3 (13) and NEI-043 are specific for peripheral monocytes. OKT-6 stains corticothymocytes and Langerhans' cells (14, 15) while RFD1 reacts with interdigitating cells (16). Leu-7 reacts with a cytoplasmic membrane antigen of cells that harbour the natural killer capacity (17). Anti-kappa/lambda Ig light chains react with all immunoglobulins and were titrated on normal B-cells in lymph node sections in order to have a reagent for B- and plasma cells. Finally, anti-HLA-DR reacts with activated T-cells, Langerhans' cells, interdigitating cells, B-lymphocytes, endothelial cells and monocytes/macrophages.

OKT-6 and OKM-1 were obtained from Orthoclone. NEI-043 was purchased from New England Nuclear (Boston, Massachusetts). All other McAb were provided by Becton Dickinson Laboratories (Sunnyvale, California), with the exception of RFD1 which was a generous gift from L. W. Poulter (London).

## RESULTS

### *Lymphocyte markers (Table I)*

In 9 out of 14 biopsies more than 50% of the infiltrating cells were T-lymphocytes as they were Leu-1+. In 4 biopsies (patients D, E, F and J) the percentage was 25–50%. A rather small percentage (1–25%) was observed in the spontaneously resolving lesion of patient K. By comparing succeeding slides, the ratio of Leu-3a+ versus Leu-2a+ positive cells (i.e. helper/inducer versus suppressor/cytotoxic lymphocytes) was found to be varying from 8:1 to 1:1. In this (rather limited) series no obvious relation between lesion type or lesion age and Leu-3a/Leu-2a ratio was apparent.

Infiltrating and dermally localized T-lymphocytes did not seem to be activated as the anti-HLA-DR staining pattern was mainly dendritic. This possible lack of activation was also indicated by subtraction analysis of the results of RFD1, OKT-6 and HLA-DR staining of the dermal infiltrates. HLA-DR staining could be completely explained by the presence of OKT-6+ and RFD1+ cells within the inflammatory infiltrates.

Exocytosis of Leu-1+ cells was always present except in patient C and in the second biopsy of patient K. No preferential exocytosis of any of the two major subsets (either Leu-2a+ or Leu-3a+) could be observed, although the impression remains that exocytic Leu-2a+ cells outnumbered the Leu-3a+ cells.

### *Langerhans' cell markers*

All the dermal infiltrates in all biopsies were heavily stained with OKT-6 in a dendritic pattern. Moreover, in all biopsies except those of patients I (peripheral lesions) and K (both lesions), a dendritic staining pattern was found with both OKT-6 and anti-HLA-DR in papillary areas where no lymphocytic infiltrate was present.

Epidermal Langerhans' cells as stained by anti-HLA-DR and OKT-6 were not quantitated. Nevertheless, there was a strong suggestion of increased numbers of these cells in most biopsies studied. Very apparent was the presence of dense OKT-6+ (Fig. 1) and HLA-DR+ (Fig. 2) material, often dendritic, within all parakeratotic horny layers that were focally present within all lesions studied. The only exception was the spontaneously healing lesion of patient K in which no parakeratosis was present.

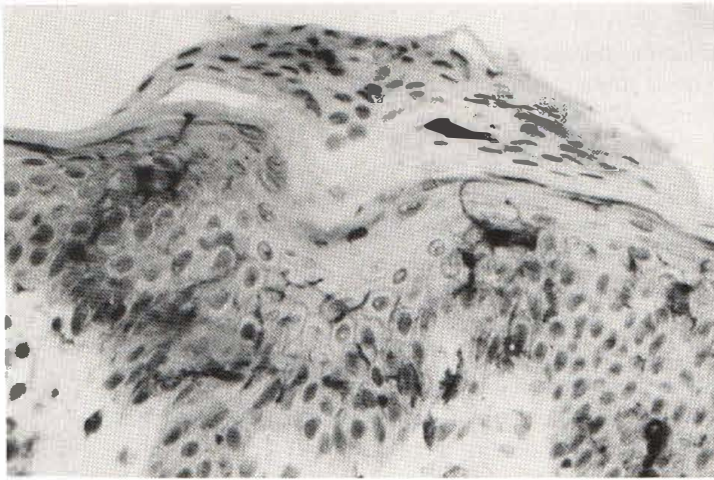


Fig. 1. Detail of pityriasis rosea skin lesion showing Langerhans' cells within papillary dermis, epidermis and within parakeratotic horny layer also (anti-T6:  $\times 250$ ).

#### *Interdigitating cell markers*

All the biopsies studied had clearly positive staining with RFD1 in a dendritic pattern, indicating interdigitating cells to be part of the inflammatory infiltrate in pityriasis rosea. In three biopsies (patients A, B and H) sporadic exocytosis of RFD1+ cells with only short dendrites could be observed. Serial sections stained with anti-HLA-DR were not helpful in determining interdigitating cell distribution since great numbers of Langerhans' cells were present at very close distances.

#### *Monocyte and natural killer cell markers*

Leu-7+ (HNK-1) cells were not observed, indicating absence of natural killer cell activity in pityriasis rosea lesions. Monocyte markers OKM-1, Leu-M3 and NEI-043 revealed positive cells only sporadically within the infiltrates. Rarely, they were observed exocytic within the epidermis.

"Cross-reactivity" of NEI-043 with sebaceous and sweat gland cells and of Leu-7 with neural structures especially in the deeper parts of the dermis was noted.

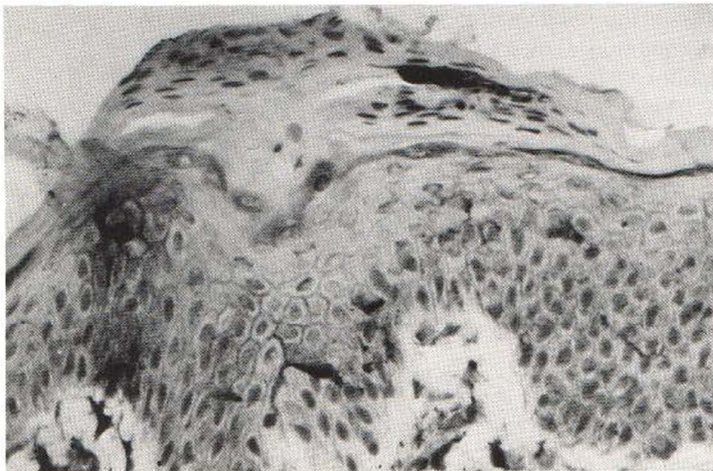


Fig. 2. Serial section from the same biopsy as shown in Fig. 1; a similar staining pattern is observed with anti-HLA-DR ( $\times 250$ ).

### *B- and plasma cell markers*

With a mixture of anti-kappa and anti-lambda monoclonal antibodies, no B- or plasma cells were found within the lesions of pityriasis rosea.

## DISCUSSION

The finding of increased T4/T8 ratios in some of the PR lesions is certainly not disease-specific. Dermatotropism or selective recruitment of the helper/inducer subset *in situ* has now been observed in a wide variety of, mostly chronic, inflammatory skin diseases. In lupus erythematosus, we previously noted a possible relation between duration of the skin lesion and an increase in the T4/T8 ratio (18). A similar increase in the *in situ* T4/T8 ratio with duration of clinical symptoms has been suggested in psoriasis (19). The present study which deals with a relatively acute and self-limited condition did not reveal such a relation. The *in situ* T4/T8 ratio of 2 as observed in most lesions of this study is not grossly deviant from circulating ratios normally obtained in healthy donors. Peripheral T4/T8 ratios were not determined. There is one study in which circulating lymphocytes of PR patients were studied (20). These authors described a slight decrease in T-cells as determined by an E-rosetting technique. Next, an increase in circulating B-cells bearing IgD and/or IgM was observed. This circulating increase in B-cells is not accompanied by their infiltration of the lesional skin as we could not detect them in our study.

Correlation of the results with anti-HLA-DR and the other McAb findings suggests that infiltrating T-cells did not seem to be activated. Double staining techniques are needed to be more certain as to whether or not T-lymphocytes within PR lesional skin are activated.

The most apparent and interesting results of this study are those concerning the presence and distribution patterns of antigen presenting cells with the immunophenotype of Langerhans' cells and interdigitating cells. In all the patients RFD1+ cells were detected in substantial numbers and their close apposition to infiltrating T-cells suggests them to be actively involved in local immune mechanisms. Interdigitating cells are normally present in the T-cell areas of the reticuloendothelial system. Accumulations of these ID-cells have now been described in the inflamed synovial lining layers of rheumatoid arthritis (21), the granulomatoma of sarcoidosis (22) and leprosy (23) and in the lesional skin of untreated psoriasis (24) and, to a lesser extent, atopic dermatitis (25). A spacial relationship with T-cell concentrations was always found and it is suggested that this combination may be indicative for T-cell mediated immune reactions.

The presence of dendritic cells with the immunophenotype of Langerhans' cells (T6+, HLA-DR+) in dermal areas in between the inflammatory infiltrates has not been observed in any other inflammatory skin condition studied so far. An exception is histiocytosis-X in which almost pure accumulations of Langerhans' cells with a different immunophenotype may be observed (26, 27). The constant findings of T6+, HLA-DR+ material within parakeratotic scales has not been described in any other parakeratotic skin disorder.

This Langerhans' cell pattern indicates these cells to be compartmentalized within the papillary dermis in PR. It seems that transepidermal elimination of Langerhans' cells occurs in this skin disease. Taken together, these results strongly indicate changes in Langerhans' cell migration processes in PR pathogenesis. Increased concentrations of Langerhans' cell specific chemo-attractants or 'immobilisins' may be responsible for this phenomenon.

## ACKNOWLEDGEMENT

We wish to thank Dr L. W. Poulter (London) for providing monoclonal antibody RFD1.

## REFERENCES

1. Messenger AG, Knox EG, Summerley R, Muston HI, Ilderton E. Case clustering in pityriasis rosea: support for role of an infective agent. *Br Med J* 1982; 284: 371-373.
2. Chuang T-I, Perry HO, Ilstrup DM, Kurland DM. Recent upper respiratory tract infection and pityriasis rosea: a case-control study of 249 matched pairs. *Br J Dermatol* 1983; 108: 587-591.
3. Björnberg A, Hellgren A. Pityriasis rosea: a statistical, clinical and laboratory investigation of 826 patients and matched healthy controls. *Acta Derm Venereol (Stockh)* 1962; 42 (suppl 50): 1-68.
4. Panizzon R, Bloch PH. Histopathology of pityriasis rosea Gibert: qualitative and quantitative light microscopic study of 62 biopsies of 40 patients. *Dermatologica* 1982; 165: 551-558.
5. Stern K, Wolf JE, Rosen T. Focal acantholytic dyskeratosis in pityriasis rosea. *Arch Dermatol* 1979; 115: 497.
6. Aoshima T, Komura J, Ofuji S. Virus-like particles in the herald patch of pityriasis rosea. *Dermatologica* 1981; 162: 64-65.
7. Takaki T, Kiyazaki H. Cytolytic degeneration in keratinocytes adjacent to Langerhans cells in herald patches of pityriasis rosea patients. *Acta Derm Venereol (Stockh)* 1976; 56: 99-103.
8. Bos JD, Hulsebosch H-J, Krieg SR, Bakker PM, Cormane RH. Immunocompetent cells in psoriasis: in situ immunophenotyping by monoclonal antibodies. *Arch Dermatol Res* 1983; 275: 181-187.
9. Synkowski DR, Provost TT. Enumeration of T-cell subpopulations in lupus erythematosus lesions using monoclonal antibodies. *Clin Res* 1982; 30: 611A.
10. Bergman Y, Levy R. Biosynthesis and processing of a human T-lymphocyte antigen. *J Immunol* 1982; 128: 1334-1340.
11. Kotzin BL, Benice CJ, Engleman EG. Induction of immunoglobulin secreting cells in the allogeneic mixed lymphocyte reaction: Regulation by helper and suppressor lymphocytic subsets in man. *J Immunol* 1981; 127: 931-935.
12. Breard J, Reinherz EL, Kung PC, Goldstein J, Schlossman SF. A monoclonal antibody reactive with human peripheral blood monocytes. *J Immunol* 1982; 124: 1943-1948.
13. Dimitriu-Bona A, Burmester GR, Waters SJ, Winchester RJ. Human mononuclear phagocyte differentiation antigens. I. Patterns of antigenic expression on the surface of human monocytes and macrophages defined by monoclonal antibodies. *J Immunol* 1983; 130: 145-149.
14. Fithian E, Kung P, Goldstein G, Rubinfeld M, Fenoglio C, Edelson R. Reactivity of Langerhans cells with hybridoma antibody. *Proc Natl Acad Sci USA* 1981; 78: 2541-2544.
15. Murphy GF. Monoclonal anti-T6 antibody and Langerhans cells. *Br J Dermatol* 1982; 107: 487-489.
16. Poulter LW. Antigen presenting cells in situ: their identification and involvement in immunopathology. *Clin Exp Immunol* 1983; 53: 513-520.
17. Abo T, Balch ChM. A differentiation antigen of human NK and K cells identified by a monoclonal antibody (HNK-1). *J Immunol* 1981; 127: 1024-1029.
18. Bos JD, Emsbroek JA, Krieg SR. T-cell subsets and Langerhans' cells in cutaneous lupus erythematosus. In: MacDonald, DM, ed. *Immunodermatology*. Kent: Butterworths, 1984: 261-266.
19. Baker BS, Swain AF, Valdimarsson H, Fry L. T-cell subpopulations in the blood and skin of patients with psoriasis. *Br J Dermatol* 1984; 110: 37-44.
20. Kermani-Arab V, Roberts JL, Leslie GA. Structure and function of human IgD. XVI: T and B lymphocytes in pityriasis rosea. *Int Arch All Appl Immunol* 1978; 57: 201-209.
21. Poulter LW, Duke O, Hobbs S, Janossy G, Panayi G, Seymour G. The involvement of interdigitating (antigen presenting) cells in the pathogenesis of rheumatoid arthritis. *Clin Exp Immunol* 1983; 51: 247-251.
22. Mishra BB, Poulter LW, Janossy G, Geraint James D. The distribution of lymphoid and macrophage like cell subsets of sarcoid and Kveim granulomata: possible mechanisms of negative PPD reaction in sarcoidosis. *Clin Exp Immunol* 1983; 54: 705-715.
23. Poulter LW, Collings LA, Tung KS, Waters MFR. Parasitism of antigen presenting cells in hyperbaccillary leprosy. *Clin Exp Immunol* 1984; 55: 611-617.
24. Poulter LW, Russell Jones R, Hobbs S. The significance of antigen presenting cells in psoriasis vulgaris. In: MacDonald, DM, ed. *Immunodermatology*. Kent: Butterworth, 1984: 185-188.
25. Sillevs Smitt JH, Bos JD, Hulsebosch H-J, Krieg SR. Antigen presenting cells and T-cell subsets in atopic dermatitis: in situ imbalance in immunophenotype. Submitted for publication.
26. Harrist TJ, Bhan AK, Murphey S, Sato A, Mihm MC. Histiocytosis-X: in situ characterization of cutaneous lesions. *Am J Clin Pathol* 1983; 79: 294-300.
27. Bos JD, Sillevs Smitt JH, Krieg SR, Bakker PM, Vos GD, van Zaane DJ. Acute disseminated histiocytosis-X: in situ immunophenotyping with monoclonal antibodies. *J Cut Pathol* 1984; 11: 59-64.