

Angioendotheliosarcoma of the Nose—A Case Report

ATLE WÆRSTED, KLAUS E. ANDERSEN and JENS P. HART HANSEN

*Departments of Dermatology and Pathology, Gentofte Hospital, Hellerup,
University of Copenhagen, Denmark*

Wærsted A, Andersen KE, Hart Hansen JP. Angioendotheliosarcoma of the nose—a case report. *Acta Derm Venereol (Stockh)* 1984; 64:88–90.

Angioendotheliosarcoma of the face or scalp is regarded as a highly malignant tumor. We present a case with onset as a purple macule on the nose, suspected to be rosacea, and emphasize the use of early skin biopsy when a red or purple discoloration is seen in the face of elderly people. *Key word: Angioendotheliosarcoma.* (Received June 14, 1983.)

A. Wærsted, Department of Dermatology, University of Copenhagen, Gentofte Hospital, 2900 Hellerup, Denmark.

Angioendotheliosarcoma of the face or scalp is a rare tumor occurring in elderly people, predominantly men (1, 2), with a median survival of 24 months (1), and very few reported

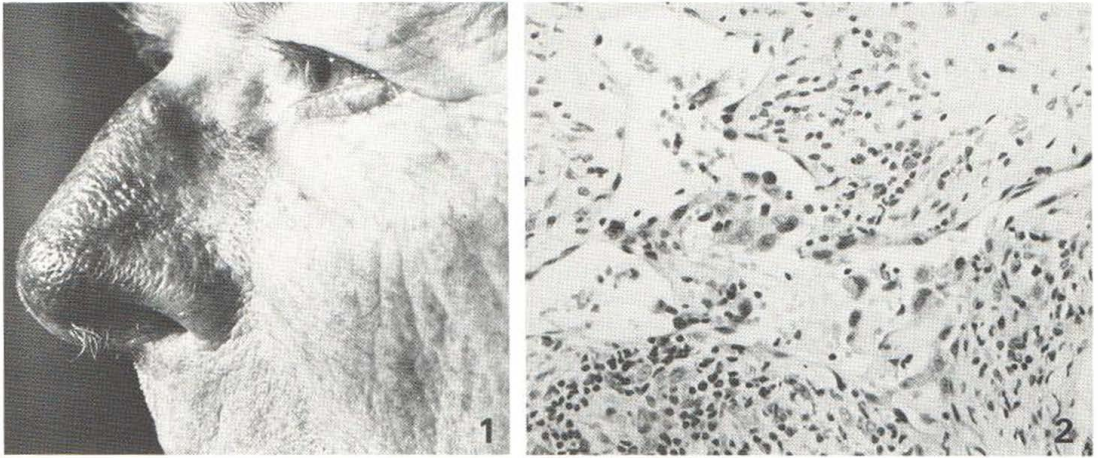


Fig. 1. The left side at referral to our clinic.

Fig. 2. Irregular vascular channels lined by large and pleomorphic endothelial cells. H & E. $\times 400$.

to survive 10 years (1, 2, 3). The tumor is resistant to chemotherapy, but radiation has a palliative effect and even led to a long lasting regression in some cases (1, 2). Wide excision, possibly followed by radiation, is recommended (4). Of the 42 cases reported by Wilson Jones, 4 with the tumor localized to the nose showed a somewhat better prognosis (2). The tumor usually begins as a red, purple or brown macule or papule. Ulceration and hemorrhage occur late in the course (5). The early diagnosis is often difficult from a clinical point of view.

The following case is presented to show the clinical picture. The tumor was diffuse and infiltrative without a nodule formation, hence the verification of the malignant nature of this disorder depended on a biopsy.

CASE REPORT

An 83-year-old retired male office worker was referred with discoloration of the nose (Fig. 1). Thirteen months previously he had received radiation therapy on a squamous cell carcinoma anterior to the right ear. There was no sign of recurrence. A few months later he developed a purple, sharply demarcated area on the back of the nose, slightly infiltrated, but not elevated. The discoloration spread slowly to the cheek below the right eye. The disorder was initially perceived as rosacea, and he was treated with tetracyclines without effect. Later telangiectasias were electrocoagulated. More than half a year after the appearance of the discoloration, he was referred to our clinic. A biopsy showed angioendotheliosarcoma (Fig. 2). Small blood vessels of varying dimensions, coated by large pleomorphic endothelial cells with hyperchromatic nuclei, and scattered lymphocytic infiltration, were seen in the corium. There were few mitoses and normal appendages (6, 7). The patient refused operation and received radiation therapy as the only treatment, with marked regression during an observation period of six months.

COMMENTS

This highly malignant tumor without nodule formation is easy to misdiagnose as a benign disorder. A macular angioendotheliosarcoma appearing on the nose can mimic rosacea (rhinophyma), chronic cellulitis, discoid lupus erythematosus or sarcoidosis (2, 8). We emphasize the use of early skin biopsy in elderly people presenting a red, purple or red-

brown facial discoloration. Radiation therapy alone may in elderly patients with short general life expectancy be a good choice. This therapy can give several years of regression of the tumor, and discouraging results following mutilating excisions implying long time hospitalisation have been reported (1, 2, 7).

REFERENCES

1. Maddox JC, Evans HL. Angiosarcoma of skin and soft tissue: A study of forty-four cases. *Cancer* 1981; 48: 1907-1921.
2. Wilson Jones E. Malignant vascular tumors. *Clin Exp Dermatol* 1976; 1: 287-312.
3. Mehregan AH, Usndek HE. Malignant angioendothelioma. *Arch Dermatol* 1976; 112: 1565-1567.
4. Bart RS, Kopf AW. Angiosarcoma (malignant angioendothelioma) of the scalp. *J Dermatol Surg Oncol* 1980; 6: 528-529.
5. Wilson Jones E. Malignant angioendothelioma of the skin. *Br J Dermatol* 1964; 76: 21-39.
6. Rosai J, Sumner HW. Angiosarcoma of the skin. A clinicopathological and fine structural study. *Hum Pathol* 1976; 7: 83-109.
7. Hori Y. Malignant hemangioendothelioma of the skin. *J Dermatol Surg Oncol* 1981; 7: 130-136.
8. Fischer H, Undeutsch W. Malignes Hämangioendotheliom. *Handbuch der Haut- und Geschlechtskrankheiten (Jadassohn)* 1979; III/3 B: 31-36.