

## Bowel Bypass Arthritis Dermatitis Syndrome: A Histological and Electron Microscopical Study

M. SANDBANK, S. WELTFRIEND and R. WOLF

*Department of Dermatology, Beilinson Medical Center, and the Tel-Aviv University, Petah Tiqva, Israel*

Sandbank M, Weltfriend S, Wolf R. Bowel bypass arthritis dermatitis syndrome: Histological and electron microscopical study. *Acta Derm Venereol* (Stockh) 1984; 64: 79-82.

A case of dermal vasculitis with arthralgia after intestinal bypass surgery is reported. A 36-year-old woman developed arthralgia and skin rash, 1 year after an ileo-jejunal bypass operation was performed for overweight (130 kg). Skin biopsy showed leucocytoclastic vasculitis in the dermis. E.M. study showed clumps of platelets around small dermis blood vessels, and polymorphous perivascular infiltration. The symptoms subsided after tetracycline treatment. *Key words: Bowel bypass; Arthritis; Dermatitis; Vasculitis.* (Received May 13, 1983.)

M. Sandbank, Department of Dermatology, Beilinson Hospital, Petah Tiqva, Israel.

The term bowel bypass syndrome was coined by Dicken & Seehafer in 1979 (1). The association of bypass surgery for overweight and the occurrence of polyarthritis was first reported in 1971 (2). The skin lesions in this syndrome were described as erythema nodosum lesions (3), nodular panniculitis (4), skin papules and pustules and various other eruptions. The disease affects 20% of patients who had bowel bypass surgery for overweight (2). The present case developed the bowel bypass skin lesions and arthralgia one year after the operation.

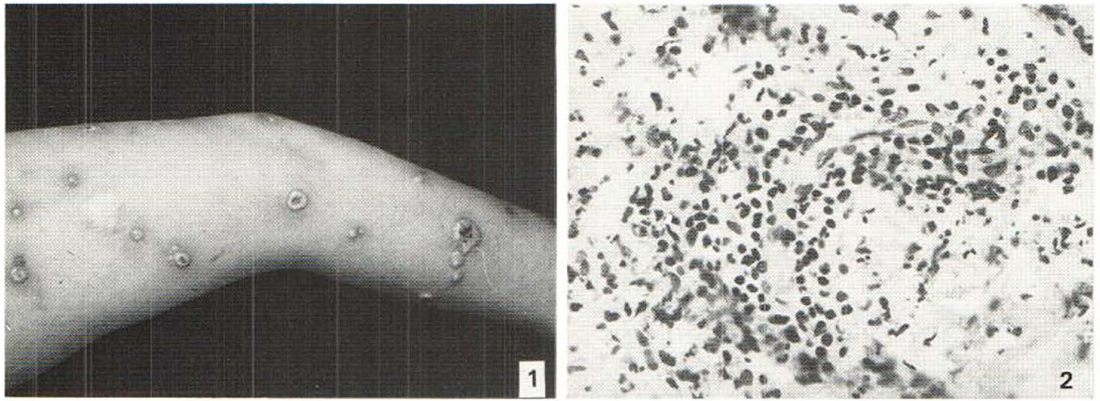
### CASE REPORT

A 36-year-old woman was admitted to the hospital in November 1982 because of a skin rash. In May 1980 an ileo-jejunal bypass was performed because of obesity. She weighed 130 kg and following the operation she lost 65 kg during one year. Six weeks after the operation low levels of Ca and Mg were found and she complained of lower back pains. She received Ca-gluconate, Vitamin D, At-10, KCl and injections of Mg-sulfate 40% and her condition ameliorated.

Her present illness started 2 months before her hospitalization. She complained of abdominal distension and pains. One month later severe joint pains mainly of the wrist and fingers of the hand and the pelvic and shoulder girdles, and she noticed stiffness of these joints mainly in the mornings. Concomitantly erythematous macules in her wrists and a few days later in the center of the macule small vesicles developed which enlarged and became confluent. Similar lesions appeared on the arms, chest and legs.

On admission, she suffered from back pain, blood pressure was 120/88 and her weight was 73 kg. Heart and lungs showed no abnormalities. Her abdomen was distended, tender with diminished peristaltic movements and abdominal X-ray showed the picture of pseudoileus. Her main skin lesions were located on the palms, dorsal portion of upper and forearms. A few lesions were seen on her neck, upper chest and thighs. These lesions consisted of solid vesicles containing pus, measuring 1-2 cm in diameter and encircled by an erythematous halo (Fig. 1).

Laboratory examination: ESR 92/16/h, WBC 12900 with shift to the left, hemoglobin 8.9 g/dl, reticulocytes 150/100, ferrum 28%, thrombocytes 398 000. Urine, BUN, glucose, electrolytes, Ca, P, proteins were normal. Magnesium 1.62 and 1.99, VDRL—negative, ANF—negative, cryoglobulin—normal, cryofibrinogen, complement—normal. Serum protein electrophoresis showed slight diminution of albumin. Immunofluorescent studies showed indirect fluorescence negative. Direct immunofluorescence showed slight traces of specific fluorescence in blood vessels with anti IgM fraction. Culture of the pustules was sterile. Skin tests for the following bacterial antigens were done and all were negative: *Streptococcus hemolytic* and *viridans*, *Staphylococcus albus*, *Klebsiella*, *Hemophilus influenza*, and *Diplococcus pneumonia*. Serum Vitamin B12 and folic acid were normal.



*Fig. 1.* Lesions on arms and forearms. Pus containing vesicles surrounded by erythematous halo.

*Fig. 2.* Swollen endothelial cells, dense perivascular infiltration with polymorphonuclears, lymphocytes and nuclear debris. Hematoxylin-eosin,  $\times 200$ .

#### *Microscopical examination*

The epidermis was edematous, a few polymorphonuclear leukocytes were dispersed between keratinocytes. The upper dermis was edematous and was infiltrated by lymphocytes, mononuclear cells and polymorphonuclear leukocytes. The endothelial cells of the small dermal blood vessels were swollen and the vessels were surrounded by a dense infiltration of lymphocytes, polymorphonuclear leukocytes, and nuclear dust (Fig. 2). P.A.S. stain did not show fibrinoid necrosis of the blood vessel walls. Gram stain did not show any organisms. Electron microscopic examination showed clumps of platelets in the vicinity of blood vessels (Fig. 3). Blood vessels showed openings between endothelial cells, rupture of the basal membrane and emigration of leukocytes through this opening (Fig. 4). The cellular perivascular infiltration consisted of many young immature lymphocytes and polynuclear leukocytes. Extensive search for basal membrane deposits or any intranuclear or intracytoplasmic viruses was negative. She was treated by Achromycin  $4 \times 500$  mg daily and local application of Lotio zinci and Terramycin pulvis. The skin lesions disappeared gradually after 10 days of treatment.

#### DISCUSSION

The etiology of the bowel bypass syndrome is unknown. According to Ely (5) streptococcus pyogenes peptidoglycan is suggested as the causative of the toxic and immunologic features of this syndrome.

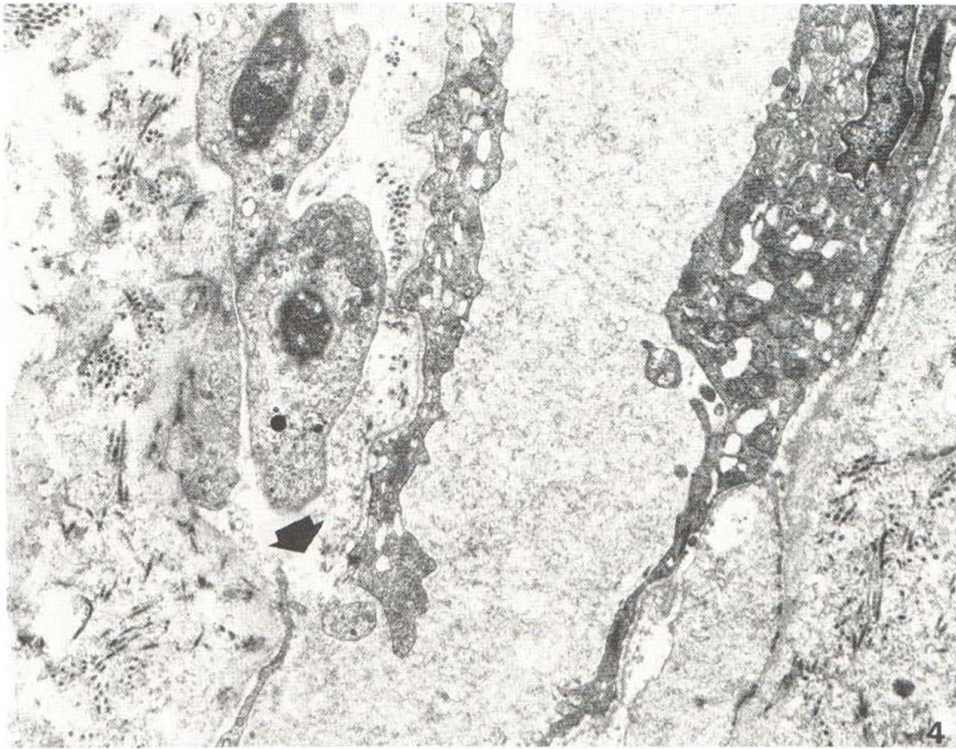
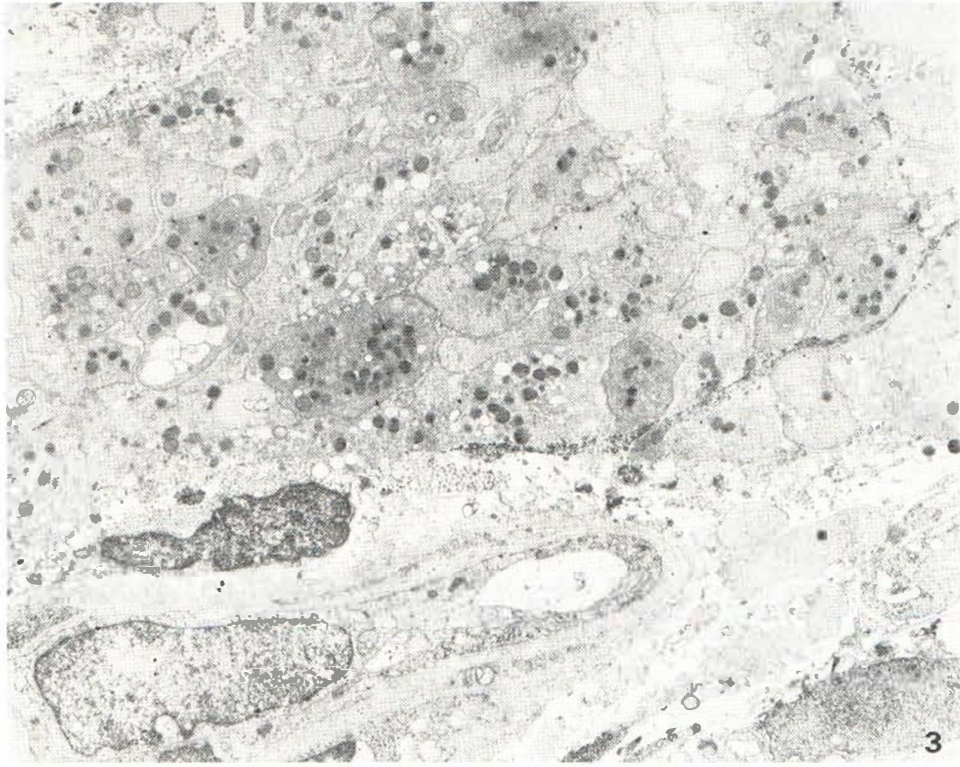
Utsinger (6) showed in 19 out of 21 patients serum immune complexes and he suggested that immune complexes may play a role in the pathogenesis of the complications following intestinal bypass operation. Moake et al. (7) suggest that immune complex mediated complement activation account for the hemolysis in their patient.

The pathological changes of the skin lesions are various. Williams et al. (4) described nodular nonsuppurative panniculitis whereas according to Drenick et al. (3) the lesions were typical erythema nodosum which on microscopical examination showed nodular vasculitis. The papules and pustules described by Dicken & Sechafer (1) showed on skin biopsy subepidermal vesicle with mixed dermal infiltration of lymphocytes and polymorphonuclears. Goldman et al. (8) reported macular-papular rash in which biopsy showed leucocytoclastic vasculitis with cellular infiltration around small dermal blood vessels.

*Fig. 3.* Aggregate of activated platelets in the vicinity of blood vessel.  $\times 4200$ .

*Fig. 4.* Opening between endothelial cells and rupture of basal membrane (arrow).  $\times 6400$ .





Stein et al. (9) described 24 patients with cutaneous vasculitis out of 31 patients with jejunoileal bypass for obesity. Ely (5) described skin lesions similar to those found in acute febrile neutrophilic dermatosis of Sweet. Clegg et al. (10) reported a case of necrobiosis lipoidica that developed after bypass surgery and rapidly resolved after reanastomosis.

This variability in the histological findings raises the question whether a common cause was responsible for the skin lesions. In our case the histological changes were similar to leucocytoclastic vasculitis, with the presence of perivascular lymphocytes and polymorphonuclear infiltration and the presence of nuclear dust. However, no necrosis of the vascular wall, no deposition of P.A.S. Positive material was seen and the E.M. study showed normal endothelial cells and vascular basal membrane. However, the presence of clumps of activated platelets outside the blood vessels suggest severe damage to the vessel wall. The activated platelets were shown by the displacement of the granules to the central area and the degranulation (11). No deposits were seen on the basal membrane of the vessels. This finding does not exclude immune complex deposition there. Our findings confirm a report by Goldman et al. (8) describing leucocytoclastic vasculitis. We cannot subscribe to the pathogenesis of the skin lesions.

## REFERENCES

1. Dicken CH, Seehafer JR. Bowel bypass syndrome. *Arch Dermatol* 1979; 115: 837-839.
2. Shagrin JW, Frame B, Duncan H. Polyarthritis in obese patients with intestinal bypass. *Ann Intern Med* 1971; 75: 377-380.
3. Drenick EJ, Ament ME, Finegold SM et al. Bypass enteropathy: Intestinal and systemic manifestations following small bowel bypass. *JAMA* 1976; 236: 269-272.
4. Williams HJ, Samuelson CO, Zone JJ. Nodular non-suppurative panniculitis associated with jejunoileal bypass surgery. *Arch Dermatol* 1979; 115: 1091-1093.
5. Ely PH. The bowel bypass syndrome; a response to bacterial peptidoglycans. *J Am Acad Dermatol* 1980; 2: 473-487.
6. Utsinger PD. Systemic immune complex disease following intestinal bypass surgery: Bypass disease. *J Am Acad Dermatol* 1980; 2: 488-498.
7. Moake JL, Kageler WV, Cimo PL et al. Intravascular hemolysis, thrombocytopenia, leukopenia, and circulating immune complexes after jejunal ileal bypass surgery. *Ann Int Med* 1977; 86: 576-578.
8. Goldman JA, Casey HL, Davidson ED et al. Vasculitis associated with intestinal bypass surgery. *Arch Dermatol* 1979; 115: 725-727.
9. Stein HB, Schlappner OLA, Boyko W, Goulay RH, Reeve CE. The intestinal bypass arthritis dermatitis syndrome. *Arthritis Rheum* 1981; 24: 684-690.
10. Clegg DO, Zone JJ, Piepkorn MW. Necrobiosis lipoidica associated with jejunoileal bypass surgery. *Arch Dermatol* 1982; 118: 135-136.
11. White JG. Electron microscopic studies of platelet secretion. In: *Progress in hemostasis and thrombosis*. Vol. 2. Spaet TH, ed. New York: Grune & Stratton, 1974: 49-98.