

Incidence of Liver Disease in Chronic Lichen planus of the Mouth

H. MOBACKEN,¹ L.-Å. NILSSON,² R. OLSSON³ and K. SLOBERG⁴

Departments of ¹Dermatology, ²Clinical Immunology and ³Medicine II, Faculty of Medicine, and ⁴Department of Oral Surgery, Faculty of Odontology, University of Gothenburg, Sweden

Mobacken H, Nilsson L-Å, Olsson R, Sloberg K. Incidence of liver disease in chronic lichen planus of the mouth. *Acta Derm Venereol* (Stockh) 1984; 64: 70-73.

Fifty-four patients with oral lichen planus were screened for chronic inflammatory liver disease utilizing standard biochemical parameters of liver function. serum levels of immunoglobulins G, A and M and circulating autoantibodies against mitochondriae, smooth muscle and cell nuclei. One patient had primary biliary cirrhosis, and another had cryptogenic cirrhosis. This study did not confirm previous observations of a frequent association of oral lichen planus and primary biliary cirrhosis or chronic active hepatitis. *Key words: Lichen planus; Primary biliary cirrhosis; Chronic active hepatitis.* (Received June 22, 1983.)

H. Mobacken, Department of Dermatology, Sahlgren's Hospital, S-413 45 Gothenburg, Sweden.

The etiology of lichen planus (LP) is still unknown (4). An association between LP and common diseases like diabetes and hypertension has been suggested, but may be coincidental (2, 3). There are occasional case reports of LP associated with other diseases, e.g. lupus erythematosus, graft versus host-reactions (GVH), ulcerative colitis, myasthenia gravis and thymoma, and alopecia areata and vitiligo (1, 4, 8). One common denominator for the last mentioned conditions is the occurrence of immunologic aberrations, which may support the hypothesis of an autoimmune etiology of LP.

The coexistence of oral LP and chronic inflammatory liver disease has recently been reported (6, 7, 10). In one series, severe liver disease occurred in 5 of 7 consecutive patients with erosive LP (9). In addition, treatment of primary biliary cirrhosis (PBC) with

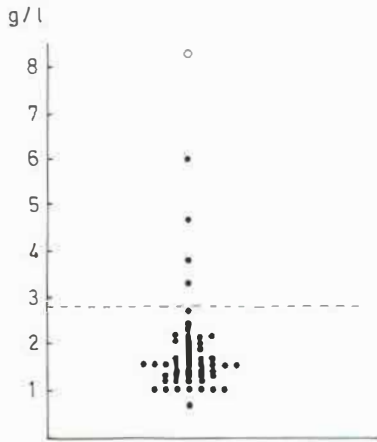


Fig. 1. Serum IgM concentrations in 54 patients with severe oral lichen ruber planus (0 = the patient with presymptomatic primary biliary cirrhosis). The dotted line shows the upper limit of the laboratory's reference value.

penicillamine seems to precipitate LP in a substantial number of such patients (7, 13). The concurrence of LP and PBC has led to speculations about a common pathogenetic mechanism. One may also question whether the occurrence of severe oral LP should promote a search for liver disease. In order to elucidate these questions we designed a prospective study in which 54 patients with chronic LP of the mouth were screened for occult liver disease.

PATIENTS AND METHODS

The study comprised 54 patients with oral LP who had been admitted to the Department of Oral Surgery because of burning and painful oral lesions refractory to conventional treatment with topical corticosteroids. There were 18 men and 36 women. Their mean age at the study was 59 years (range 34–78). The mean duration of LP was 6 years (range 0.5–26). The diagnosis of LP was based on the clinical and histological pictures. Direct immunofluorescence examination of the mucous membranes was performed in most cases to exclude lupus erythematosus and bullous dermatoses. Atrophic-erosive lesions were present in 38 patients and reticular-plaque lesions in 16. Skin lesions of LP occurred in 5 cases.

The patients were asked to answer in a questionnaire whether they had had jaundice, if they were operated for gall bladder disease or if they knew that they had suffered from any liver disease.

As screening tests for chronic inflammatory liver disease we measured serum levels of bilirubin, alkaline phosphatases (ALP), aspartate aminotransferase (ASAT) and alanine aminotransferase (ALAT) by standard laboratory methods. Immunoglobulins G, A and M (IgG, IgA, IgM) were determined by the single radial immunodiffusion method. Antinuclear antibodies (ANA), smooth muscle antibodies (SMA) and antimitochondrial antibodies (AMA) were determined by the indirect immunofluorescent technique as described earlier (12) using rat liver, kidney and stomach as substrates.

RESULTS

One patient reported jaundice during pregnancy. Ten women and two men had been operated on for gallstone diseases. Five women reported a regular intake of thyroxin.

Two women had biopsy-proven liver cirrhosis. One of these, a woman aged 68 years, had been operated on with a portocaval shunt in 1977. Her liver biopsy showed cirrhosis with low inflammatory activity, she had slightly elevated aminotransferases and bilirubin, normal ALP and immunoglobulins and negative tests for HB_sAg and autoantibodies. The cirrhosis was considered cryptogenic. The other woman, aged 57 years, had a biopsy-picture compatible with primary biliary cirrhosis with granulomas, marginally elevated

aminotransferases and ALP, markedly increased IgM, AMA positive 1/80 with negative tests for ANF and SMA.

In the other patients, the liver tests showed only minor aberrations from the normal. Thus, two women had marginally elevated ASAT and ALAT (0.85 and 0.76 $\mu\text{kat/l}$ respectively, normal <0.70), and two men had marginally elevated bilirubin (22.2 and 26.6 $\mu\text{mol/l}$ respectively, normal <21).

Five patients had moderately increased IgA levels. Two had markedly, and 3 had moderately increased IgM levels (Fig. 1). Agarose electrophoresis did not reveal any M components in these patients. Low levels of ANA and SMA were observed in 7 and 3 cases respectively. AMA was only detected in the patient with primary biliary cirrhosis. Of the patients with the slight abnormalities of liver tests only one (with ALAT 0.76) had a moderately increased IgM level (3.3 g/l) with a weakly positive ANA test (1:20).

DISCUSSION

Graham-Brown et al. reported five patients with both LP and PBC (6). The prevalence of this combination in their patients with PBC was however not mentioned. In the present study there was only one case with PBC out of 54 patients with oral LP. There were no remarkable clinical features of the oral LP lesions in this patient. Although it is true that PBC may often occur in a presymptomatic form, sometimes with normal liver tests (14), the characteristic hallmark of PBC, viz. the presence of AMA in the blood, was not shown in any of the other LP patients. Furthermore, the failure to detect AMA's in our other LP patients contradicts the supposition that the increased IgM levels observed in some of the patients would be a sign of PBC. The presence of presymptomatic PBC in our other patients therefore seems highly improbable.

Chronic active hepatitis, described in no less than 13.5% of 37 patients with non-erosive LP (10), was not diagnosed in any of our patients. Certainly, the cryptogenic cirrhosis in one of our patients could have been caused by a chronic active hepatitis but otherwise the existence of a chronic active hepatitis seems to have been excluded with reasonable certainty.

The present study did not confirm other observations that severe LP of the mouth is associated with a high prevalence of chronic inflammatory liver disease. An increased coexistence of chronic inflammatory liver disease and LP seems improbable also from the fact that LP was not reported in any of 280 patients with PBC followed for up to 19 years (11), and in only two patients with chronic liver disease, including 108 patients with active chronic hepatitis, 47 with primary biliary cirrhosis, and 63 with cryptogenic cirrhosis (5).

REFERENCES

1. Brenner W, Diem E, Gschnait F. Coincidence of vitiligo, alopecia areata, onychodystrophy, localized scleroderma and lichen planus. *Dermatologica* 1979; 159: 356-360.
2. Christensen E, Holmstrup P, Wiberg-Jørgensen F, Neumann-Jensen B, Pindborg JJ. Glucose tolerance in patients with oral lichen planus. *J Oral Pathol* 1977; 6: 143-151.
3. Christensen E, Holmstrup P, Wiberg-Jørgensen F, Neumann-Jensen B, Pindborg JJ. Arterial blood pressure in patients with oral lichen planus. *J Oral Pathol* 1977; 6: 139-142.
4. Fellner MJ. Lichen planus. *Int J Dermatol* 1980; 19: 71-75.
5. Golding PL, Smith M, Williams R. Multisystem involvement in chronic liver disease. Studies on the incidence and pathogenesis. *Am J Med* 1973; 55: 772-782.
6. Graham-Brown RAC, Sarkany I, Sherlock S. Lichen planus and primary biliary cirrhosis. *Br J Dermatol* 1982; 106: 699-703.
7. Powell FC, Rogers RS III, Dickson ER. Lichen planus, primary biliary cirrhosis and penicillamine. *Br J Dermatol* 1982; 107: 616.

8. Razzaque Ahmed A, Schreiber P, Abramovits W, Ostreicher M, Lowe NJ. Coexistence of lichen planus and systemic lupus erythematosus. *J Am Acad Dermatol* 1982; 7: 478-483.
9. Rebora A. Lichen planus and the liver. *Lancet* 1981; ii: 805-806.
10. Rebora A, Rongioletti F, Canepa A. Chronic active hepatitis and lichen planus. *Acta Derm Venereol (Stockh)* 1982; 62: 351-352.
11. Roll J, Boyer JL, Barry D, Klatskin G. The prognostic importance of clinical and histologic features in asymptomatic and symptomatic primary biliary cirrhosis. *N Engl J Med* 1983; 308: 1-7.
12. Rosén K, Mobacken H, Nilsson L-Å. Increased prevalence of antithyroid antibodies and thyroid diseases in pustulosis palmoplantaris. *Acta Derm Venereol (Stockh)* 1981; 61: 237-240.
13. Seehafer JR, Rogers RS III, Fleming CR, Dickson ER. Lichen planus-like lesions caused by penicillamine in primary biliary cirrhosis. *Arch Dermatol* 1981; 117: 140-142.
14. Triger DR. Primary biliary cirrhosis. *Br Med J* 1982; 284: 1898-1900.