

Occurrence of Epidermolysis bullosa in Finland

MATTI KERO

Department of Dermatology, Central Hospital of Kanta-Häme, Hämeenlinna 53, Finland

Kero M. Occurrence of epidermolysis bullosa in Finland. Acta Derm Venereol (Stockh) 1984; 64: 57-62.

Cases of epidermolysis bullosa (EB) were gathered from the hospital files of dermatological clinics and university pediatric clinics in Finland over a period of 10 years. 40 families were identified, containing 121 live sufferers from this condition, after which genealogical analysis revealed a further 55 patients. 11 out of the 17 subtypes of EB (1) were diagnosed in these families. The diseases found in two families were difficult to type according to the present classification, and were therefore handled separately. No regional accumulation was found and it seems that there is no type of EB which represents a peculiarly Finnish form. The most significant difference compared with the Norwegian material was the very much lower incidence of the recessive dystrophic subtype in Finland. *Key words: Subtypes; Regional distribution.* (Received April 5, 1983.)

M. Kero, Department of Dermatology, Central Hospital of Kanta-Häme, SF-13530 Hämeenlinna 53, Finland.

The term epidermolysis bullosa has become a common name for a mechanobullous symptom complex including many heterogeneous diseases (1, 2). It is believed at present to include about 11 genetic entities (3) and also an acquired type.

The classification of EB has been undergoing continual change. Current diagnostic methods enable the subtypes to be divided into three main forms: intra-epidermal, junctional and dermal (Table I).

Very little attention has been paid either to the epidemiology of EB as a whole or to that of the various subtypes, although one profound study on the subject has been carried out by Gedde-Dahl (4) in Norway. The aim of the present study was to obtain information on the occurrence of EB and its subtypes in Finland.

MATERIAL AND METHODS

Diagnostic criteria for EB

The following clinical criteria presented by Gedde-Dahl were used here, amplified by electron microscopy and immunohistological studies:

1. Blisters appearing in the skin periodically or continuously over the years.
2. Localization of blisters in areas usually exposed to pressure or trauma with bilateral involvement.
3. Size of blisters often exceeding 5 mm in diameter.
4. Absence of photosensitivity. Normal porphyrin levels in the urine and faeces in patients with the onset occurring after the age of ten.
5. Absence of infection or drug aetiology.
6. Other bullous diseases with a specific histology excluded by light microscopy.
7. Acquired cases with onset in adulthood give a positive direct immunofluorescence finding with IgG and C' in the basement membrane zone.
8. Typical electron microscopy findings.

Material

The probands were collected retrospectively from the files of the dermatological clinics of the central hospitals and the pediatric clinics of the university central hospitals in Finland covering the period 1970-81.

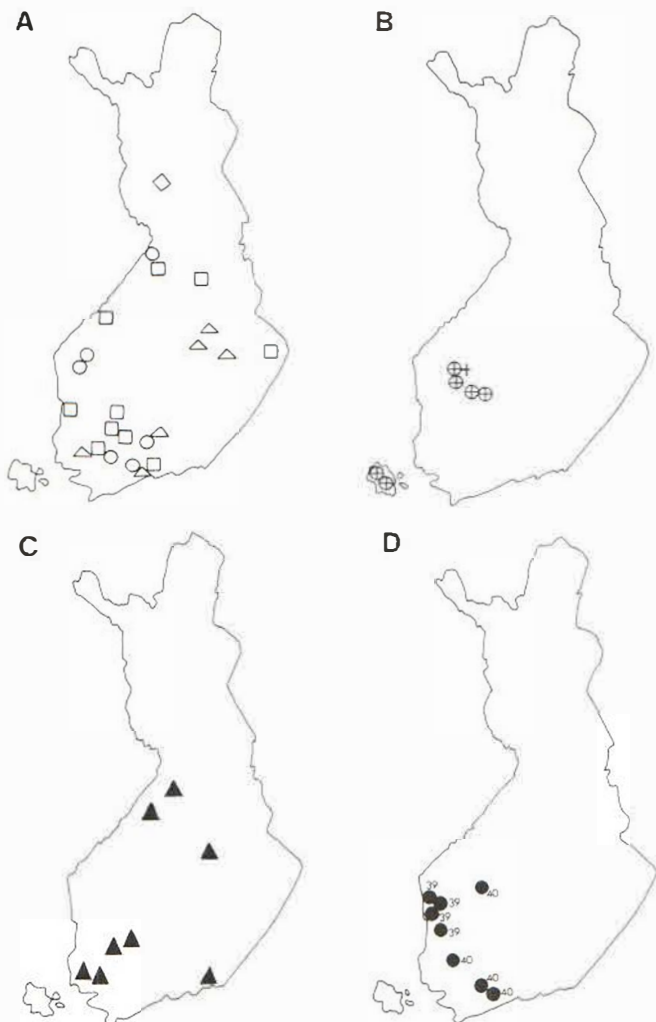


Fig. 1. (A) Birthplaces of probands with intra-epidermal EB types: □, D-EBS-Köbner; ○, D-EBS-Weber-Cockayne; △, D-EBH-Dowling-Meara; ◇, D-EB-Bart./ (B) Birthplaces of patients with R-EBA: ⊕, alive; +, dead. (C) Birthplaces of probands with D-EBD-CT and D-EBD-P. (D) Birthplaces of the grandparents of 2 R-EBD patients (FEB 39, 40).

Clinical examination

At least one proband from every family, with the exception of two families in both of which two children had died of the lethal R-EBA-GH during the first months of their lives, was examined by the author. In addition, one sporadic patient with well documented D-EBS-WC, who died of another disease at the age of 58 just before the proposed consultation, was included in the series.

The occurrence of the disease in the families of the probands was checked by means of interviews and questionnaires.

All the cases reported to have symptoms of EB were invited to a personal examination. Clinical status and genealogical family history were determined and, if possible, a biopsy was taken from a fresh blister. The families were numbered as Finnish EB (FEB 1, 2, 3, . . . 40) according to the system initiated by Gedde-Dahl.

The locations of the blisters, scars, milia and pigmentations were recorded, as were any nail deformities, the condition of the teeth, alopecia, hyperkeratosis of the hands and the soles of the feet, hyperhidrosis, and complaints regarding the eyes. The possibility of malignant tumours was also taken into consideration.

Genealogical studies

The families were checked back for 4–7 generations from parish registers and using information provided by the subjects. Pedigrees were drawn for those families with dominantly inherited EB.

while in the case of families with recessively inherited EB the aim of the genealogical analysis was to find evidence of consanguinity or common gene sources between the families.

Histological studies

32 probands were biopsied and specimens were taken for routine light microscopy (haematoxylin eosin) and electron microscopy. The latter specimens were fixed in 2.5% glutaraldehyde and postfixed with 1% osmium tetroxide and the grids stained with uranyl acetate and lead citrate. In 8 cases the levels of the blisters were determined by an indirect immunofluorescence method (5) using specific antibodies against collagens of types IV and V and the proteoglycan component of basement membrane.

RESULTS

The investigation revealed 40 EB families, involving 176 patients altogether, out of whom 121 were alive at the time of the study and 78 were examined personally. The areal distribution of the subtypes is seen in Fig. 1.

Intra-epidermal EB types

The blisters were intra-epidermal in 24 families. These contained 107 diseased members altogether, of whom 74 were alive at the time of study and 50 were examined personally. In one family (FEB 3) there was a possible linkage between D-ESB-K and a deficiency in galactosylhydroxylysyl glucosyltransferase (GGT), an enzyme involved in the synthesis of collagen (6). The distribution of the cases by subtype is presented in Table II.

Junctional types

Three families (FEB 2, 28 and 29) contained 14 children altogether, of whom 7 had EB of the type R-EBA-GH/mitis. Two children in family FEB 2, living in an isolated area of the Åland Islands had died of R-EBA-GH. The genealogical background of families 28 and 29 could be traced back to the same community in Southern Ostrobothnia, and the common

Table I. *Subtypes of epidermolysis bullosa*

Intra-epidermal forms

D-EBS-K	Dominant EB Simplex Köbner
D-EBS-WC	Dominant EB Simplex Weber-Cockayne
D-EBS-O	Dominant EB Simplex Ogna
D-EBS-mottled	Dominant EB Simplex Mottled
D-EBH-DM	Dominant EB Herpetiformis Dowling-Meara
D-EB-B	Dominant EB Bart

Junctional forms

R-EBA-GH	Recessive EB Atrophicans Gravis Herlitz
R-EBA-mitis	Recessive EB Atrophicans Mitis
R-EBA-L	Recessive EB Atrophicans Localizata
R-EBA-I	Recessive EB Atrophicans Inversa
R-EBP	Recessive EB Progressiva

Dermal forms

D-EBD-CT	Dominant EB Dystrophica Cockayne-Touraine
D-FBD-P	Dominant EB Dystrophica Pasini (albopapuloidea)
R-EBD-HS	Recessive EB Dystrophica Hallopeau-Siemens
R-EBD-I	Recessive EB Dystrophica Inversa
R-EBD-L	Recessive EB Dystrophica Localizata
A-EBD	Acquired EB Dystrophica

gene source seemed probable. Two children in each family had died of R-EBA-GH. A 20-year-old girl in family FEB 29 still had blistering, and also nail and teeth deformities. Hemidesmosome hypoplasia was seen in electron microscopy. Her disease was classified as R-EBA-mitis (7). The association between R-EBA-GH and intestinal malformations often quoted in the pediatric literature was found in one case in family FEB 29, in whom volvulus intestini was detected in obduction.

Dermal EB types

Eight families with 55 diseased members were classified into the dermal subtypes D-EBD-CT and D-EBD-P. 41 of these subjects were still alive, and 22 were examined personally. Only 3 cases in two families had the generalized disease D-EBD-P (albopapuloidea), while one family (FEB 32) contained cases of both limited D-EBD-CT and generalized D-EBD-P.

One female had the acquired form of the disease, beginning at the age of 38 in connection with her third parturition (8), 2 patients in families FEB 39 and 40 had R-EBD, representing different subtypes, and an 11-year-old girl had the inversa-type R-EBD-I and a 16-year-old boy had the mutilating type R-EBD-HS.

Unclassified cases

Classification proved difficult in the case of 3 patients in families FEB 24 and 30, in whom the blisters were found to be above the basement membrane and the hemidesmosomes were well developed. One patient was a 5-year old girl in whom the clinical features resembled those of EBA with destroyed teeth, alopecia, and anaemia; no exacerbation occurred in the warm season. The indirect immunofluorescence finding was nevertheless similar to that for EB simplex (5). The other 2 patients were a 34-year-old woman and her brother who had died at the age of 20. They both had the same syndrome, with a weakly scarring mechanobullous disease with muscle dystrophy (9), nail deformities and destroyed teeth.

DISCUSSION

The Norwegian material presented by Gedde-Dahl (4) in 1970 included 46 families, 53 probands and 124 certain or secondary cases, of whom 40 probands and 96 secondary cases were examined, and was thus fairly similar to the present Finnish series. There are some differences in the occurrence of the various subtypes, however. In Norway there were eight families and 4 sporadic cases with non-scarring EB types, whereas in Finland 24 non-scarring intra-epidermal families were found, seven represented by a sporadic case. The special Norwegian type D-EBS-0 presented by Gedde-Dahl has not been diagnosed in Finland.

Table II. *Distribution of 107 cases of intra-epidermal EB by subtype*

	Families	Cases	Cases alive
D-EBS-K	11	54	37
D-EBS-WC	6	40	28
D-EBS-O	—	—	—
D-EBH-DM	6	10	7
D-EBS-mottled	—	—	—
D-EB-B	1	3	2

Table III. Occurrence of EBA

Family	Dead	Healthy Siblings	Cases alive
FEB 2	2	1	-
FEB 28	2	1	-
FEB 29	2	5	1

Comparison of the dystrophic forms in these two series is more complicated due to different classifications used. Gedde-Dahl's classification used no ultrastructural criteria, and he included both atrophic junctional forms and dystrophic dermal forms within the same group. It can be seen, however, that the most significant difference is the major occurrence of R-EBD types in Norway. In 1979 Breit (10) reviewed the published R-EBD-I cases, 13 of these 16 being from Norway. In contrast, the less destructive D-EBD types were found to be more numerous in Finland. Gedde-Dahl reports a D-EBD-P family with 5 members and one sporadic D-EBD-CT case, whereas the Finnish series includes two D-EBD-P families and six D-EBD-CT families with 55 members altogether. Although the ascertainment probability is assumed to be low, the extensive material available from Central Europe (11) suggests that D-EBD-CT/CP is not a specific Finnish form.

In 1952 Böök (12) reported the mutation rate of EB dystrophica letalis in Sweden to be 5×10^{-5} . In the Norwegian material there were 7 lethal cases in six families. Since the ascertainment probability of R-EBA-GH is unknown in the Finnish material of three families with 6 lethal cases, there is no reason to calculate the exact mutation rate. Schnyder and Anto-Lamprecht (7) report 5 cases with R-EBA-mitis between 1976 and 1979. The single case within 10 years in Finland illustrates the rarity of this subtype. The present study showed no real concentration of EB cases, nor any subtype which could be considered a special Finnish form (Fig. 1).

Electron microscopy has assumed a decisive role in the classification of the subtypes of EB, especially for diagnosing the subtypes with specific structural defects, such as the R-EBA types with hemidesmosome hypoplasia (13) and D-EBH-DM with tonofilament clumping (14) in dystrophic forms with anchoring fibril defect (15, 16). The immunofluorescence technique with specific antibodies against components of basement membrane proved convenient for determining the depth of the blister (7). The structural, and in some types the biochemical backgrounds of blistering are better known in the junctional (13) and dermal types (15, 2) than in the intra-epidermal types, but it is to be expected that the pathogens of the intra-epidermal types will also emerge more clearly in the near future. Whether the GGT deficiency found in one D-EBS-K family (FEB 3) is an association or an aetiological factor is not entirely certain (6).

Because of the rarity of the subtypes, the acquisition of information on their characteris-

Table IV. Occurrence of dermal forms of EB

Type	Families	Cases	Cases alive
D-EBD-CT/P	8	55	41
A-EBD	1	1	1
R-EBD-HS	1	1	1
R-EBD-I	1	1	1

tics is very slow, as in D-EBH-DM, which was discovered in 1953 (17), whereas the tonofilament defect was identified as a pathomechanism for the first time 25 years later.

Since there were cases which could not be classified into the known types, it is probable that the classification is not yet final. The starting point for new types entails the mapping of the morphological features before any biochemical or ultrastructural defects can be identified. It is uncertain whether D-EB-B, for instance, is a type of its own, and aplasia cutis is a morphological feature on which more data should be collected before enough information is available for its nature to be determined.

A great deal of work has been done in the field of EB research in the Scandinavian countries, but there is still no common organization to promote collaboration between investigators and EB patients. Such organizations, known as D.E.B.R.A. (dystrophic epidermolysis bullosa research associations) have already been founded in Britain, Australia and the USA (18).

ACKNOWLEDGEMENTS

This work was supported by the Häme division of the Finnish Cultural Fund and Hoechst Fennica. The author is grateful to K-M Niemi, M.D. Ph.D. for electron microscopy studies.

REFERENCES

1. Gedde-Dahl T Jr. Sixteen types of epidermolysis bullosa. *Pediatric Dermatology. A symposium*, Skövde, March 1981. *Acta Derm Venereol (Stockh)* 1981; Suppl. 95: 74.
2. Pearson RW. Studies on the pathogenesis of epidermolysis bullosa. *J Invest Dermatol* 1962; 39: 551.
3. Gedde-Dahl T Jr. Classification of epidermolysis bullosa. In: *Pädiatrische Dermatologie* (Herzberg, JJ ed.) 1978; Stuttgart, New York: F. K. Schattauer Verlag, 1978; 65.
4. Gedde-Dahl T Jr. Epidermolysis bullosa. A clinical genetic and epidemiological study. Oslo, Bergen-Tromsø: Universitetsforlaget 1970. Baltimore: The Johns Hopkins Press, 1971.
5. Kero M, Peltonen L, Foidart JM, Savolainen E-R. Immunohistological localization of three basement membrane components in various forms of epidermolysis bullosa. *J Cutan Pathol* 1982; 9: 316.
6. Savolainen ER, Kero M, Pihlajaniemi T, Kivirikko KI. Deficiency of galactosylhydroxylysyl glucosyltransferase, an enzyme of collagen synthesis, in a family with dominant epidermolysis bullosa simplex. *N Engl J Med* 1981; 304: 197.
7. Schnyder UW, Anton-Lamprecht I. Zur Klinik der Epidermolysen mit junctionaler Blasenbildung. *Dermatologica* 1979; 159: 402.
8. Kero M, Niemi K-M, Kanerva L. Pregnancy as a trigger of epidermolysis bullosa acquisita. *Acta Derm Venereol (Stockh)* 1983; 63: 353-356.
9. Weerdt, CJ, Castelein S. Het voorkomen van epidermolysis bullosa hereditaria dystrophica en progressieve spier-dystrophie in één gezin. *Nd T Geneesk* 1972; 116: 1264.
10. Breit R. Epidermolysis bullosa dystrophica inversa. Übersicht und Bericht eines Falles. *Hautarzt* 1977; 30: 471.
11. Touraine MA. Classification des épidermolyses bulleuses. *Ann Dermatol Syph* 1942; 2: 309.
12. Böök JA. Fréquence de mutation de la chondrodystrophie et de l'épidermolyse bulleuse dans une population du sud de la Suède. *J Genet Hum* 1952; 1: 24.
13. Hashimoto I, Gedde-Dahl T Jr, Schnyder UW, Anton-Lamprecht I. Ultrastructural studies in epidermolysis bullosa hereditaria. IV. Recessive dystrophic types with junctional blistering (Infantile or Hertz-Pearson type and adult type). *Arch Dermatol Res* 1976; 257: 17.
14. Niemi K-M, Kero M, Kanerva L, Mattila R. Epidermolysis bullosa simplex. A new histological subgroup. *Arch Dermatol*. 1983; 119: 138-141.
15. Bauer EA. Abnormalities in collagenase expression as in vitro markers for recessive dystrophic epidermolysis bullosa. *J Invest Dermatol* 1982; 79: 105.
16. Briggaman RA, Wheeler CE. Epidermolysis bullosa dystrophica-recessive: a possible role of anchoring fibrils in the pathogenesis. *J Invest Dermatol* 1975; 65: 203.
17. Dowling GB, Meara RH. Epidermylisis bullosa resembling juvenile dermatitis herpetiformis. *Br J Dermatol* 1954; 66: 139.
18. Barclay WR. Epidermolysis Bullosa Research Association. *JAMA* 1981; 246: 2194.