

# Acute Febrile Neutrophilic Dermatitis with Genital Involvement

RUNE LINDSKOV

*Department of Dermatology, Gentofte Hospital, Hellerup, Denmark*

Lindskov R. Acute febrile neutrophilic dermatosis with genital involvement. *Acta Derm Venereol* (Stockh) 1984; 64: 559-561.

More than 80 cases of acute febrile neutrophilic dermatosis have been published since Sweet in 1964 described the syndrome. Besides skin eruptions, some patients have mucous membrane lesions involving mouth and lips. This report describes a patient with a pustular eruption consistent with Sweet's syndrome, who is believed to be the first with involvement of genital mucosa. *Key words: Sweet's syndrome; Pustular eruption; Genital lesions.* (Received May 16, 1984.)

R. Lindskov, Department of Dermatology, Gentofte Hospital, 65 Niels Andersensvej, DK-2900 Hellerup, Denmark.

In 1964 Sweet described a syndrome, which he called acute febrile neutrophilic dermatosis (ND), consisting of abrupt onset of tender, red cutaneous plaques often accompanied by fever, malaise and neutrophilic leucocytosis. Histological specimens contain dermal infiltrates of mature neutrophils and leucocytoclasia without vasculitis (1, 2). Since then more than 80 cases have been published. Besides skin eruptions, some patients have mucous membrane lesions involving mouth and lips (3).

This paper describes a patient with Sweet's syndrome, who is believed to be the first with involvement of genital mucosa.

## CASE REPORT

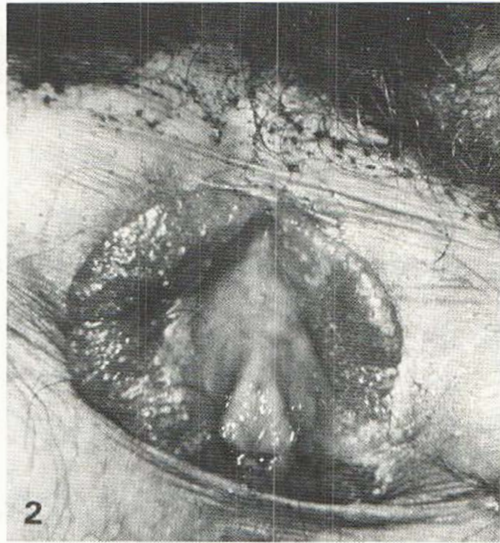
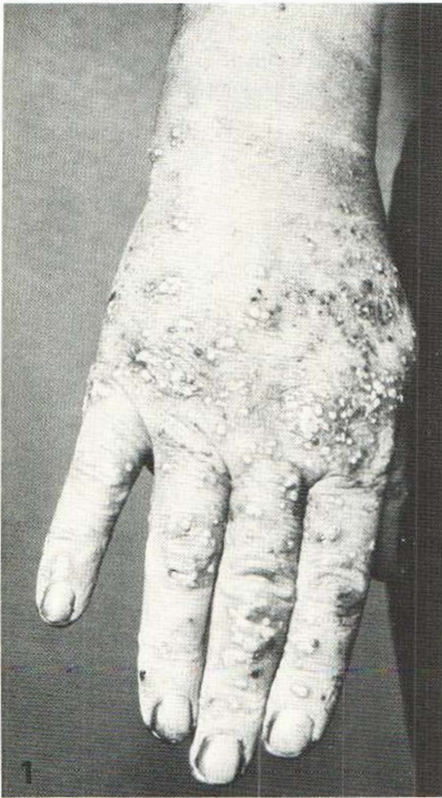
A 50-year-old woman was referred with a pustular eruption on the hands and feet of one week's duration. Furthermore the patient complained of pain from labia minores. One week before the skin eruption, the patient had suffered from a sore throat.

On examination pustules of varying size up to 4 mm were present on the dorsal and ventral aspects of the hands (Fig. 1). Most pustules were surrounded by a narrow ring of erythema and set upon normal skin. A few pustules were present on the forearms, calves and feet. The labia minores were swollen and red, and pustules were present (Fig. 2). The cutaneous and in particular the genital lesions were painful. The temperature at admission was 39°C.

Laboratory investigations included a sedimentation rate of 64-48 mm, white cell count of 20 500-19 900/mm<sup>3</sup> with 83-64% neutrophils, plasma fibrinogen 23.8 µmol/l (6-13) and C4 186 units (40-135). Urine showed traces of albumin and hemoglobin. Both albumin and hemoglobin disappeared on follow-up examinations. Chest X-ray showed an infiltrate in the lower right lobe. No endobronchial pathology was found on bronchoscopy. The infiltrate gradually diminished during follow-up examinations and was almost regressed after 6 weeks.

The following investigations were normal or negative: Hemoglobin, platelet count, creatinine, ANA, AST, ASH, alkaline phosphatase, repeated bacterial cultures from pustules (besides contaminants), blood culture, mycological and herpes simplex cultures from the pustules.

A skin biopsy from an evolving pustule demonstrated a dilated follicle filled with neutrophils in the dermis.



*Fig. 1.* Pustules on the dorsal aspect of the right hand.

*Fig. 2.* Swollen and erythematous labia minores studded with pustules.

Despite treatment with oral erythromycin and topical betamethasone/clioquinol cream new lesions continued to develop. Older lesions tended to coalesce and formed slightly infiltrated plaques. Four days after admittance the patient developed stomatitis. The temperature remained high. Besides tenderness of the lesions and shiverings the general health remained well.

A biopsy from a plaque showed focal parakeratosis and some exocytosis of neutrophils. In papillary dermis there was dilated vessels and perivascular infiltrates dominated by neutrophils. Lymphocytes, some eosinophils and nuclear dusts were also seen. There was no fibrinoid necrosis of the vessel walls.

A diagnosis of Sweet's syndrome was proposed and prednisolone therapy was started on the 5th day with a dose of 40 mg daily. Within 24 hours the patient was afebrile and lesions began to involute. When the dose was lowered to 20 mg relapse occurred. Potassium iodide 450 mg twice daily was added with no convincing effect. Combined therapy was continued and prednisolone was gradually tapered. The patient was discharged after 18 days. At the last examination after 8 weeks, red, well circumscribed macules persisted on the dorsum of the hands. A few milia had developed. The patient continued with prednisolone 12.5 mg daily.

## DISCUSSION

Pustules are sometimes described in ND, but they tend to develop surmounted on older lesions and not as a primary event (1). However, ND may present with a variety of skin lesions. Some are annular (4), others erythema nodosum like (5) or may simulate lupus erythematosus (6). The morphology in the present case may resemble that of pustular bacterid (7). However, in pustular bacterid, the pustules are subcorneal, whereas the abscess in the present case was found in the dermis. Furthermore vasculitis has been described in pustular bacterid (8). This was not found in the present case. Lack of true

vasculitis and dermal infiltrates dominated by neutrophils instead of lymphocytes makes a diagnosis of Behcet's syndrome less likely (9).

The histological findings, the presence of a prodrome, the results of laboratory investigations and the response to steroid treatment altogether point to the diagnosis of ND.

A child with Sweet's syndrome has been described, in whom a lung infiltrate resistant to antibiotic treatment, resolved after treatment with prednisone (4). Whether the lung infiltrate found in our patient represented a pulmonary involvement of ND remains purely speculative.

While stomatitis is found in about 25% of cases of ND associated with leukemia, it is rarely seen in ND without leukemia (3). It is believed, that this patient is the first case of ND with involvement of genital mucosa.

In conclusion it may be that the present case is part of a spectrum of acute febrile neutrophilic dermatosis with cutaneous lesions ranging from a few large plaques to a great number of pustules and with various forms of mucous membrane involvement.

## REFERENCES

1. Sweet RD. An acute febrile neutrophilic dermatosis. *Br J Dermatol* 1964; 76: 349-356.
2. Sweet RD. Further observations on acute febrile neutrophilic dermatosis. *Br J Dermatol* 1968; 80: 800-805.
3. Cooper PH, Innes DJ, Greer KE. Acute febrile neutrophilic dermatosis (Sweet's syndrome) and myeloproliferative disorders. *Cancer* 1983; 51: 1518-1526.
4. Levin DL, Esterly NB, Herman JJ, Boxall LBH. The Sweet syndrome in children. *J Pediatr* 1981; 99: 73-78.
5. Evans S, Evans CC. Acute febrile neutrophilic dermatosis. Two cases. *Dermatologica* 1971; 143: 153-159.
6. Frayha R, Matta M, Kurban A. Sweet's syndrome simulating systemic lupus erythematosus. *Dermatologica* 1972; 144: 321-324.
7. Andrews GC, Machacek GF. Pustular bacterids of hands and feet. *Arch Dermatol* 1935; 32: 837-847.
8. Tan RSH. Acute generalized pustular bacterid—an unusual manifestation of leukocytoclastic vasculitis. *Br J Dermatol* 1974; 91: 209-215.
9. James DG. Behcet's syndrome. *N Eng J Med* 1979; 301: 431-432.