

Phagocytosis by Mast Cells in Urticaria pigmentosa

PER GÖRAN KRÜGER¹ and ALLAN NYFORS²

¹Institute of Anatomy, PKI, Årstadveien 19, 5000 Bergen and ²Department of Dermatology, Haukeland sykehus, University of Bergen, 5016 Bergen, Norway

Krüger PG, Nyfors A. Phagocytosis by mast cells in urticaria pigmentosa. *Acta Derm Venereol (Stockh)* 1984; 64: 373-377.

Mast cells with endocytic and autophagic vacuoles were observed in a biopsy from a lesion of urticaria pigmentosa. In several areas of the specimen the mast cells revealed the typical morphology of mast cells which have released low molecular weight mediators, but this phenomenon did not seem to be correlated morphologically to the phagocytic activity of the mast cells. Some mast cells contained giant granules with a normal as well as an abnormal substructure. (Received January 16, 1984.)

P. G. Krüger, Institute of Anatomy, PKI, University of Bergen, Årstadveien 19, 5000 Bergen, Norway.

Since the observation of Padawer & Fruhman (1) that rat mast cells may engulf zymosan particles *in vivo* the rat peritoneal mast cell has been classified among cells with a certain phagocytic capacity (2, 3, 4, 5, 6, 7). So far, however, the observations on phagocytosis by mast cells have been restricted to the rat mast cell. In examining skin biopsies from a patient with urticaria pigmentosa, mast cells containing phagocytic inclusions were observed.

PATIENT, MATERIALS AND METHODS

Over a period of 2 years a 31-year-old male had developed widespread brown maculopapules, 2 to 4 mm in diameter, diagnosed as urticaria pigmentosa. Two 3 mm punch biopsies were taken of maculopapules after subcutaneous xylocain anesthesia in the upper part of the scapular region. The biopsies were immediately fixed at room temperature in 2% glutaraldehyde in 0.1 N cacodylate buffer (pH 7.4) to which was added 0.1 mM CaCl₂. Postfixation was performed in 1% OsO₄ in the same buffer. The specimens were dehydrated in graded ethanol and propyleneoxid and embedded in Epon-Agar. The specimens were sectioned into semithin and ultrathin sections using glass knives or a diamond knife. Semithin sections were stained in 0.1% toluidine blue and viewed in a Leitz light microscope. The ultrathin sections were contrasted in uranylacetate and lead citrate and viewed in a Phillips EM 300 electron microscope.

RESULTS

Mast cells were plentiful in most parts of the dermis except for the uppermost part of stratum papillare. Most of the mast cells had a normal ultrastructure with a few mitochondria, occasionally a centriole, some endoplasmic reticulum and a variable amount of microvilli (microridges). The mast cell granules varied in structure. Normal electron-dense granules with a crystalline-like, filamentous or scroll-like substructure were frequently observed. In a great proportion of the mast cells, however, granules with a central dense core or peripheral dense granular material alternated with an electron-lucid filamentous or particulated material (Figs. 1, 2 and 3).

In several mast cells giant granules were observed. They seemed to be granular aggregates with a particulated substructure (Fig. 2*a*), although some of these giant granules had a lamellated or scroll-like substructure (Fig. 2*b*). In some areas of the specimen, most mast cells possessed altered granules in cellular vacuoles (Fig. 3). In one

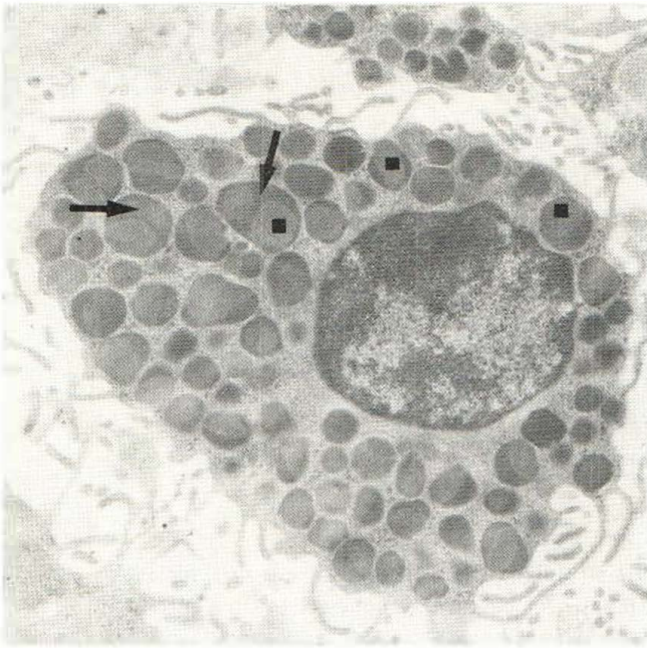


Fig. 1. The mast cells have granules with peripheral areas showing dense granular material (→) alternating with electron lucid material (■). $\times 10\,260$.

of the biopsies phagocytic vacuoles were observed within a minority of the mast cells. The content of the vacuoles could be identified as remnants of granular cells (Figs. 4 and 6). Within some of the phagocytic vacuoles remnants of mast cells could be observed (Figs. 4 and 5). In a few instances the vacuoles contained highly decomposed remnants of cells (Fig. 6*b*).

DISCUSSION

Mast cells with endocytic as well as autophagic vacuoles were observed in one of two biopsies taken from a patient with urticaria pigmentosa. Phagocytosis has not been reported in other studies on urticaria pigmentosa (8, 9). Phagocytic activity of mast cells

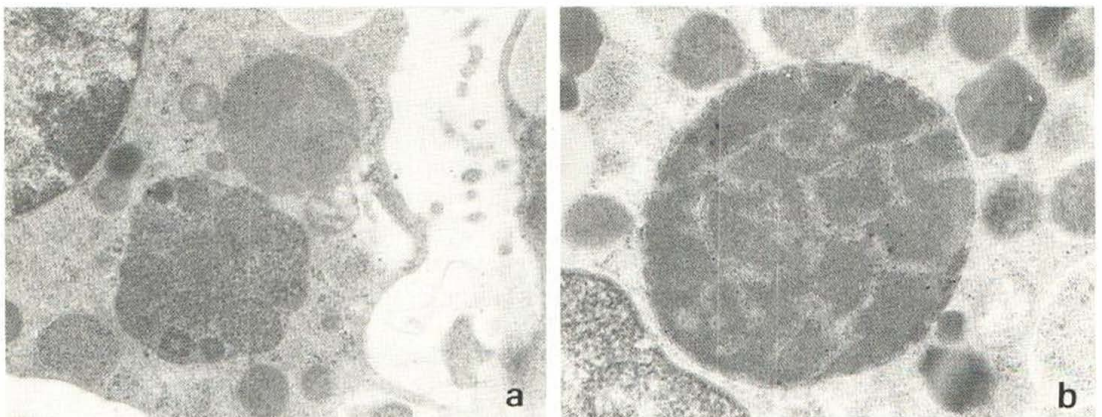


Fig. 2. Giant mast cell granules with a particulated or a lamellated substructure. $\times 16\,000$.

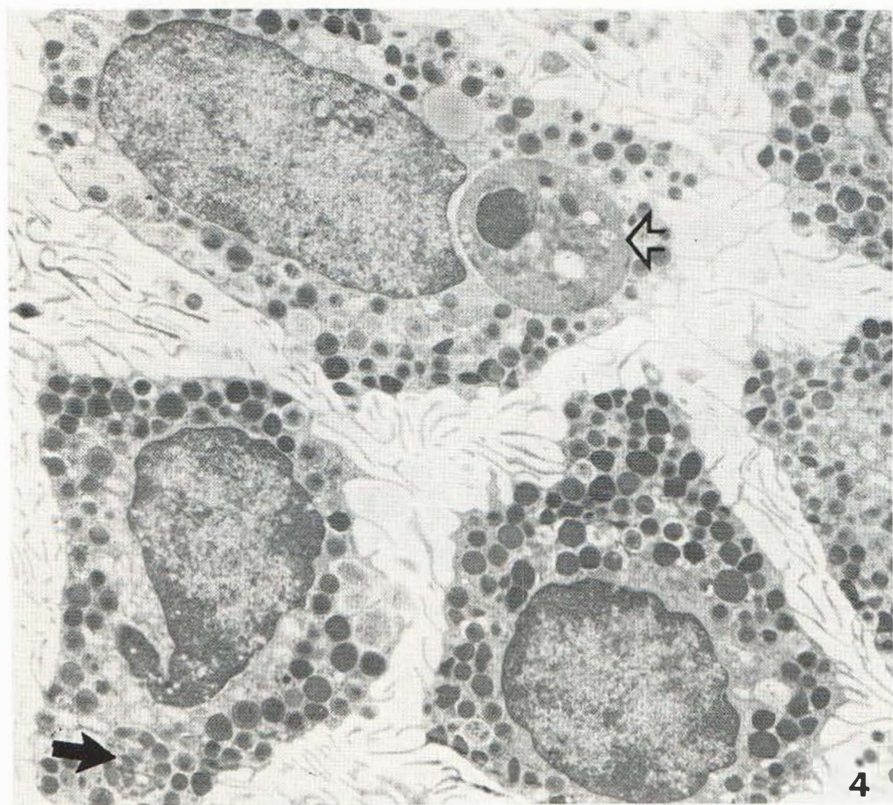
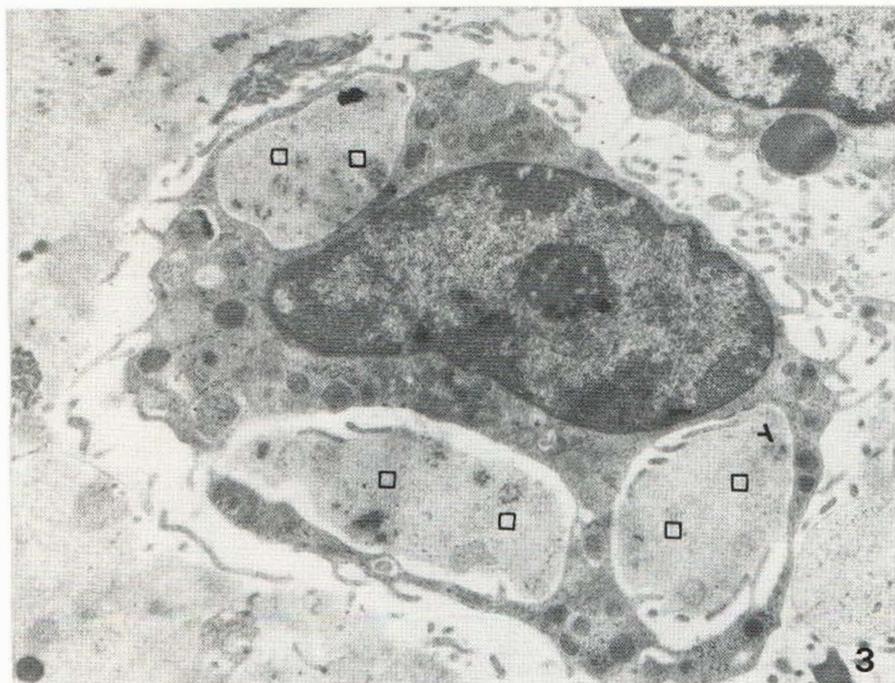

Fig. 3. Mast cell with altered granules within intracellular vacuoles (□). $\times 9120$.

Fig. 4. Mast cells with endocytic (⇒) as well as autophagic (→) vacuoles containing remnants of granular cells. $\times 6384$.

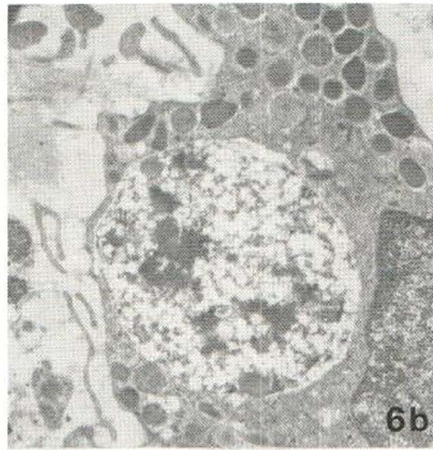
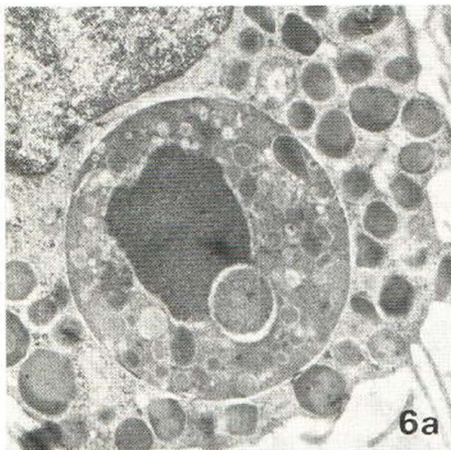
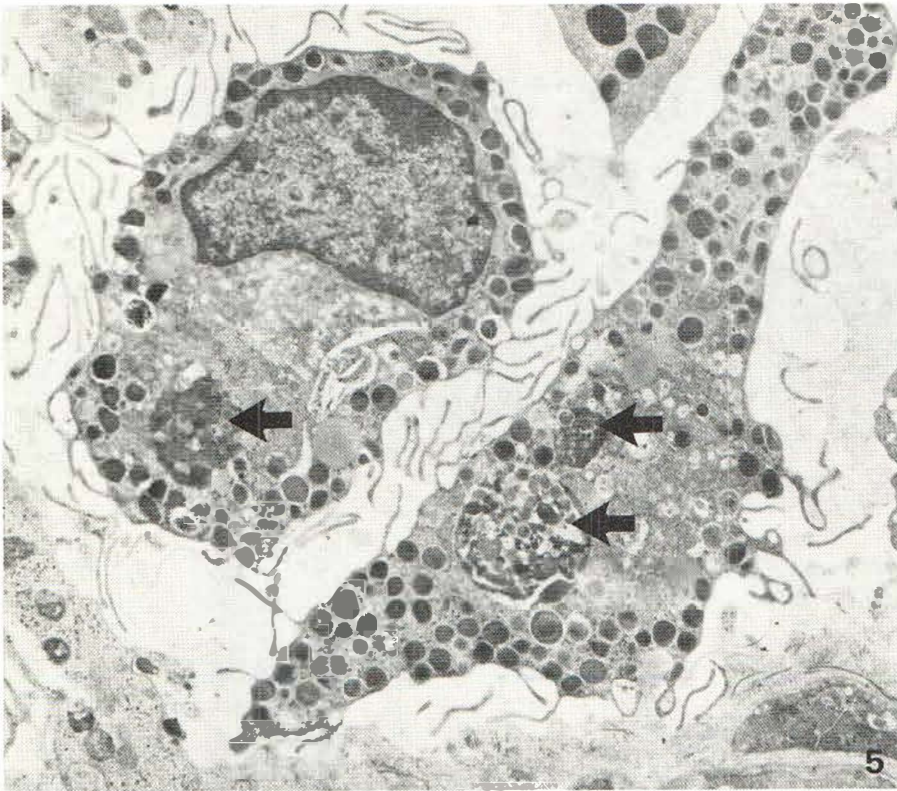


Fig. 5. Mast cells with phagocytic vacuoles containing remnants of mast cells (probably autophagic vacuoles) (→). $\times 6384$.

Fig. 6. Endocytic vacuoles with remnants of a granular cell (a) and a highly decomposed cell (b). (a) $\times 11172$, (b) $\times 10260$.

may not be linked to urticaria pigmentosa. In three biopsies from another patient (33-year-old male) with the same disease, no mast cells were observed with phagocytic vacuoles (unpublished results). Some of the phagocytic vacuoles observed were probably autophagic, as in the cells with remnants of mast cells (Figs. 4 and 5).

It has been reported that rat mast cells release mediators such as histamine, β -glucuronidase and an eosinophilic chemotactic factor during phagocytosis (6). In the present investigation, a majority of the mast cells in certain areas had morphological signs of mediator release: altered granules within cellular vacuoles (10, 11, 12, 13). This confirms observations by others that mast cells in urticaria pigmentosa can regularly release mediators (8). It seems, however, that the release of mediators is not linked to phagocytosis, since there was no correlation between mediator release as observed morphologically and the mast cell content of phagocytic vacuoles in this patient. This is in agreement with the opinion of others that phagocytosis by mast cells in rats is not associated with the release of low molecular weight mediators from the cells (5).

An observation of giant granules in mast cells from a patient with urticaria pigmentosa has been reported and the giant granules had an atypical morphology (9). In the present patient, the same type of giant granules were observed, representing fusions of mast cell granules with particulated substructure. Although most of the giant granules observed were of this atypical morphology, some of them had a lamellated substructure which has been described as typical of human mast cell granules (14).

ACKNOWLEDGEMENTS

We thank Birgit Nyfors, M.D., for referring the patient and Berit Hausvik for skilful assistance.

REFERENCES

1. Padawer J, Fruhman GJ. Phagocytosis of zymosan particles by mast cells. *Experientia* 1968; 24: 471-472.
2. Spicer SS, Simson JAV, Farrington JE. Mast cell phagocytosis of red blood cells. *Am J Pathol* 1975; 80: 481-498.
3. Padawer J. Phagocytosis of particulate substances by mast cells. *Lab Invest* 1971; 25: 320-330.
4. Sher A, Hein A, Moser G, Caulfield JP. Complement receptors promote the phagocytosis of bacteria by rat peritoneal mast cells. *Lab Invest* 1979; 41: 490-499.
5. Vranian G, Conrad DH, Ruddy S. Specificity of C3 receptors that mediate phagocytosis by rat peritoneal mast cells. *J Immunol* 1981; 126: 2302-2306.
6. Czarnetzki BM. Release of mediators from purified rat mast cells during phagocytosis. *Scand J Immunol* 1982; 15: 581-586.
7. Otani I, Conrad DH, Carlo JR, Segal DM, Ruddy S. Phagocytosis by rat peritoneal mast cells: Independence of IgG Fc-mediated and C3-mediated signals. *J Immunol* 1982; 129: 2109-2112.
8. Hashimoto K, Gross BG, Lever WF. An electron microscopic study of the degranulation of mast cell granules in urticaria pigmentosa. *J Invest Dermatol* 1966; 46: 139-149.
9. James MP, Eady RA. Familial urticaria pigmentosa with giant mast cell granules. *Acta Derm Venereol (Stockh)* 1981; 117: 713-718.
10. Bloom GD, Larsson B, Smith DE. The reaction of peritoneal mast cells in the rat for various activators. *Acta Pathol Microbiol Scand A* 1957; 40: 309-314.
11. Bloom GD, Fredholm B, Haegermark Ø. Studies in the time course of histamine release and morphological changes induced by histamine liberators in rat peritoneal mast cells. *Acta Physiol Scand* 1967; 71: 270-282.
12. Röhlich P, Anderson P, Uvnäs B. Mast cell degranulation as a process of sequential exocytosis. *Acta Biol Sci Hung* 1971; 22: 197-213.
13. Krüger PG, Bloom GD. Granule alteration and vacuole formation, two primary structural features of the histamine release process in mast cells. *Experientia* 1973; 29: 329-33.
14. Bloom GD. Structural and biochemical characteristics of mast cells. In: *The inflammatory process*. 2nd ed. (Zweifach BW, Grant L, McCluskey RT, ed.). Academic Press, New York, 1974; 1: 545-599.