

Mondor's Phlebitis of the Penis: A study with Factor VIII Related Antigen

TSUKASA TANII, TOSHIO HAMADA, YOSHIE ASAI
and TOKIKO YORIFUJI

*Department of Dermatology, Osaka City University Medical School,
Osaka, Japan*

Tanii T, Hamada T, Asai Y, Yorifuji T. Mondor's phlebitis of the penis: a study with factor VIII related antigen. *Acta Derm Venereol (Stockh)* 1984; 64: 337-340.

Four patients with so-called non-venereal sclerosing lymphangitis of the penis are reported. It was suggested that the affected vessels were veins by positively stained factor VIII related antigen with the unlabeled peroxidase-antiperoxidase method. If cord-like linear subcutaneous swelling observed in the coronary sulcus or dorsal region of the penile shaft originate from the vein, it seems correct to call this disease as Mondor's phlebitis of the penis. *Key words: Non-venereal sclerosing lymphangitis of the penis; Factor VIII related antigen; PAP method; Mondor's phlebitis of the penis.* (Received November 16, 1983.)

T. Tanii, Department of Dermatology, Osaka City University Medical School, 1-5-7, Asahimachi, Abeno-ku, Osaka 545, Japan.

Cord-like subcutaneous swelling of the penis usually reported as non-venereal sclerosing lymphangitis of the penis (NSLP) are based on the theory that the affected vessels are lymphatic vessels (4, 5, 6). However, there are reports regarding this disease as originate from the vein (1, 2, 3), and the conclusion is not obtained yet. In the present study of four cases of so-called NSLP, the affected vessels were investigated by staining factor VIII related antigen (FVIII-RAG) as a vascular endothelial marker, and the results suggested the vascular origin.

MATERIALS AND METHODS

In four cases of NSLP, hematoxylin-eosin staining, Weigert staining and Azan-Mallory staining of cross sections of cord-like lesions were performed. And immunohistochemical staining for F VIII-RAG with unlabelled-peroxidase-antiperoxidase method (PAP method) were carried out as a endothelial marker of blood vessel.

The clinical features of the four cases were as follows: Case 1, a 22-year-old married man presented with a cord-like lesion of two weeks' duration running straightly on the back of the penile shaft accompanied by edematous swelling of the prepuce (Fig. 1). Case 2, a 21-year-old unmarried man presented with a cord-like lesion of three weeks' duration running around coronary sulcus. Case 3, a 36-year-old married man presented with a worm-like lesion on the coronary sulcus occurring four months before. Case 4, a 39-year-old married man also had a worm-like lesion on the back of the penile shaft occurring several weeks before.

PAP method was performed after the modified method of Sternberger et al. (7). Sections were deparaffined in xylene, placed in absolute and 95% alcohol, then sequentially incubated for 10, 5, 20, 120, 20, 20, 20 min with each of the following reagents: 1) 0.1% protease type VII (SIGMA), at 37°C; 2) 3% hydrogen peroxide, at room temperature; 3) normal swine serum prediluted in 0.05 M Tris buffer, pH 7.6, at room temperature; 4) rabbit anti-human FVIII-RAG antiserum prediluted in 0.05 M Tris buffer, pH 7.6, at room temperature; 5) swine anti-rabbit immunoglobulin prediluted in 0.05 M Tris buffer, pH 7.6, at room temperature; 6) PAP (soluble horseradish peroxidase-antihorseradish peroxidase complex) prediluted in 0.05 M Tris buffer, pH 7.6, at room temperature; 7) the substrate solution: mixture of 3-amino-9-ethylcarbazole and 0.3% hydrogen peroxidase in 0.1 M acetatebuffer, pH 5.2, at 37°C. After each incubation, except for normal swine serum, slides were rinsed and bathed with Tris buffer pH 7.6. After incubation with the substrate solution, they were rinsed with water, counterstained with Mayer's hematoxylin, rinsed with water, dipped ten times in ammonia water, and rinsed with and mounted in glycerol gelatin. All reagents from 2) to 7) were purchased from DAKO Corporation (a subsidiary of Dakopatts A/S of Copenhagen, Denmark). Santa Barbara, USA, as 'DAKO PAP KIT 518'. For a control study, separate slides from every four cases were stained in the same manner with 120 min incubation with Tris buffer, pH 7.6 instead of with primary antibodies.

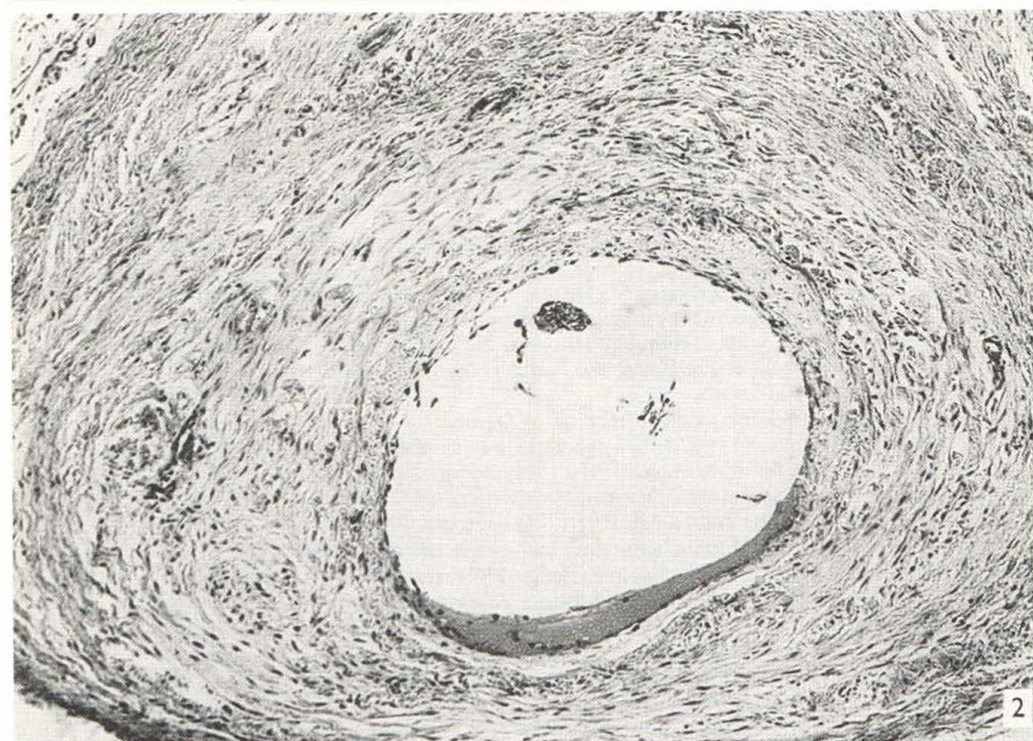
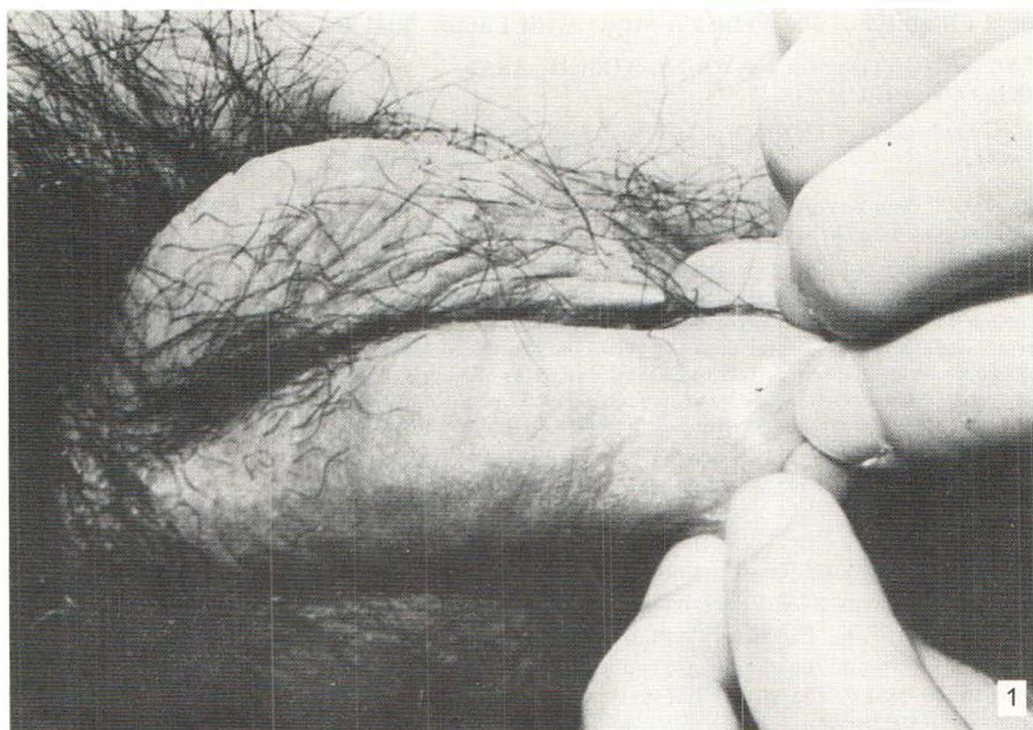


Fig. 1. Case 1, linear cord-like lesion on the back of the penile shaft.

Fig. 2. Case 1, dilated vessel with fibrous wall. Hematoxylin-eosin, $\times 100$.

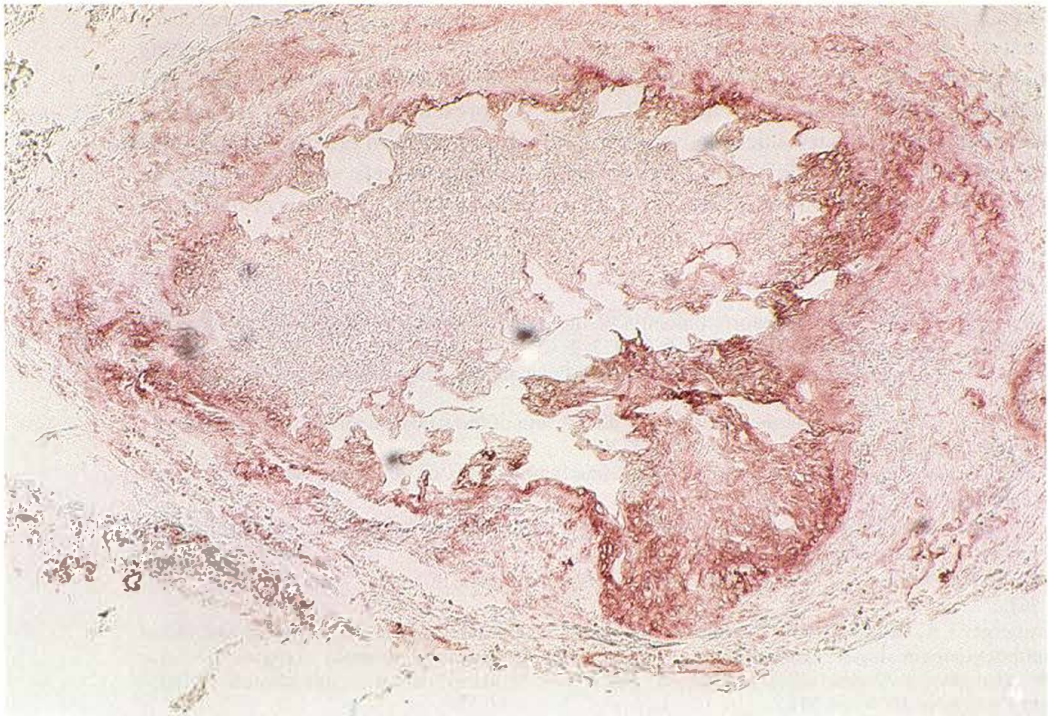
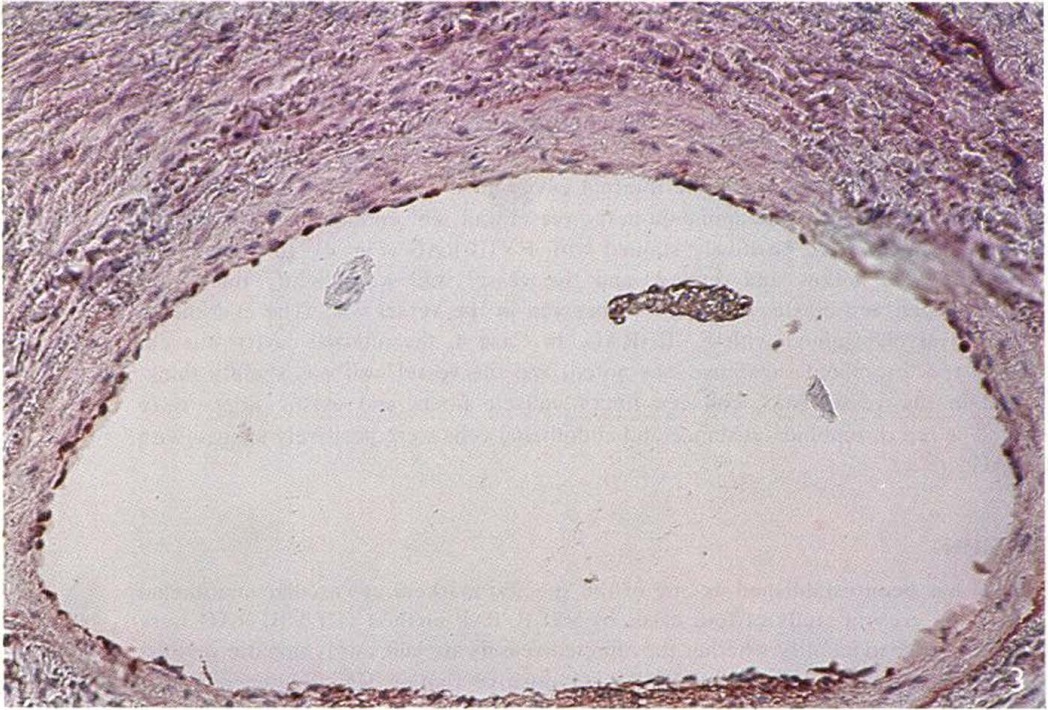

Fig. 3. Case 1, positive staining of endothelial cells lying on the luminal side. F VIII-RAG-PAP, counterstain hematoxylin, $\times 200$.

Fig. 4. Case 2, positive staining of endothelial cells grown on the internal cavity. F VIII-RAG-PAP, counterstain hematoxylin, $\times 125$.

RESULTS

The endothelial cells of blood vessel in all four cases were positively stained with F VIII-RAG. In the hematoxylin-eosin staining of Case 1, dilated vessel with thickened fibrous wall were noted (Fig. 2), and endothelial cells lying on the luminal side were positively stained with F VIII-RAG (Fig. 3). In the hematoxylin-eosin staining of Case 2, revealed a thickened fibrous vessel wall with the internal cavity in the process of recanalization. Collagen and muscle fibers were abundant in the vessel wall. The endothelial cells growing in the internal cavity were positively stained with F VIII-RAG (Fig. 4). In Case 3, the internal cavity was hollow and dilated, and the vessel wall was slightly thickened. Abundant collagen and elastic fibers were observed in the vessel wall. The endothelial cells were positively stained with F VIII-RAG. In Case 4, the internal cavity was extended, and red thromboid substance was noted, and the vessel wall was slightly thickened. And in the vessel wall, collagen fibers, muscle fibers and elastic fibers were abundant. The red thromboid substance and endothelial cells were positively stained with F VIII-RAG.

DISCUSSION

F VIII-RAG has been established as one of the specific markers of vascular endothelial cells (8). In the present study of four cases of NSLP, PAP method of F VIII-RAG were carried out in order to identify whether the affected vessels are veins or lymphatic vessels. As a result, in all cases, obvious F VIII-RAG positive finding were obtained in the endothelial cells of the vessels or in the endothelial cells of recanalized vessels. This fact seem to suggest that the affected vessels in all four cases were veins. Many of the cases previously reported to be caused by lymphatic vessels had the cord-like lesion running around the coronary sulcus (4, 5, 6), while lesions running on the back of the penile shaft were reported to be caused by veins (1, 2, 3). In the presented cases, the lesion was circular around the coronary sulcus in one case, and were running on the back of the penis in three cases. Since the origination from the veins in these vessels was suggested, the term of NSLP is not proper, and it seems correct to call as Mondor's phlebitis of the penis.

REFERENCES

1. Findlay GH, Whiting DA. Mondor's phlebitis of the penis: a condition miscalled 'non-venereal sclerosing lymphangitis'. *Clin Exp Dermatol* 1977; 2: 65.
2. Harrow BR, Slone JA. Thrombophlebitis of superficial penile and scrotal veins. *J Urol* 1963; 89: 841.
3. Helm JD, Jr, Hodge IG. Thrombophlebitis of a dorsal vein of the penis: report of a case treated by phenylbutazone (butazolidine). *J Urol* 1958; 7: 306.
4. Kandil E, Al-Kashlam IM. Non-venereal sclerosing lymphangitis of the penis. *Acta Derm Venereol (Stockh)* 1970; 50: 309.
5. Marsch W Ch, Stüttgen G. Sclerosing lymphangitis of the penis: a lymphangiofibrosis thrombotica occlusiva. *Br J Dermatol* 1981; 104: 678.
6. Nickel WR, Plumb RT. Nonvenereal sclerosing lymphangitis of penis. *Arch Dermatol* 1962; 86: 761.
7. Sternberger LA, Hardy PH, Jr, Cuculis JJ, Mejer HG. The unlabelled antibody enzyme method of immunocytochemistry. Preparation and properties of soluble antigen-antibody complex (horseradish peroxidase-antihorseradish peroxidase) and its use in identification of spirochetes. *J Histochem Cytochem* 1970; 18: 315.
8. Mukai K, Rosai J, Burgdorf WHC. Localization of factor VIII-related antigen in vascular endothelial cells using an immunoperoxidase method. *Am J Surg Pathol* 1980; 4: 273.