

## **Prochlorperazine—an Unusual Cause of Lip Ulceration**

G. D. REILLY and M. L. WOOD

*Rupert Hallam Department of Dermatology, Royal Hallamshire Hospital,  
Glossop Road, Sheffield, England*

Reilly GD, Wood ML. Prochlorperazine—an unusual cause of lip ulceration. *Acta Dermato Venereol* (Stockh) 1984; 64: 270-271.

A case is reported of a fixed drug eruption due to Prochlorperazine maleate which caused ulceration of the lower lip confirmed by a positive provocation test. (Received November 19, 1983.)

G. D. Reilly, Rupert Hallam Department of Dermatology, Royal Hallamshire Hospital, Glossop Road, Sheffield S10 2JF, England.

### **CASE REPORT**

A 75-year-old housewife attended the Dermatology Out-patient Clinic complaining of an ulcer on the lower lip which had developed over a period of three months. She described the lesion starting as a blister which became ulcerated and originally improving with the use of Triamcinolone oral paste. Since then the ulcer had persisted and was asymptomatic apart from occasional bleeding.

She had been prescribed Prochlorperazine maleate tablets 5 mg three times a day for dizzy spells and she had taken these intermittently over the past 12 years. Prior to presentation she had been taking them regularly for six months. She was a non-smoker, on no other medication and her general health was otherwise good.

On examination she had a small ulcer affecting the red margin of the lower lip with no extension onto the oral mucosa and no associated lymphadenopathy. General examination was unremarkable. She was given a further course of Triamcinolone which resulted in little improvement and on her own initiative she stopped taking Prochlorperazine.

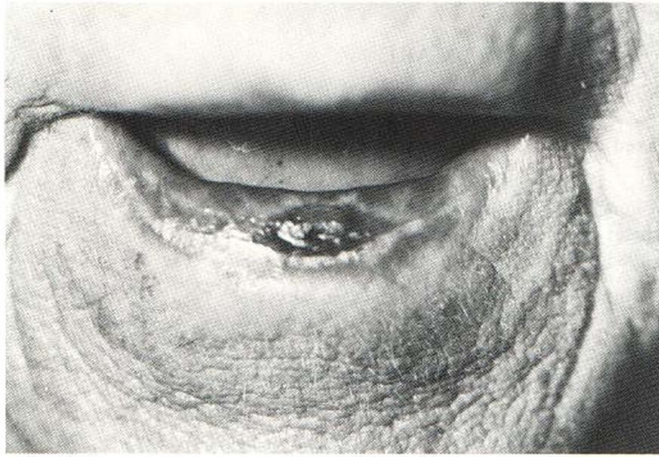


Fig. 1

On re-attending the clinic three weeks later the lesion had healed. This was thought to be the result of discontinuing Prochlorperazine and thus an attempt was made to confirm this by means of a provocation test. She was re-started on Prochlorperazine at a dose of 5 mg three times a day and when seen in the clinic three weeks later her condition had recurred. Her lip had re-ulcerated after three days of therapy (Fig. 1). She then stopped the medication and when finally reviewed again in three weeks her lip had completely healed.

## DISCUSSION

The term fixed drug eruption was first used by Brocq in 1894 to describe a special type of reaction to Phenazone. It is now known that there are many drugs which are capable of producing similar reactions. The commonest causes have been found to be due to barbiturates, phenophthalein, oxyphenbutazone, tetracyclines, chlordiazepoxide and acetyl salicylate (1). Lesions are more frequent on the limbs than the trunk and the hands and glans penis are commonly affected. A recent review of fixed drug eruptions has shown that amongst 30 reported cases only two patients had involvement of the lips (2).

There have been no previous reports of Prochlorperazine maleate causing fixed drug eruptions and there is little structural similarity between the phenothiazine and the other drugs which have been reported.

## ACKNOWLEDGEMENT

We would like to thank Dr R. E. Church for his permission to publish this case.

## REFERENCES

1. Savin JA. Current causes of Fixed Drug Eruptions. *Br J Dermatol* 1970; 83: 546.
2. Shukla SR. Drugs causing Fixed Drug Eruptions. *Dermatologica* 1981; 163: 160-163.