

Clinical and Scanning Electron Microscopic Findings in a Solitary Case of Trichorhinophalangeal Syndrome Type I

E. P. PRENS,¹ J. D. R. PEEREBOOM-WYNIA,¹ W. C. DE BRUYN,²
TH. VAN JOOST¹ and E. STOLZ¹

¹*Department of Dermatology and Venereology, University Hospital Rotterdam Dijkzigt- Erasmus University and* ²*Department of Pathology I, Erasmus University, Rotterdam, The Netherlands*

Prens EP, Peereboom-Wynia JDR, de Bruyn WC, van Joost Th, Stolz E. Clinical and scanning electron microscopic findings in a solitary case of trichorhinophalangeal syndrome type I. *Acta Derm Venereol* (Stockh) 1984; 64: 249-253.

A solitary case of Trichorhinophalangeal syndrome type I is described. Scanning electron microscopic examination revealed alterations of the cuticular pattern and hair shaft structure. These alterations have not been previously described and differ from those seen in other syndromes belonging to the group of the ectodermal dysplasias e.g. the Trichoonnyctic Hidrotic ectodermal dysplasia, autosomal recessive Anhidrotic ectodermal dysplasia and X-linked Anhidrotic ectodermal dysplasia. *Key words: Alopecia; Ectodermal dysplasia; Genetics; Hair; Hypotrichosis.* (Received October 29, 1983.)

E. P. Prens, Department of Dermatology and Venereology, University Hospital Rotterdam-Dijkzigt, Erasmus University, Dr. Molewaterplein 40, 3015 GD Rotterdam, The Netherlands.

The Trichorhinophalangeal syndrome (TRP) type I is characterized by sparse, fine slow-growing hair, a bulbous 'pear-shaped' nose with a long philtrum, a certain degree of dwarfism and short fingers deviated at one or more interphalangeal joints, showing 'cone shaped' epiphyses on X-ray examination. Other associated symptoms are: thin lateral eyebrows, lumbar scoliosis or lordosis, small supernumerary teeth, 'Perthes-like' alterations of the femoral heads (1, 2, 3, 4). This syndrome was given its name by Giedion, who

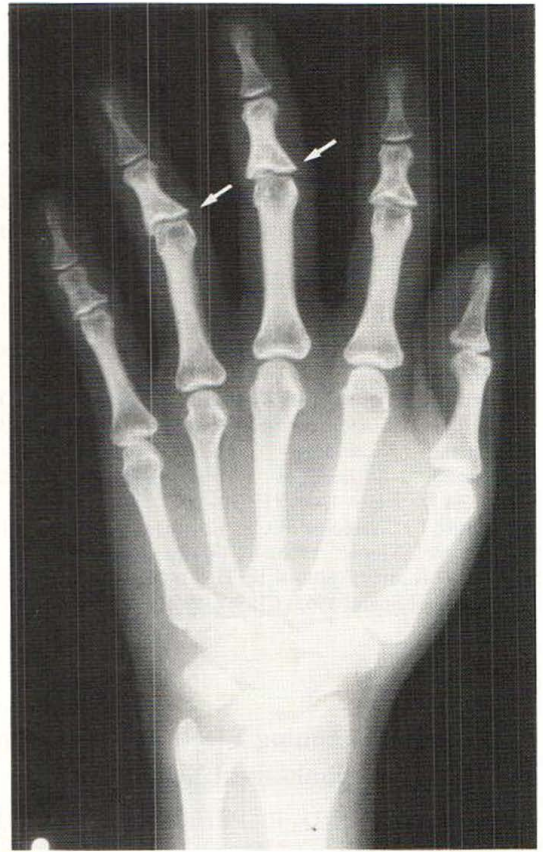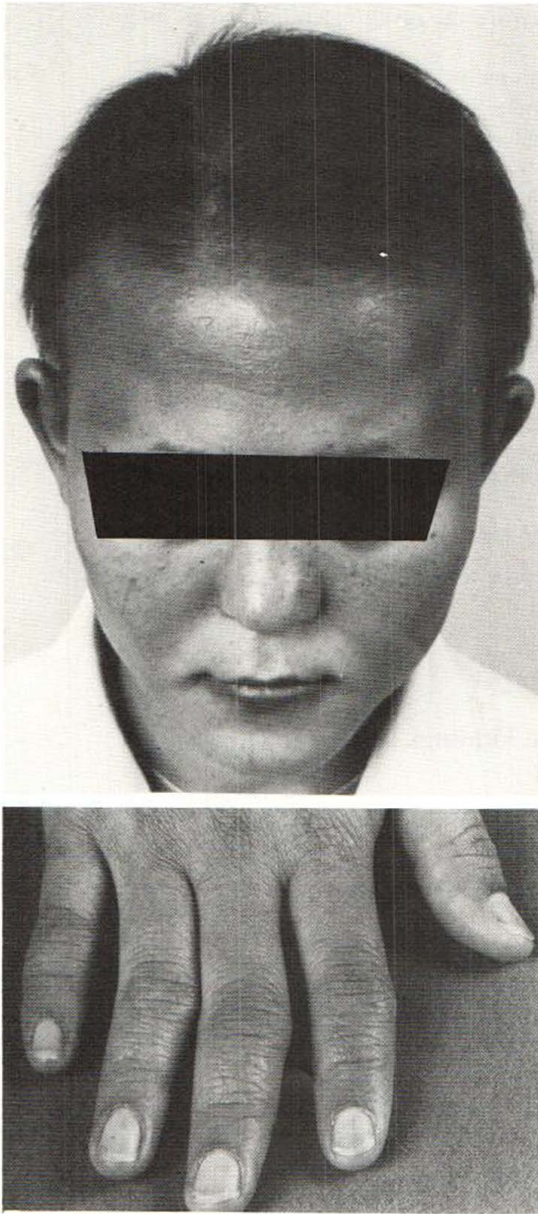


Fig. 1. Sparsely distributed short scalp hair, absent lateral part of the eyebrows, pear shaped nose and long philtrum.

Fig. 2. Swelling and ulnar deviation of the 2nd & 4th finger at the proximal interphalangeal joints.

Fig. 3. Cone-shaped, epiphyses type 12 peripheral dysostosis, at the proximal interphalangeal joints.

also suggested an autosomal dominant mode of inheritance; a recessive mode of inheritance is possible, solitary cases have also been reported (5). In type II TRP syndrome the following symptoms are also present: large protruding ears, multiple cartilaginous exostoses and some degree of mental retardation or microcephaly (6). Ultrastructural studies of the hair in this syndrome only revealed a reduced diameter of the scalp hair shaft and relative hypoplastic papilla (7). Abnormalities of the cuticular pattern or shaft structure studied by scanning electron microscopy (SEM) have not been reported (7, 8).

CASE REPORT

A 21-year-old girl of Indonesian origin was seen because of increasing hair loss since two years. She already had sparsely distributed, slowly growing and fragile scalp hair from childhood. Her mental and motor development was normal, but growth was slow and body height decreased in the end. The family history was negative for dwarfism, joint deformities, alopecia/hypotrichosis or consanguinity.

Physical examination: Length 1.47 m, weight 45 kg. Scalp hair: sparsely distributed, short and thin, receding fronto-temporal hairline. The lateral part of the eyebrows, the axillary and extremity hair was absent, the pubic hair sparse. Nose: 'pear-shaped', bulbous with an enlarged philtrum (Fig. 1). Normal teeth and nails. Hands: short fingers, ulnar deviation of the 2nd-4th fingers at the proximal interphalangeal joints (Fig. 2). A prominent sternum with thickening at the costal-sternal border. Feet: pes planes, short first toe. Further physical examination revealed no abnormalities.

X-ray examination: Short metacarpalea, typical cone-shaped epiphyses, type 12 Peripheral Dysostosis (9, 10) mainly at the 3rd and 4th proximal interphalangeal joints of the hands (Fig. 3). Short metatarsalea of both feet. Besides a mild cervical scoliosis, a 'total-body' X-ray examination did not reveal other abnormalities, e.g. exostoses. On the basis of the clinical and X-ray findings the diagnosis TRP syndrome type I was obvious.

Further investigations were carried out: Blood chemistry and endocrinology: normal. Delayed type immunity screened by intradermal injection of P.P.D., *Hemophilus influenzae*, *Staf. aureus*, *Candida albicans*. Trichofyton spec., Streptodornase and Streptokinase and Influvac: normal pattern.

Sweat-test (exercise): Normal sweat production.

Histologic examination scalp: Multiple hair follicles in different phases, normal amount of sweat and sebaceous glands, a mild perifollicular fibrosis. Amino-acid analysis scalp hair: normal pattern.

Hair root examination: telogen rate increased. The diameter of the hair shaft appeared to be markedly decreased: 30-40 μm (normal 80-100 μm), there was no variation in diameter along the hair shaft.

Physical examination of the patient's sister and the study of a photograph of her father, revealed no abnormalities. X-rays of hands and feet of father and sister were normal. Blood group and Rhesus factor of the three persons matched.

Scanning electron microscopy: The basal portions of the hairs, trimmed to a length of about 10 mm, were attached by double-sided tape to the SEM stud. Without any further treatment, a thin layer of gold as sputtered onto these specimens. The hairs from the patient were compared with those obtained from her sister in a Cambridge S 180 scanning electron microscope, operating at 15 KV. The hairs of the control (sister's) specimen were normal, both in diameter and morphological appearance. The patient's hair is characterized by its extremely reduced diameter and occasionally dimples with outward deviation of the free ends of the cuticle cells (Fig. 4). The surface pattern as well as the individual cuticle cells show some abnormalities. The spacing between the overlapping cuticular scales is highly irregular. The free margins of the cuticle cells are jagged, some show longitudinal pleating and at some places a major part of the cuticle cell has broke off, exposing the cortex (Figs. 5 and 6).

DISCUSSION

Until 1973 sixty cases of the TRP syndrome have been described (5), of which 13 (11 female and 2 male) were solitary cases. The absence of clinical and X-ray abnormalities in the probands family, and matching of the blood groups strongly suggest that we are dealing with a solitary case (again female!). However, for a complete background thorough X-ray examination of parents and relatives and blood group determination is necessary because of the irregular expressivity in this syndrome (1, 5). In the past no or only light microscopic examination of the hair took place, more attention was paid to the clinical, genetical and radiological features of the TRP syndrome (1, 2, 3, 4).

In contrast to our SEM findings some authors reported no abnormalities at SEM investigation of the hair in this syndrome (7, 8). SEM alterations not having much in common with our SEM findings have been described in other syndromes also belonging to the Ectodermal Dysplasia group such as (trichoonytic type) Hidrotic ectodermal dysplasia, Autosomal recessive- and X-linked Anhidrotic ectodermal dysplasia (8, 11). Further SEM examination of hair of more TRP syndrome type I patients will indicate if our findings are common and, if so, characteristic of this syndrome.

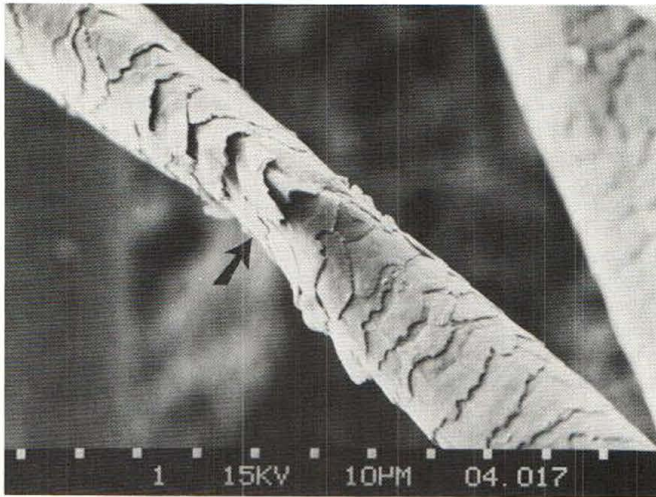


Fig. 4. Dimple in the hair shaft and outward deviation at the free ends of the cuticle cells. $\times 1030$.

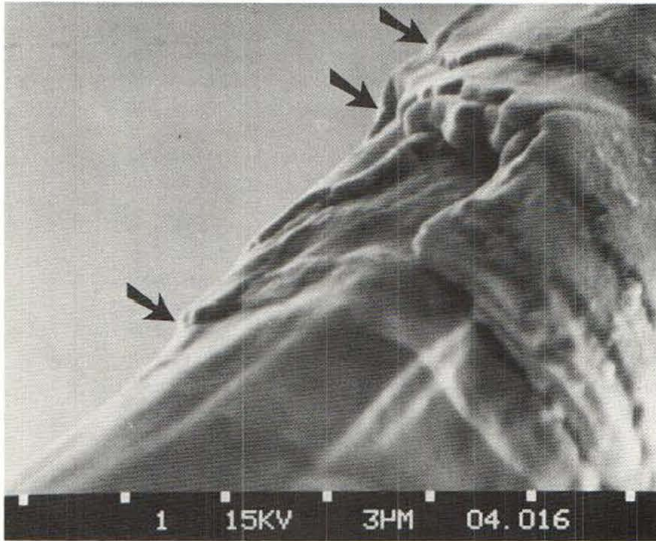


Fig. 5. Jagged free margins of the cuticle cells. $\times 5800$.

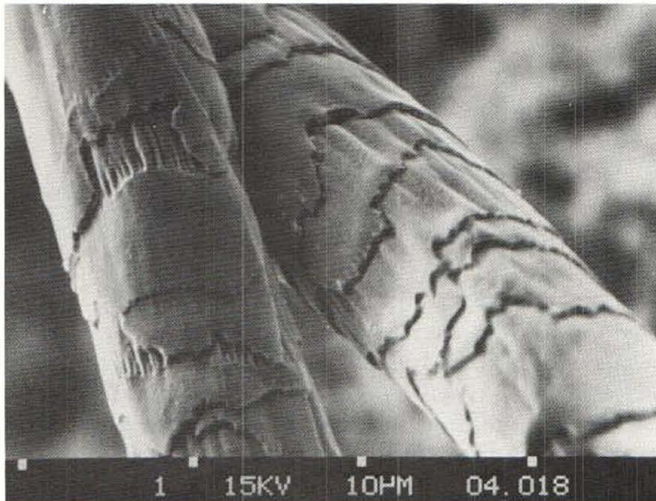


Fig. 6. Longitudinal pleating of—and partially broken off cuticle cells. $\times 2860$.

REFERENCES

1. McCloud DJ, Solomon LM. The tricho-rhino-phalangeal syndrome. *Br J Dermatol* 1977; 96: 403-407.
2. Kuna GB, Collip BJ, Balsam D. Trichorhinophalangeal Dysplasia (Giedion syndrome), a case report. *Clin Pediatr (Phila)* 1978; 17: 96-98.
3. Gorlin RJ, Michael Cohen M, Wolfson J. Tricho-rhino-phalangeal syndrome. *Am J Dis Child* 1969; 118: 595-599.
4. Peltola J, Kuokkanen K. Tricho-rhino-phalangeal syndrome in five successive generations: report on a family in Finland. *Acta Derm Venereol (Stockh)* 1978; 58: 65-68.
5. Giedion A, Burdea M, Furchter Z, Meloni T, Trosc V. Autosomal dominant transmission of the Trichorhinophalangeal syndrome. *Helv Paediatr Acta* 1973; 28: 249-259.
6. Rook A, Dawber R. *Diseases of the hair and scalp*. Oxford, London, Edingburgh, Boston, Melbourne, Blackwell Scientific Publications, 1982: 159-161.
7. Van Neste D, Dumortier M. Tricho-rhino-phalangeal syndrome. Disturbed geometric relationships between hair matrix and dermal papilla in scalp hair bulbs. *Dermatologica* 1982; 165: 16-23.
8. Haneke E, Wilsch L. Scanning electron microscopic investigations of the hair in Ectodermal Dysplasia syndromes. Orfanos, Montagna and Stüttgen, ed. In: *Hair research*, Berlin, Heidelberg: Springer-Verlag, 1981: 433-435.
9. Giedion A. Cone-shaped epiphyses of the hands and their diagnostic value. The tricho-rhino-phalangeal syndrome. *Ann Radiol* 1967; 10: 322-329.
10. Giedion A. Die periphere Dysostose (PD)—ein Sammelbegriff. *Fortschr Röntgenstr* 1969; 110 (4): 507-524.
11. Wilsch L, Haneke E, Schaidt G. Structural hair abnormalities in Hidrotic Ectodermal Dysplasia (HED). *Arch Dermatol Res* 1977; 259: 101-103.