

found to be within normal limits: full blood count, SMA 12, urinalysis. A superimposed oral candidiasis was ruled out because direct examination and culture on Sabouraud's medium did not show spores or pseudohyphae. A biopsy specimen was taken from the mucosa of the right cheek and submitted for histologic examination. Alcohol-fixed, paraffin-embedded sections were stained with hematoxylin-eosin. At bright-field examination the *surface epithelium was acanthotic, with many islands of enlarged and vacuolized cells, many of which were devoid of nuclei (Fig. 2)*. No evidence of dyskeratosis was seen: the corium displayed a slight, diffuse chronic inflammatory infiltrate. PAS stain revealed purplish-red glycogen-positive granules in the cytoplasm of many of the epithelial cells.

Treatment with penicillin (Triwycillina, Carlo Erba, Italy) was started, with a total dose of 12 MU (1.2 MU i.m. every third day).

Improvement became apparent soon after the first injection and the oral plaques were consistently reduced and less prominent at the end of the treatment, as shown in Fig. 3. The patient was followed up for 6 months and no relapse was noted.

DISCUSSION

WSN is an autosomal, dominant, inherited disease of the mucous membranes, affecting mainly the oral mucosa. This benign condition was recently reviewed by Jorgenson & Levin (2). We deemed it interesting to report the present case because our patient clearly improved soon after penicillin administration. As his lesions had never got better previously, either spontaneously or after other treatments, the favorable effect of this antibiotic on WSN is confirmed. O'Leary and colleagues (3) first reported a patient, who on one occasion noted the disappearance of her oral lesions following intramuscular injections of penicillin.

This treatment is based on practical experience without reference to scientific principles, but it seems to be the only available remedy.

REFERENCES

1. Cannon, A. B.: White nevus of the mucosa (nevus spongiosus albus mucosae). *Arch Dermatol Syphilol* 31: 365, 1935.
2. Jorgenson, R. J. & Levin, L. S.: White sponge nevus. *Arch Dermatol* 117: 73, 1981.
3. O'Leary, P. A., Montgomery, H., Brunsting, L. A. & Kierland, R. R.: White sponge nevus: Moniliasis? *Arch Dermatol Syphilol* 62: 608, 1950.

Chondrodermatitis nodularis chronica helicis Treated with Curettage and Electrocauterization: Follow-up of a 15-year Material

N. Kromann, H. Høyer and F. Reymann

Department of Dermatology, The Finsen Institute, DK-2100 Copenhagen Ø, Denmark

Received April 8, 1982

Abstract. During the 15-year period from 1965 to 1979 a total of 142 cases of chondrodermatitis nodularis chronica helicis were diagnosed. 32% were women, a higher proportion than in earlier materials. The treatment was principally curettage followed by electrocauterization. 78 patients were re-examined after an average lag of 7.1 years. The relapse rate was 31%. This simple surgical technique seems equal to the more elaborate procedures in respect of recurrence rate and more satisfactory from a cosmetic point of view.

Key words: Chondrodermatitis nodularis chronica helicis; Sex incidence; Curettage; Electrocauterization

Chondrodermatitis nodularis chronica helicis (CNCH) is a distinct clinical entity, although not rare, first recognized 1916 by Winkler of Luzern (4). Clinically it is characterized by a small tender nodule situated on the lateral aspect of the outer ear and causing much distress to the patients, especially by disturbing the sleep.

As the most appropriate treatment is still a matter of dispute, we have found it of interest to present the results of a 15-year follow-up of a material principally treated by curettage combined with electrocauterization.

MATERIAL

During the 15-year period from January 1965 to December 1979, 142 patients attended our out-patient clinic suffering

Table I. *Patient material*

Total number of patients 1965-1979	142
Men	97
Women	45
Re-examined	64
Interviewed by letter or telephone	14
Deceased	52
Non-responders	12

Table II. *Clinical and epidemiological data*

	n	
Average age at onset		
Men	97	62 years (31-81)
Women	45	64 years (16-88)
Duration until attendance	113	14 months (1 month-25 years)
Multiple unilateral nodules	142	3.5%
Bilateral nodules	142	0
Localization on the right ear	140	61%
Localization on preferred sleeping side	36	78%
Localization on anthelix, tragus or antragus		
Men	75	4%
Women	31	39%
Outdoor professional work or hobby		
Men	50	60%
Women	26	8%

from CNCH. The data for the material are given in Tables I and II.

In 109 cases a histological examination was performed. In 2 cases the findings were suggestive of basal cell carcinoma and in one case of squamous cell carcinoma, but clinically there was no suspicion of malignancy and no relapse after the initial treatment occurred. In one case an uncharacteristic nodule on the ear was treated as CNCH. By its recurrence 6 weeks later the histologic diagnosis of squamous cell carcinoma was established.

METHODS

For each patient the initial course of treatment and the first possible recurrence were noted. Recurrence was defined as the appearance of a new tender nodule on the same location at least 3 months after the initial treatment.

The therapeutic approach was principally surgical: curettage and subsequent electrocauterization. A supplementary course of three X-irradiations in a dose of 1.0 Gy delivered at 29 or 43 kV was given in 15 cases. In 5 cases X-irradiation was given primarily. Other adjunctive modalities were intralesional injection of a triamcinolone crystal suspension, and freezing with carbon dioxide. The time between the initial treatment and the follow-up examination was on an average 7.1 years.

RESULTS

Of the whole group of 142 patients a recurrence—as previously defined—was noted in 36, viz. 25%. Among the 78 re-examined, a recurrence was recorded in 24 (31%). In this group the CNCH reappeared with an average lag of 2.1 years—half of them during the first year after the intervention. The recurrence rate for one person-year within the observation period was 0.04.

DISCUSSION

This not uncommon condition can in the majority of instances be diagnosed on the basis of its clinical features: the appearance of the nodule on a typical

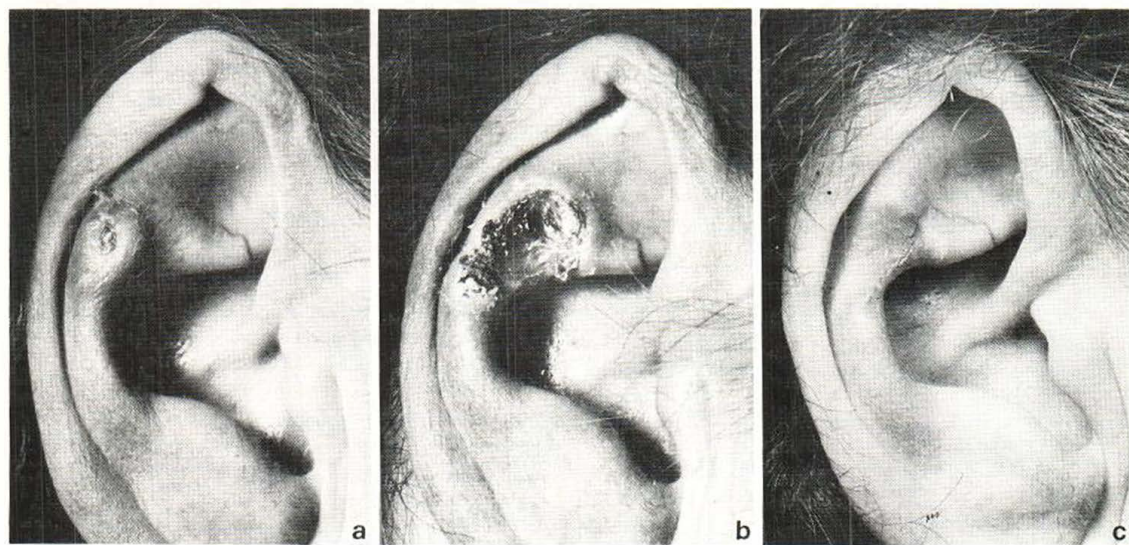


Fig. 1. A typical lesion of anthelix. (a) Before, (b) 2 weeks after, and (c) 6 months after curettage/electrocauterization.

location and its extreme tenderness to pressure. A histological examination may support the diagnosis, but is performed mainly to exclude malignancy. Apart from one case of squamous cell carcinoma misdiagnosed as CNCH, no malignant tumours arose at the site of the CNCH in our series of 142 patients.

In the literature it is usually stated that CNCH is far more common in men than in women. By reviewing the existing literature, Duncan (2) found in 1937 that the male cases outnumbered the female cases by 10 to 1. The men still constitute 68 per cent of our material, but a change in the sex distribution seems to have taken place during the last four decades. Although sun exposure of women is, no doubt, increasing, our interviews still show more outdoor activity both during work and at leisure among the male patients, which may to some degree explain the sex difference in incidence.

It has earlier been claimed that persistent pressure on the outer ear is of pathogenetic significance. Our data support this assumption, as the condition was more frequently recorded on the right side—the preferred resting side during sleep. A few patients mentioned pressure from certain headgear or a hearing aid as the cause of their trouble. In 2 young women the CNCH was situated on a very prominent anthelix, which could be ascribed to a corrective operation for aures alatae performed during childhood.

The treatment currently recommended is excision of an ellipse of skin and subjacent cartilage. Newcomer (3) re-examined 58 patients treated this way and found 18 recurrences appearing from 2 months to 3 years after the operation (31%). Bard (1) treated 19 patients by shave biopsy of the lesion and subsequent curettage and electrodesiccation. 21% of the lesions reappeared 4 months to 7 years after treatment. In our department this condition has been treated by routine, with curettage and electrocauterization only. In the few cases where X-irradiation was tried as the first procedure of treatment there was no recovery.

Our recurrence rate is comparable to that of the more elaborate surgical techniques mentioned above. In experienced hands our method is faster and less mutilating. The most critical point in this procedure is, in our experience, the thorough cauterization of all chondritic tissue left after the curettage. Some weeks after the procedure the surroundings may still be tender, swollen and red, but this

reactive alteration subsides gradually. From a cosmetic point of view this simple technique is very satisfactory.

REFERENCES

1. Bard, J. W.: Chondrodermatitis nodularis chronica helicis. *Dermatologica* 163: 376, 1981.
2. Duncan, O.: Sex incidence of chondrodermatitis nodularis chronica helicis. *Texas J Med* 33: 19, 1937.
3. Newcomer, V. D., Steffen, C. G., Sternberg, T. H. & Lichtenstein, L.: Chondrodermatitis nodularis chronica helicis. Report of ninety-four cases and survey of literature, with emphasis upon pathogenesis and treatment. *Arch Dermatol Syph* 68: 241, 1953.
4. Winkler, M.: Knötchenförmige Erkrankung am Helix. Chondrodermatitis nodularis chronica helicis. *Arch Dermatol Syph* 121: 278, 1916.

Short-wave Ultraviolet Light (UVB) Treatment of Allergic Contact Dermatitis of the Hands

Nils-Jørgen Mørk and Joar Austad

*Department of Dermatology, Rikshospitalet,
the National Hospital, University of Oslo,
Oslo 1, Norway*

Received June 8, 1982

Abstract. 7 out of 10 patients with long-standing allergic contact dermatitis of their hands were successfully treated with short-wave ultraviolet light (UVB) and the contact dermatitis healed completely. To maintain this result they had to receive UVB therapy regularly once a week. The last 3 patients also showed improvement, but they had periods with vesiculation during the treatment. UVB treatment seems to be a valuable supplement for the treatment of contact dermatitis.

Key words: Short-wave ultraviolet light (UVB) treatment; Allergic contact dermatitis

During recent years many reports have been published on the influence of ultraviolet radiation on the immune systems. Haniszko and Suskind showed in 1963 that ultraviolet light at 280–320 nm inhibits cutaneous sensitization in guinea pigs (5). It has also been shown that the contact allergic reaction is alleviated when guinea pigs are exposed to UVB radiation during the period of sensitization