

of tuberculoid leprosy. Recently, another case has been reported (4). From 1975 to 1982, 3397 Vietnamese refugees have arrived in Denmark. Up to the present, leprosy has been discovered only in our patient and in a 61-year old man with tuberculoid leprosy (Prof. Finn T. Black, personal communication).

The immune response of the patient was normal and consistent with the clinical diagnosis of tuberculoid leprosy. Using monoclonal antibodies, Bach et al. (1) found no significant change in T lymphocyte subpopulations in peripheral blood in leprosy. In our patient it is likely that the significant change in the ratio between T- $\gamma$  and T- $\mu$  lymphocytes and her lymphocyte reactivity *in vitro* is a reflection of her resistance towards the infection.

The incidence of leprosy in Vietnam is considered to be approximately 1% (5). Apparently, the incidence in the refugees is much lower. However, Scandinavian doctors should be aware of its existence.

#### ACKNOWLEDGEMENT

The immunological studies were supported by the Danish Medical Research Council, grant no. 12-1740. We thank Ms Annie Jespersen for her laboratory assistance and Mrs Margareta Sommer for her secretarial help.

#### REFERENCES

1. Bach, M.-A., Chatenoud, L., Wallach, D., Tuy, F. P. D. & Cottenot, F.: Studies on T cell subsets and functions in leprosy. *Clin Exp Immunol* 44: 491, 1981.
2. Castor, B., Frolov, I. & Hansen, C.: Infection panorama among Vietnamese boat people. *Läkartidningen* 78: 1659, 1981. (In Swedish.)
3. Jensen, J. R., Cramers, M. & Thestrup-Pedersen, K.: Subpopulations of T lymphocytes and non-specific suppressor cell activity in patients with atopic dermatitis. *Clin Exp Immunol* 45: 118, 1981.
4. Ölcén, P. & Fredlund, H.: *Leprosy hos båtflykting*. Report no. Vecka 41, 1981, from the National Bacteriological Laboratory, Department of Epidemiology, S-105 21 Stockholm, Sweden.
5. Prag, J., Nørredam, K. & Hardvendel, U.: The health of 150 Mon-Khmers during the first 30 months in Denmark. *Ugeskr Læg* 141: 3022, 1979. (In Danish.)
6. Schmidt, H.: A case of leprosy diagnosed in Denmark. *Ugeskr Læg* 134: 1169, 1972. (In Danish.)

## White Sponge Nevus: Successful Treatment with Penicillin

A. Alinovi, D. Benoldi and E. Pezzarossa

Department of Dermatology, University of Parma, Parma, Italy

Received May 12, 1982

**Abstract.** White sponge nevus is a rare, benign, inherited disorder of the mucous membranes, affecting mainly the oral mucosa. A case is reported of white sponge nevus, which showed a definite improvement following penicillin administration.

**Key words:** White sponge nevus; Leukoderma exfoliativum mucosae oris; Penicillin

Since Cannon first reported 3 cases of white sponge nevus (WSN) of the oral mucosa in 1935 (1), fewer than 80 cases of this autosomal dominant disorder have been recorded in the literature.

The treatment of WSN is considered unrewarding, with the exception of penicillin, whose administration was noted to be associated with remission in 2 patients (3, 2). The purpose of this report is to describe a case of WSN in which the oral lesions almost completely disappeared during treatment with penicillin.

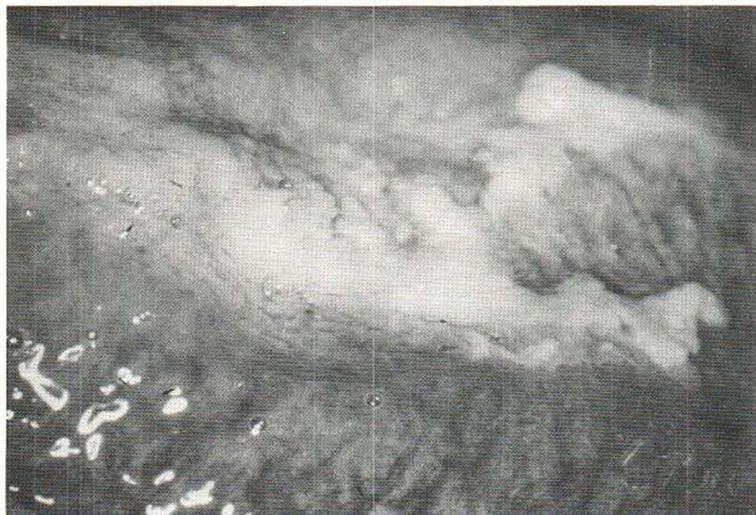#### REPORT OF A CASE

A healthy 23-year-old medical student was seen in the Skin Clinic of the University of Parma in September 1981 because of diffuse, white, folded, asymptomatic lesions confined to the oral mucosa. The onset was noted in infancy on the right side of the tongue, followed by bilateral involvement of the tongue and cheeks within 2 years. Afterwards the condition remained stationary despite several therapeutic trials.

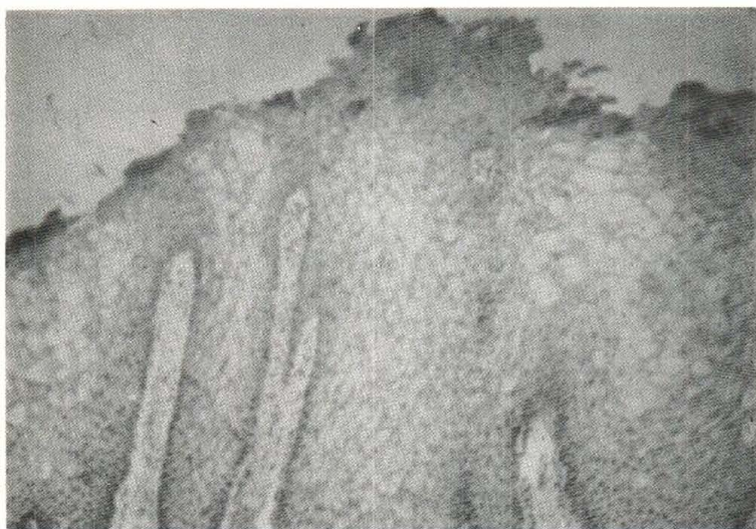
In 1978 he was treated with vitamin A orally (Arovit, Roche, Italy) for one year and then with nystatin (Mycostatin, Squibb, Italy) for 2 months, unsuccessfully. In January 1980 the histologic diagnosis of leukoplakia was made and treatment with liquid nitrogen was given, though without any effect.

The family history revealed that the patient's mother and grandmother had similar white spongy lesions of the mouth, whereas one brother and two aunts were not affected. Oral examination showed soft, creamy-white, folded, irregular plaques with spongy appearance, located on both sides of the tongue and cheeks (Fig. 1). No lesions were found on the palate, peritonsillar areas or lips. Moreover, conjunctivas, genitalia and anal mucosa were not affected.

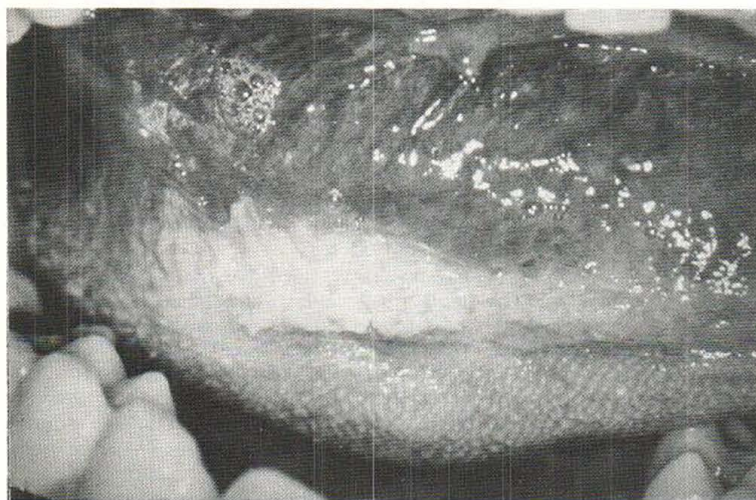
The following investigations were carried out and were



*Fig. 1.* White, irregular plaque on the right side of the tongue, before treatment with penicillin.



*Fig. 2.* Biopsy of lesion showing acanthotic epithelium and pronounced vacuolization of prickle-cells.



*Fig. 3.* Same area as in Fig. 1, after treatment with penicillin.

found to be within normal limits: full blood count, SMA 12, urinalysis. A superimposed oral candidiasis was ruled out because direct examination and culture on Sabouraud's medium did not show spores or pseudohyphae. A biopsy specimen was taken from the mucosa of the right cheek and submitted for histologic examination. Alcohol-fixed, paraffin-embedded sections were stained with hematoxylin-eosin. At bright-field examination the *surface epithelium was acanthotic, with many islands of enlarged and vacuolized cells, many of which were devoid of nuclei (Fig. 2)*. No evidence of dyskeratosis was seen: the corium displayed a slight, diffuse chronic inflammatory infiltrate. PAS stain revealed purplish-red glycogen-positive granules in the cytoplasm of many of the epithelial cells.

Treatment with penicillin (Triwycillina, Carlo Erba, Italy) was started, with a total dose of 12 MU (1.2 MU i.m. every third day).

Improvement became apparent soon after the first injection and the oral plaques were consistently reduced and less prominent at the end of the treatment, as shown in Fig. 3. The patient was followed up for 6 months and no relapse was noted.

#### DISCUSSION

WSN is an autosomal, dominant, inherited disease of the mucous membranes, affecting mainly the oral mucosa. This benign condition was recently reviewed by Jorgenson & Levin (2). We deemed it interesting to report the present case because our patient clearly improved soon after penicillin administration. As his lesions had never got better previously, either spontaneously or after other treatments, the favorable effect of this antibiotic on WSN is confirmed. O'Leary and colleagues (3) first reported a patient, who on one occasion noted the disappearance of her oral lesions following intramuscular injections of penicillin.

This treatment is based on practical experience without reference to scientific principles, but it seems to be the only available remedy.

#### REFERENCES

1. Cannon, A. B.: White nevus of the mucosa (nevus spongiosus albus mucosae). *Arch Dermatol Syphilol* 31: 365, 1935.
2. Jorgenson, R. J. & Levin, L. S.: White sponge nevus. *Arch Dermatol* 117: 73, 1981.
3. O'Leary, P. A., Montgomery, H., Brunsting, L. A. & Kierland, R. R.: White sponge nevus: Moniliasis? *Arch Dermatol Syphilol* 62: 608, 1950.

## Chondrodermatitis nodularis chronica helicis Treated with Curettage and Electrocauterization: Follow-up of a 15-year Material

N. Kromann, H. Høyer and F. Reymann

*Department of Dermatology, The Finsen Institute, DK-2100 Copenhagen Ø, Denmark*

Received April 8, 1982

**Abstract.** During the 15-year period from 1965 to 1979 a total of 142 cases of chondrodermatitis nodularis chronica helicis were diagnosed. 32% were women, a higher proportion than in earlier materials. The treatment was principally curettage followed by electrocauterization. 78 patients were re-examined after an average lag of 7.1 years. The relapse rate was 31%. This simple surgical technique seems equal to the more elaborate procedures in respect of recurrence rate and more satisfactory from a cosmetic point of view.

**Key words:** Chondrodermatitis nodularis chronica helicis; Sex incidence; Curettage; Electrocauterization

Chondrodermatitis nodularis chronica helicis (CNCH) is a distinct clinical entity, although not rare, first recognized 1916 by Winkler of Luzern (4). Clinically it is characterized by a small tender nodule situated on the lateral aspect of the outer ear and causing much distress to the patients, especially by disturbing the sleep.

As the most appropriate treatment is still a matter of dispute, we have found it of interest to present the results of a 15-year follow-up of a material principally treated by curettage combined with electrocauterization.

#### MATERIAL

During the 15-year period from January 1965 to December 1979, 142 patients attended our out-patient clinic suffering

Table I. *Patient material*

Total number of patients 1965-1979	142
Men	97
Women	45
Re-examined	64
Interviewed by letter or telephone	14
Deceased	52
Non-responders	12