

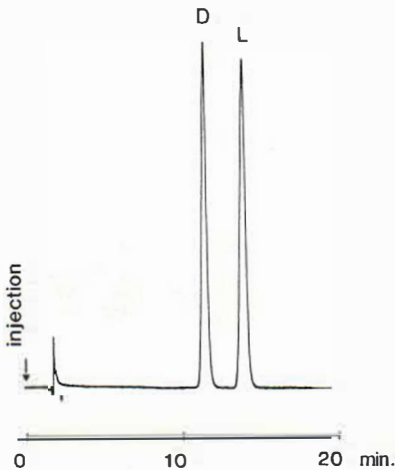Fig. 2. Separation of 5-S-L-cysteinyl-L-dopa from 5-S-D-cysteinyl-L-dopa. Mobile phase: Water, 3.0 orthophosphoric- and 6.0 g methanesulphonic acid per litre. pH 3.00. Column: Nucleosil C₁₈ (5 μ m), 250 \times 46 mm. Flow rate: 1.5 ml/min. Peak identity: D = 5-S-D-cysteinyl-L-dopa, L = 5-S-L-cysteinyl-L-dopa.

DISCUSSION

The finding of easily separable diastereomers of 5-S-cysteinyl-dopa may be of great practical value in the study of cysteinyl-dopas and related substances.

Analysis of catecholic amino acids of importance in pigment metabolism, such as 5-S-cysteinyl-dopa, meets with considerable difficulties because such compounds are easily oxidized. Falsely low serum values of 5-S-cysteinyl-dopa may be obtained because of oxidation at sample collection, during sample handling, storage, or quantitation. Falsely high blood levels of cysteinyl-dopa may be seen in patients on dopa medication due to artificial oxidation of a minute portion of the large quantities of dopa present in the serum. To avoid errors of the type mentioned, different reducing agents may be added to the blood samples. If the reductant added is similar to the substance to be analysed the added reducing agent may also serve as an internal standard in the analytical procedure. Now that it is possible to analyse diastereomers of 5-S-cysteinyl-dopas separately, an ideal internal standard has been found.

Quantitation of the cysteine addition products of D- and L-dopa will be especially helpful in the investigation of tyrosinase activity in Man, since tyrosinase shows great stereospecificity in higher animals.

The diastereomers formed from D-cysteine may be used in the investigations of cysteine metabolism, e.g. for quantitation of L-cysteine levels in body fluids and tissues.

ACKNOWLEDGEMENTS

This investigation has been supported by grants from the Swedish Cancer Society (project 626-B81-09XC), the Swedish Medical Research Council, the Thure Carlsson Foundation for Scientific Research, the Walter, Ellen, and Lennart Hesselman Foundation for Scientific Research, the Edvard Welander Foundation for Scientific Research, the donation funds of the University Hospital at Lund, and the donation funds of the Faculty of Medicine, University of Lund.

REFERENCES

1. Agrup, G., Hansson, C., Rorsman, H., Rosengren, A.-M. & Rosengren, E.: Mass spectrometric analysis of enzymatically synthesized cysteinyl-dopa isomers. Communications from the Department of Anatomy, University of Lund, Sweden, No. 5, 1976.
2. Agrup, G., Hansson, C., Rorsman, H. & Rosengren, E.: The effect of cysteine on oxidation of tyrosine, dopa, and cysteinyl-dopas. *Arch Dermatol Res* 272: 103, 1982.
3. Ito, S. & Prota, G.: A facile one-step synthesis of cysteinyl-dopas using mushroom tyrosinase. *Experientia* 33: 1118, 1977.
4. Prota, G.: Structure and biogenesis of phaeomelanins. In *Pigmentation: Its Genesis and Biologic Control* (ed. Vernon Riley), p. 615. Appleton, Century, Crofts, Meredith Corporation, New York, 1972.
5. Rorsman, H., Agrup, G., Hansson, C., Rosengren, A.-M. & Rosengren, E.: Detection of phaeomelanins. In *Pigment Cell* (ed. S. N. Klaus), p. 244, S. Karger, Basel, 1979.

Scanning Electron Microscopic Visualization of Rolled Hair (Poils en Spirale)

Lasse Kanerva,^{1,2,3} Kirsti-Maria Niemi,¹
Allan Lassus¹ and Tapio Rantanen¹

¹Department of Dermatology, University Central Hospital, Helsinki, ²Department of Anatomy, University of Helsinki, and ³Institute of Occupational Health, Helsinki, Finland

Received October 20, 1981

Abstract. A patient suffering from recalcitrant pemphigoid developed rolled hairs after prolonged oral corticosteroid



Fig. 1. Rolled hair.



Fig. 2. Light microscopy of affected follicle. $\times 380$.

therapy. Consequently, we looked for rolled hairs in 100 out-patients, but none could be found. The rolled hairs were characterized by light and scanning electron microscopy.

Key words: Scanning electron microscopy; Rolled hair; Corticosteroids; Pemphigoid

Rolled hairs ("Poils en spirale") are tightly coiled hairs rolled into a circular pattern under a thin translucent layer of stratum corneum (2). They are associated with ichthyosis of autosomal dominant type or with keratosis pilaris of other origins (4). They may also be associated with prolonged corticosteroid therapy (2).

We noted this phenomenon in a patient with severe pemphigoid who had been treated for several years with oral corticosteroids. The purpose of the present study was to shed light on this phenomenon with the aid of scanning electron microscopy.

CASE REPORT

The patient was a 57-year-old man (born in 1922) who in 1975 developed tense bullae over large areas of the body.

A biopsy revealed a subepidermal bulla with an eosinophilic perivascular infiltrate. Direct immunofluorescence showed IgG and complement in the basement membrane. The basal lamina antibodies were positive at 1:1000.

Consequently, the bullous disease was diagnosed as pemphigoid.

Thereafter he had taken oral corticosteroids almost continuously. The blisters had a tendency to recur rapidly after cessation of oral corticosteroids. When we noticed the rolled hairs on his abdominal skin (1979) the patient had already developed a Cushing-type moon face. Having found this one patient with rolled hairs, we examined 100 out-patients, but none of these had rolled hairs.

Two 4-mm biopsies for light microscopy, one for immunofluorescence microscopy and two similar biopsies for scanning electron microscopy, containing one rolled hair were studied. The light microscopical samples were sectioned serially. Two extracted rolled hairs were visualized with scanning electron microscopy. The scanning electron microscopy specimens were processed and examined by the routine methods used in our laboratory (3).

RESULTS

Follicular openings with a small dark coiled hair 1–3 mm in diameter visible through a transparent horny layer were found on the lower and mid-abdomen (Fig. 1). No evidence of inflammation was observed.

Light microscopy

The follicles were superficial and more horizontal than normally. The follicle openings were slightly parakeratotic, widened, and filled with keratin (Fig. 2). Often more than one hair shaft was seen per follicle. Several cross sections of the hair were

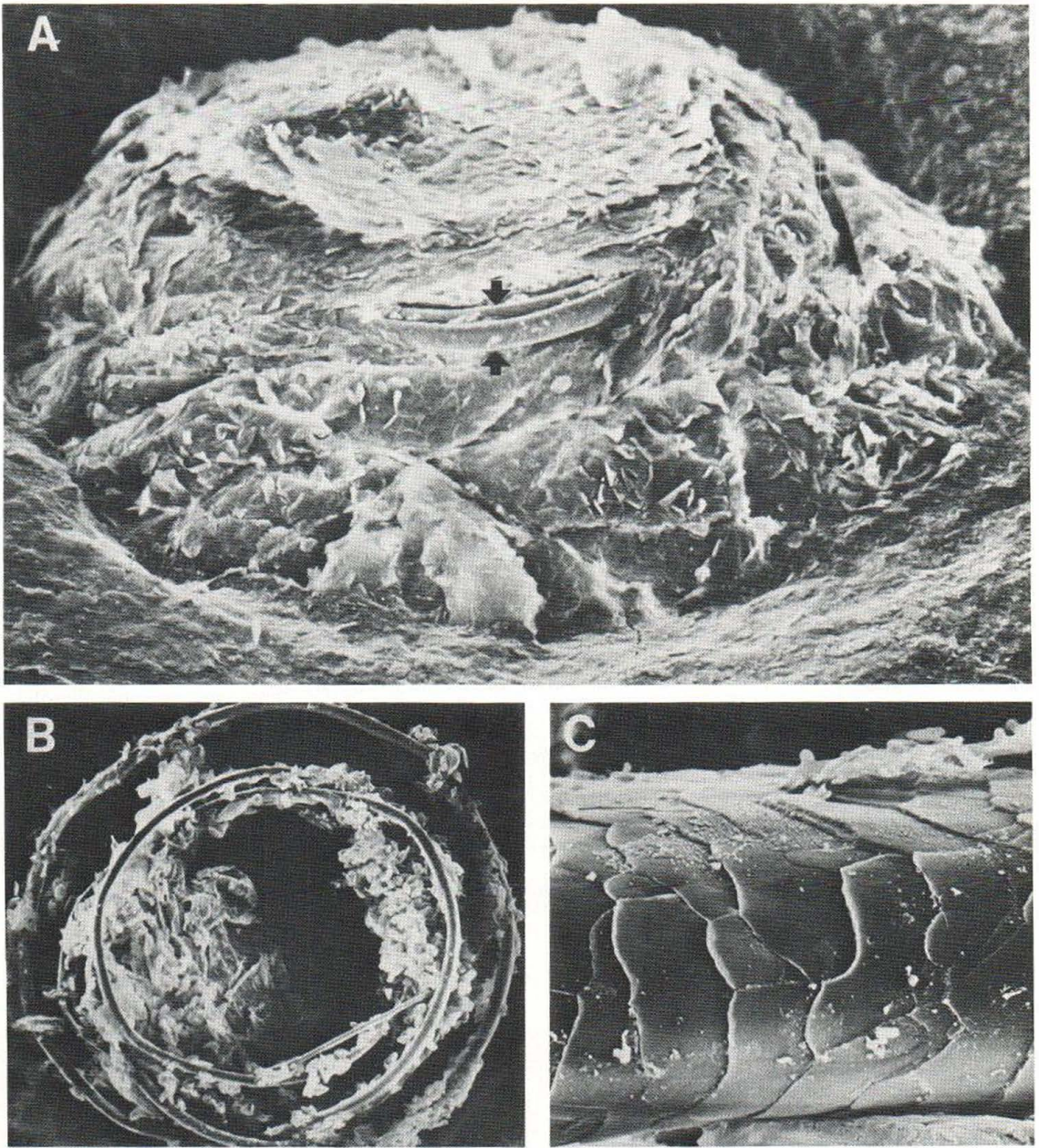


Fig. 3. (A) Scanning electron micrograph showing the enlarged follicle containing a rolled hair mainly covered by keratin. The rolled hair shaft is exposed at two sites

(arrow). $\times 80$. (B) Extracted coiled hair with attached keratin. $\times 50$. (C) Normal appearance of hair cuticle of rolled hair. $\times 1400$.

seen within the keratin mass. A slight perivascular inflammatory reaction was seen close to the follicle.

Immunofluorescence microscopy

The direct immunofluorescence microscopy visualized complement and IgG at the basement

membrane around the hair follicle, thus confirming the diagnosis of bullous pemphigoid.

Scanning electron microscopy

Scanning electron microscopy revealed an enlarged crater-like follicle opening filled with dome-shaped

keratin. Contours of a rolled hair were visible within the keratin mass. At points of exposure, the rolled hair showed a normal cuticle (Fig. 3).

DISCUSSION

Although rolled hair was already mentioned as early as 1894 by Unna (5), it has not received much attention in the literature. Ferguson et al. (2) reported 4 patients, of whom 2 patients had received systemic corticosteroid. They concluded that corticosteroids might be involved in the formation of rolled hairs. Adatto (1) reported that rolled hairs are frequently found in men aged 50 and over, without follicular abnormality. This would indicate that rolled hairs ought to be a regular feature in everyday dermatologic practice. Our study, however, shows that in Finnish patients this is a rare phenomenon, since it was not found in any patient in an examination of 100 out-clinic patients.

REFERENCES

- Adatto, R.: Poils en spirale (poils en roulés). *Dermatologica* 127: 145, 1963.
- Ferguson, A. G. & Derblay, P. R.: Rolled hairs. *Arch Dermatol* 87: 311, 1963.
- Lassus, A., Kanerva, L., Stubb, S. & Salonen, A.: White piedra. Report of a case evaluated by scanning electron microscopy. *Arch Dermatol* 118: 208, 1982.
- Rook, A., Wilkinson, D. S. & Ebling, F. J. G.: *Textbook of Dermatology*, 3rd ed. Blackwell Scientific Publications, Oxford, London, Edinburgh, Melbourne, 1979.
- Unna, P. G.: *Histopathologie der Haut-Krankheiten*, p. 292. Hirschwald, Berlin, 1894.

Do Sexual Steroids Contribute to the Pathomechanism of Rosacea? A Study of Estrogen and Androgen Receptors in Acne rosacea

Jolanta B. Schmidt, Manfred Raff and Jürgen Spona¹

Department of Dermatology II, Alserstraße 4, A-1090 Vienna, and ¹Department of Gynecology I, University of Vienna, Vienna, Austria

Received February 21, 1982

Abstract. Estrogen- and androgen receptor levels were investigated in the skin of 11 male and 4 female rosacea

patients. No significant difference in receptor distribution or in receptor levels could be found between rosacea lesions and normal skin of the same patients. Moreover, hormone serum levels were in the normal range. Data from the present investigation suggest that rosacea formation is not governed by endocrine, although clinical and electron microscopic observations indicate a possible endocrine influence at the vascular level.

Key words: Estrogen receptor; Androgen receptor; Rosacea; Normal skin; Hormone serum levels

Factors influencing the formation of rosacea have been discussed for a long time. They have been the objective of various investigations, but conceivable explanations are based on clinical observations only. A possible genetic disposition is discussed, as well as disorders of the gastrointestinal tract (1).

Another possibility which is discussed and which might be relevant is the role of the sebaceous gland in the aetiology of rosacea. Investigations have shown that there were no significant differences in the quantity or quality of skin surface lipids of rosacea patients compared with those of a control group (2, 8). On the other hand, the clinically often impressive appearance of seborrhoea, and the success of treatment with tetracycline (11) point to an altered function of the sebaceous glands as being one of the various conditions for the onset of rosacea. This is suggested by the results of treatment of rosacea with 13-*cis* retinoic acid (6, 7, 10), which is known to suppress sebaceous gland functions very effectively.

The dubious role of the sebaceous gland for the pathomechanism of rosacea, as well as the appearance of the disease in middle age when hormonal changes take place in the organism, led to the conclusion that hormonal influences might contribute to the origin of the disease—a conclusion which was based mainly on clinical observations.

The purpose of the present investigation was to study estrogen and androgen receptors in normal skin and in rosacea lesions, since a previous report (9) has shown an influence of sex steroids at the cellular level. In addition, 17 β -estradiol and testosterone serum levels were estimated in order to correlate them with receptor contents.

MATERIAL AND METHODS

Skin was obtained from 11 male and 4 female rosacea patients between 40 and 82 years of age. Two 6-mm