

Leukoplakia of the Prepuce with Epidermolytic Hyperkeratosis: A Case Report

G. KOLDE and F. VAKILZADEH

*Department of Dermatology, Westfälische-Wilhelms Universität,
Münster, F. R. Germany*

Kolde G, Vakilzadeh F. Leukoplakia of the prepuce with epidermolytic hyperkeratosis: A case report. *Acta Derm Venereol* (Stockh) 1983; 63: 571-573.

A leukoplakic lesion of the prepuce is described with the histologic and ultrastructural features of epidermolytic hyperkeratosis. The lesion represents most likely a variant of epidermolytic leukoplakia recently observed in the vermilion border of the lip. *Key words: Preputial epidermis; Epidermolytic leukoplakia.* (Received April 13, 1983.)

G. Kolde, Department of Dermatology, University of Münster, von-Esmarch-Str. 56, D-4400 Münster, F.R. Germany.

The term epidermolytic hyperkeratosis is applied to a distinctive, but nonspecific pathological process of the epidermis which is histologically characterized by vacuolization of the upper epidermal cells and by a thickened granular layer containing irregular keratohyaline granules. The histopathologic features of epidermolytic hyperkeratosis can occur in a wide variety of benign skin disorders including genodermatoses, acquired and nevoid dermatoses (1). More recently, similar alterations of the epidermis have been found to be associated with leukoplakic, probably precancerous skin lesions of the lip (2, 3). In the present case report, we demonstrate the occurrence of epidermolytic hyperkeratosis in a leukoplakic lesion of the prepuce.

CASE REPORT

The 51-year-old man presented with a sharply demarcated leukoplakia of the prepuce measuring 0.5×1.0 cm. There were no subjective symptoms. The lesion had developed six months earlier and

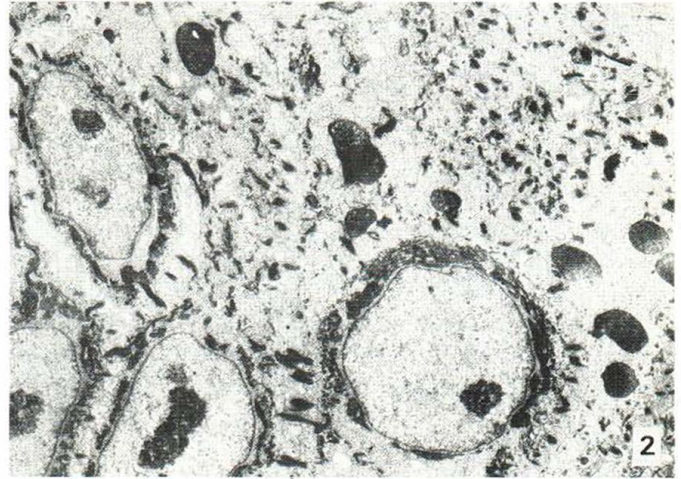
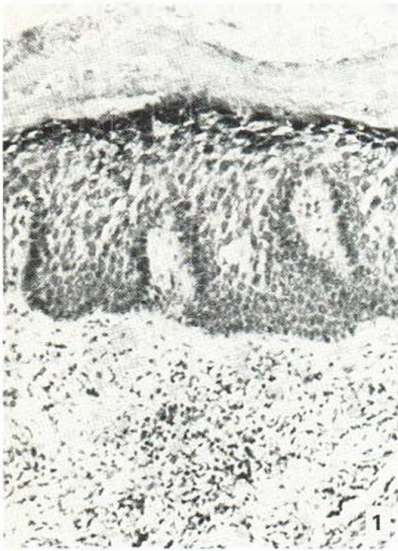


Fig. 1. Histologic appearance of the leukoplakia with epidermolytic hyperkeratosis and perivascular lymphohistiocytic infiltrate in the dermis. H&E, $\times 150$.

Fig. 2. Electron micrograph of the upper spinous keratinocytes showing perinuclear shells and peripheral clumping aggregates of the tonofibrils. $\times 4800$.

had been treated with local corticosteroid and antimycotic creams without any benefit. The leukoplakia was excised *in toto* and processed for routine histology.

Light microscopy (Fig. 1)

The biopsy specimen revealed a moderately acanthotic epidermis covered by a hyperkeratotic stratum corneum. The granular layer was thickened with numerous coarse keratohyaline granules. The keratinocytes of the stratum granulosum and upper stratum spinosum contained clear spaces around their nuclei and faintly eosinophilic strands in the more peripheral cytoplasm which made the cellular boundaries appear reticulate. The basal cell layer was normal, except for a slight enlargement of some nuclei. In the underlying dermis, a perivascular infiltrate was noted which was mainly composed of lymphocytes and histiocytes.

Electron microscopy

Because of the unexpected histologic findings in the leukoplakic lesion, an ultrastructural investigation was performed on material originally fixed in formalin for routine histology. Although the ultrastructural details of some cellular organelles were less preserved, the tissue displayed thick bundles of tonofibrils around the nuclei and clumped peripheral tonofilaments within the keratinocytes of the upper Malpighian layer (Fig. 2). The stratum granulosum was characterized by enlarged, frequently irregularly shaped keratohyaline granules.

DISCUSSION

The leukoplakic lesion of the prepuce reported here is characterized by the typical histologic features of epidermolytic hyperkeratosis. This finding is confirmed by the ultrastructural features of the same biopsy specimen showing irregularly formed and haphazardly arranged tonofilaments which is characteristic for epidermolytic hyperkeratosis in other skin diseases (4). Similar histologic and ultrastructural alterations of the epidermis have recently been described in leukoplakic lesions of the vermilion border of the lip and have been called epidermolytic leukoplakia (2, 3, 5). Because of their localiza-

tion, the development of these lesions has been attributed to chronic sun damage of the vermilion. The present data, however, demonstrate that this rare disorder may also occur in the non sun exposed preputial epidermis.

The malignant potential of leukoplakic lesions with epidermolytic hyperkeratosis is still controversial. Ackerman & Reed (2) observed marked atypia of the basal keratinocytes in the epidermolytic leukoplakia of the lip and considered the lesion a rare form of actinic cheilitis. In contrast, the cases published more recently by Vakilzadeh & Happle (3) showed discrete dysplastic abnormalities only on ultrastructure (5). Similarly, the present epidermolytic leukoplakia of the prepuce exhibits some enlarged nuclei in the lower epidermal cell layers, but there is no marked nuclear atypia clearly classifying the lesion as precancerous disorder.

REFERENCES

1. Ackerman AB. Histopathologic concept of epidermolytic hyperkeratosis. *Arch Dermatol* 1970; 102: 253.
2. Ackerman AB, Reed RJ. Epidermolytic variant of solar keratosis. *Arch Dermatol* 1973; 107: 104.
3. Vakilzadeh F, Happle R. Epidermolytic leukoplakia. *J Cutan Pathol* 1982; 9: 267.
4. Wilgram GS, Caulfield IB. An electron microscopic study of epidermolytic hyperkeratosis. *Arch Dermatol* 1966; 94: 127.
5. Kolde G, Vakilzadeh F. An ultrastructural study of epidermolytic leukoplakia. *Arch Dermatol Res* 1983; 275: 86.