

## Giant Basal Cell Carcinoma with Metastasis and Secondary Amyloidosis: Report of Case

HANS-IVER BECK, JØRGEN ARRESKOV ANDERSEN,  
NIELS ERIK BIRKLER and PETER D. OTTOSEN

*Department of Medicine, Thisted Sygehus, DK-7700 Thisted, Denmark,  
The Radium Center for Jutland and the University Institute of Pathology, Aarhus  
Kommunehospital, DK-8000, Aarhus C, Denmark*

Beck H-I, Andersen JA, Birkler NE, Ottosen PD. Giant basal cell carcinoma with metastasis and secondary amyloidosis: Report of case. *Acta Derm Venereol (Stockh)* 1983; 63: 564-567.

Basal cell carcinoma of the skin is a slow growing relatively benign tumor usually located on the head and neck. Although rare, metastasis to lymph nodes or parenchymatous organs has been reported previously (1-9). We wish to add another case of metastasizing basal cell carcinoma of the skin, which presented certain unique features only rarely reported (1), namely complicating amyloidosis in the kidneys, the lymph nodes, the spleen and probably in the intestinal canal. *Key words: Basal cell carcinoma; Metastasis; Amyloidosis; Lymph nodes; Kidneys; Spleen.* (Received April 13, 1983.)

H.-I. Beck, Department of Dermatology, Marselisborg Hospital, 8000 Aarhus C, Denmark.

### CASE REPORT

The patient was a 59-year-old Caucasian woman who came to the department in December 1981 because of continuous diarrhoea. Physical examination showed a large, rodent ulcer on her back, which had been present since 1957. It was known to have measured 5 × 5 cm in 1968, and at the time of admission it measured 40 × 30 cm. The ulcer was located at the lower right part of the back, it was very necrotic and purulent with obvious secondary bacterial infection. Very hard and slightly enlarged inguinal lymph nodes were present on both sides. There was no hepato-splenomegaly, but severe oedema of both legs (Fig. 1).

Laboratory tests showed severe anemia 3.7 mmol/l (7.3-9.7 mmol/l) and a raised serum-creatinine 296 mmol/l (53-87 mmol/l). Electrolyte values were normal. Serum electrophoresis did not show any elevated gamma-globulin or paraprotein but hypoalbuminemia. There was heavy proteinuria and hyaline casts in the urine. Intravenous pyelography showed no nephrograms. Further radiological examination showed no tumor in the lungs or colon. Cultures of the ulcer grew  $\beta$ -hemolytic streptococci, *Proteus* and *Pseudomonas*. Numerous biopsies from the ulcer showed classical basal cell carcinoma (Fig. 2).

The patient was treated with antibiotics, diuretics, blood transfusions and plasma. She developed a rapidly progressive nephrotic syndrome and died in February 1982 in uremia.

### Autopsy

At the autopsy the patient showed a large, heavily infected rodent ulcer on the back. She had several hard and indurated lymph nodes in both inguinal regions. The kidneys were enlarged and very pale and on the cut surface the cortex was almost white, and showed strongly positive reaction for amyloid after treatment with iodine. The spleen was also enlarged and showed macroscopic signs of amyloidosis. Apart from the enlarged lymph nodes in the inguinal regions there was no sign of metastasis.

### Microscopy

Tissue from the tumor on the back showed a characteristic basal cell carcinoma with invasion of the underlying dermis and subcutaneous tissue. There were no spinocellular differentiation in the tumor and no keratinization (Fig. 2). Microscopy of the inguinal lymph nodes showed extensive fibrosis with nests and groups of tumor cells showing the same features as the primary skin tumor with little or no preservation of the normal lymph node structure (Fig. 3). Extensive amyloidosis as shown by heavy staining with Congo-red was present in the kidneys, spleen and lymph nodes. In the kidneys the capillary tuft in practically all glomeruli was obliterated with amyloid (Fig. 4). There was a clear green birefringence on polarization microscopy. Also the spleen shows microscopic signs of amyloidosis but there was nothing in the liver, and especially not in the primary tumor. Electron microscopy of renal

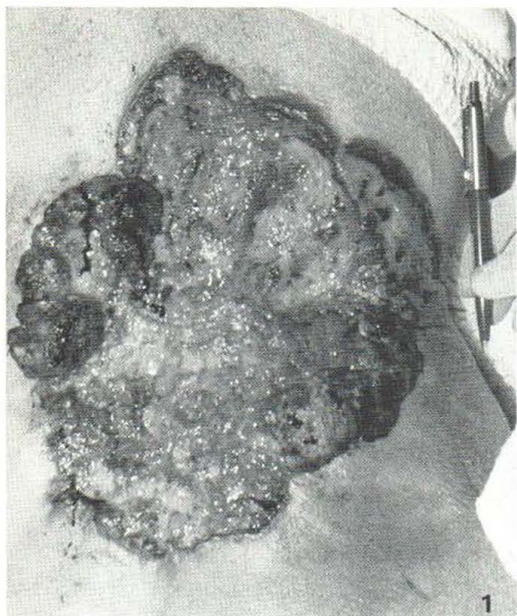
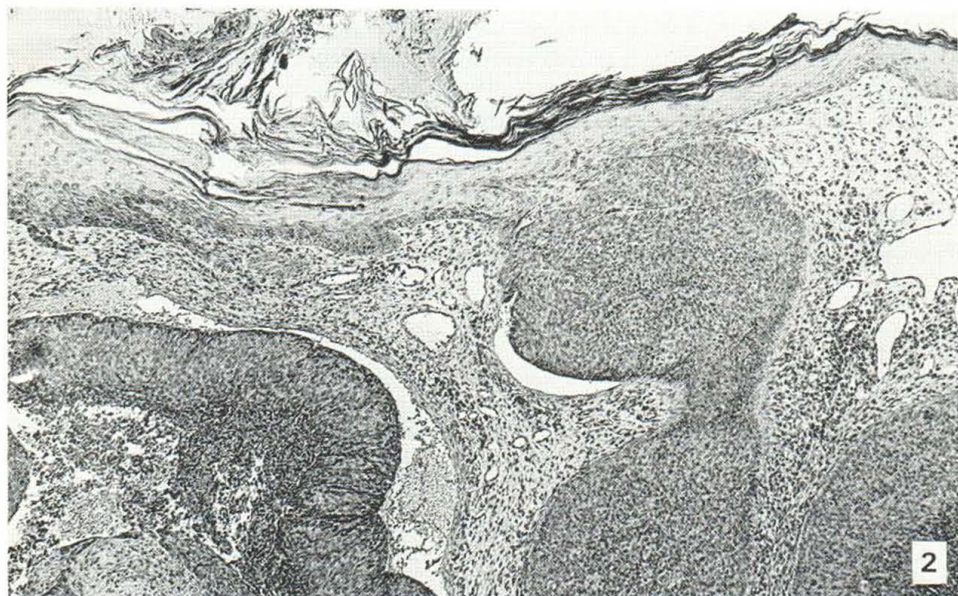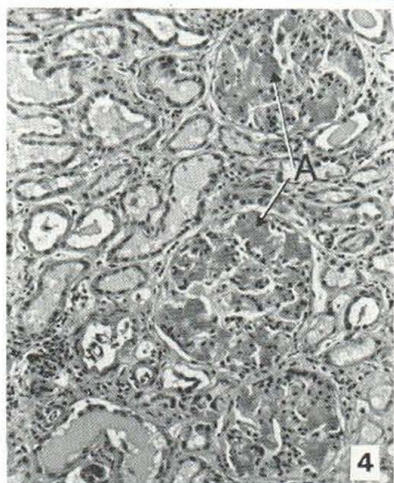
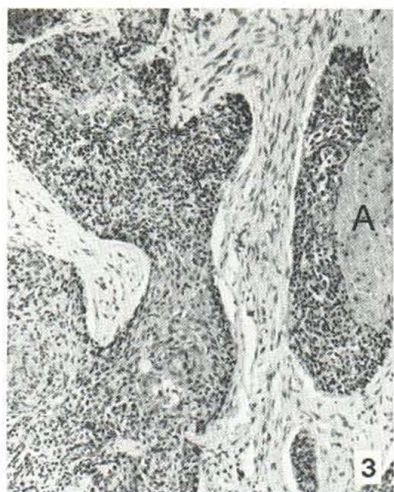


Fig. 1. Rodent ulcer on the back of the patient.

Fig. 2. Biopsy from tumor on the back showing the characteristic growth pattern of a nodular-cystic basal cell carcinoma with nests of tumor cells penetrating into the dermis. The epidermis is seen in upper part of figure ( $\times 60$ ).

Fig. 3. Tissue from inguinal region removed at the autopsy. It contains metastasis from the basal cell carcinoma. There is severe fibrosis and an area with amyloid (A) is seen in the right part of the figure ( $\times 120$ ).

Fig. 4. Renal cortical tissue removed at the autopsy. Three glomeruli with heavy amyloidosis (A) are seen ( $\times 200$ ).





cortex showed extensive amyloidosis in the glomerular basement membrane. Thus, tightly packed fibrillar substructures characteristic of amyloid precipitate were present.

## DISCUSSION

The primary skin tumor shows morphological characteristics corresponding to a basal cell carcinoma, and the close resemblance between this tumor and the tumor tissue in the inguinal lymph nodes demonstrates a case of metastasizing basal cell carcinoma.

Basal cell carcinoma is the most common skin cancer accounting for 65–75% of all cutaneous carcinomas (9). Metastasis is rare, the incidence is established to be 0.1% (4). Giant basal cell carcinomas with metastasis are even more rare, about 100 have been reported (3, 5, 8, 9). Metastasis is most frequently found in the regional lymph nodes (68% (3)), but metastasis to the skin, brain, liver, lungs, spleen, bone and bone marrow with anemia has been reported (2–5, 7, 8). Late metastasis has been reported to occur from 7–43 years after the primary tumor (4) and when appearing it has a bad prognosis since the medium survival time is only 10 months (3).

Although the patient in the present case had metastasizing skin cancer she died from another complication, namely rapidly progressing nephrotic syndrome and severe deterioration in kidney function. At the autopsy the kidneys showed extensive amyloidosis, a classical cause of secondary nephrotic syndrome.

When amyloidosis occurs in conjunction with other chronic diseases it is generally classified as secondary amyloidosis. In the present case there can be little doubt that the amyloid precipitates in the kidney, spleen and lymph nodes were secondary to the large and heavy infected skin cancer. Thus, there was not clinical or laboratory evidence of plasma cell myeloma, pulmonary tuberculosis, ulcerative colitis or amyloid infiltration of cutaneous, mucocutaneous or subcutaneous tissues.

Secondary amyloidosis as a complication to skin diseases has been reported in certain dermatoses such as hidradenitis suppurativa, stasis ulcers, psoriatic arthritis, dystrophic epidermolysis bullosa, lepromatous leprosy and has to our knowledge only been reported once before in association with basal cell carcinoma (1).

Unfortunately the intestines were not microscopically examined, but the patient's continuous diarrhoea was most likely caused by secondary amyloidosis in the intestine.

The present case report thus shows a case of long-standing untreated basal cell carcinoma, which slowly grew for 25 years and then caused severe renal amyloidosis resulting in death. It is not unlikely that if the primary tumor had been treated with surgery and radiation, the patient would not have developed secondary renal amyloidosis.

## ACKNOWLEDGEMENT

For preparing the manuscript we are indebted to Lene Lyck Poulsen.

## REFERENCES

1. Brownstein MH, Helwig EB. Systemic amyloidosis complicating dermatoses. *Arch Dermatol* 1970; 102: 1–7.
2. Coletta DF, Haentze FE, Thomas CC. Metastasizing basal cell carcinoma of the skin with myelophthisic anemia. *Cancer* 1968; 22: 879–884.
3. Constanza ME, Dayal Y, Binder S, Nathanson L. Metastatic basal cell carcinoma: Review, report of a case, and chemotherapy. *Cancer* 1974; 34: 230–235.
4. Cotran RS. Metastasizing basal cell carcinomas. *Cancer* 1961; 14: 1036–1040.
5. Curry MC, Winkelmann RK. Giant basal cell carcinoma. *Arch Dermatol* 1977; 113: 316–319.

6. Farmer ER, Helwig EB. Metastatic basal cell carcinoma: A clinicopathologic study of seventeen cases. *Cancer* 1980; 46: 748–757.
7. Lattes R, Kessler RW. Metastasizing basal cell epithelioma of the skin. *Cancer* 1951; 4: 866–877.
8. Lildholdt T, Søgård H. Metastasizing basal cell carcinoma. *Scand J Plast Reconstr Surg* 1975; 9: 170–173.
9. Wermuth BM, Fajardo LF. Metastatic basal cell carcinoma. *Arch Pathol* 1970; 90: 458–462.