

## Concomitant Immunohistochemical Characteristics of Pemphigoid and Dermatitis herpetiformis in a Patient with Atypical Bullous Dermatosi

M. C. J. M. DE JONG,<sup>1</sup> J. B. VAN DER MEER,<sup>2</sup> J. A. M. DE NIJS<sup>3</sup> and S. C. J. VAN DER PUTTE<sup>4</sup>

<sup>1</sup>Department of Dermatology, State University Hospital, Groningen, <sup>2</sup>Department of Dermatology, Medical Centre, Leeuwarden, <sup>3</sup>Department of Dermatology, Zeister Hospital, Zeist, and <sup>4</sup>Institute of Pathology, State University of Utrecht, Utrecht, The Netherlands

de Jong MCJM, van der Meer JB, de Nijs JAM, van der Putte SCJ. Concomitant immunohistochemical characteristics of pemphigoid and dermatitis herpetiformis in a patient with atypical bullous dermatosis. *Acta Derm Venereol (Stockh)* 1983; 63: 476-482.

We report a patient who developed a vesiculobullous eruption which clinically and histologically showed features of pemphigoid and dermatitis herpetiformis, responded to prednisone but doubtfully to dapsone, and demonstrated 'classical' immunopathologic characteristics of pemphigoid and dermatitis herpetiformis. Peribullous and unaffected skin featured deposition of IgG and C3c in a homogeneous-linear pattern at the epidermal basement membrane, while the unaffected skin demonstrated concomitantly granular IgA deposits in the dermal papillae. Circulating IgG class anti-basement membrane antibody was found in a titre of 1:80 when using guinea-pig oesophagus, and of 1:320 when using human oral mucosa as antigenic substrate. Our findings add another piece to the puzzle that continues to stimulate discussion among dermatologists as how to classify patients with overlapping features of pemphigoid and dermatitis herpetiformis. (Received February 18, 1983.)

M. C. J. M. de Jong, Department of Dermatology, Oostersingel 59, 9713 EZ Groningen, The Netherlands.

The detection of granular IgA deposits in the tips of dermal papillae ('papillary' IgA) in patients with bullous dermatosis is the most reliable way of establishing the diagnosis dermatitis herpetiformis (14, 19, 20, 22). In the same way, linear *in vivo* deposition of IgG at the epidermal basement membrane, together with circulating IgG class anti-basement membrane antibody in the serum of patients with bullous lesions, is diagnostic of pemphigoid (2, 5, 13, 18).

It has been claimed, however, that in individual patients it is occasionally difficult to decide whether they have pemphigoid or dermatitis herpetiformis (4, 10, 11, 12). This problem has been complicated by the finding of homogeneous-linear IgA deposition in the uninvolved skin of adults with subepidermal blistering, combining the linearity of the staining pattern in pemphigoid with the IgA class of the deposits typical of dermatitis herpetiformis. Recently, it has been proposed that for the time being the term 'adult linear IgA disease' should be used to distinguish these patients from those with granular, papillary IgA deposits (16).

We now report our findings in a patient with an atypical bullous dermatosis which, unlike previously reported cases, showed the 'classical' immunopathologic characteristics of both pemphigoid and dermatitis herpetiformis.

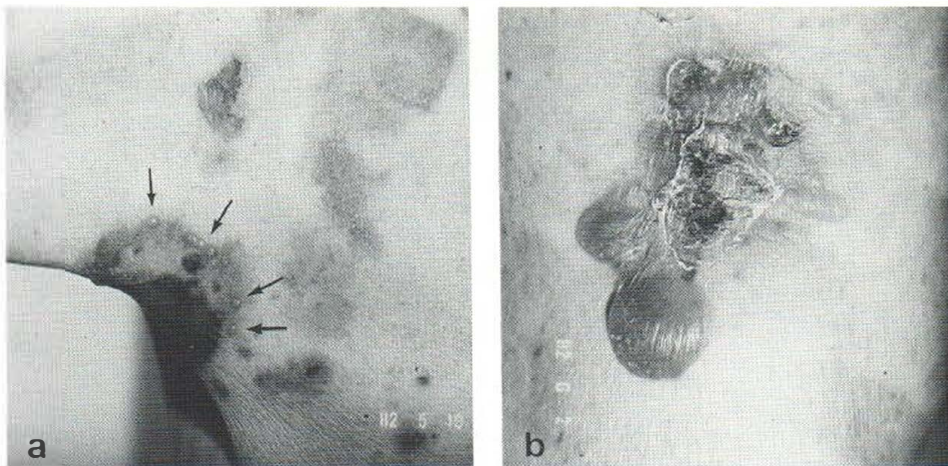


Fig. 1. (a) The right axillary region. Note the more or less grouped vesicles at the periphery of a healing lesion. (b) Flaccid bullae on the flexor surface of the right knee.

## CASE REPORT

A man aged 79 years presented in 1982 with a 13-month history of an itchy eruption over the neck, shoulders, axillae, arms, buttocks and legs. Examination showed erosions, flaccid bullae with sparse erythema and healing lesions (Fig. 1 b). In the right axillary region, grouped vesicles around a healing lesion were seen as well (Fig. 1 a). The oral mucosa was normal. Nikolsky's sign was negative. Routine hematological and biochemical investigations showed no abnormalities, except for an initial ESR of 38 mm/h. Anti-nuclear antibodies, including anti-dsDNA, were negative.

Treatment was initiated at 150 mg dapsone (DDS) per day for one week. This was to no avail. The rash did not disappear following the administration of prednisone 60 mg daily, but regressed on increasing the dose to 80 mg daily. A further course of dapsone was given at a later stage. Withdrawal of dapsone after this second course has not led to exacerbation of the eruption at a critical dose of prednisone.

### Histopathology

Skin biopsies were taken in February, March and May. All showed subepidermal bulla formation. The dermal changes, however, were different. The first biopsy demonstrated the presence of many eosinophils within the blister, but also in the sub-bullous and adjacent peribullous areas (Fig. 2 a). These cells were diffusely scattered and, together with lymphocytes, grouped around blood vessels as well. This picture is consistent with the polymorph variety of pemphigoid (8, 17, 20). The second biopsy revealed the presence of numerous neutrophils in the blister cavity and beneath the floor of the blister (Fig. 2 c). However, micro-abscesses characteristic of dermatitis herpetiformis were not seen.

The third biopsy could essentially be characterized as "infiltrate-poor", with a monolayer of cells along the dermo-epidermal junction as seen in the monomorph variety of pemphigoid (Fig. 2 b).

### Jejunal biopsy

In the biopsy of the jejunum, no villi were observed. The stroma appeared edematous and contained increased numbers of lymphocytes, plasma cells and eosinophils. Thus a picture of total villous atrophy was evident, such as can be found in dermatitis herpetiformis.

### HLA typing

HLA antigens detectable on the surface of the patient's lymphocytes included: All, Aw19 (A29), B12 (Bw44), B15 (Bw62), Dr1, Dr4. HLA-B8 antigen was absent. Allo-antibodies and auto-antibodies against the patient's lymphocytes were not demonstrable.

## IMMUNOFLUORESCENCE PROCEDURES (IF)

### Skin biopsies

Five punch biopsy specimens were examined. Three of these were obtained on 10th May and included one biopsy from uninvolved skin, dorsal wrist, and two perilesional biopsies from the edge of bullous

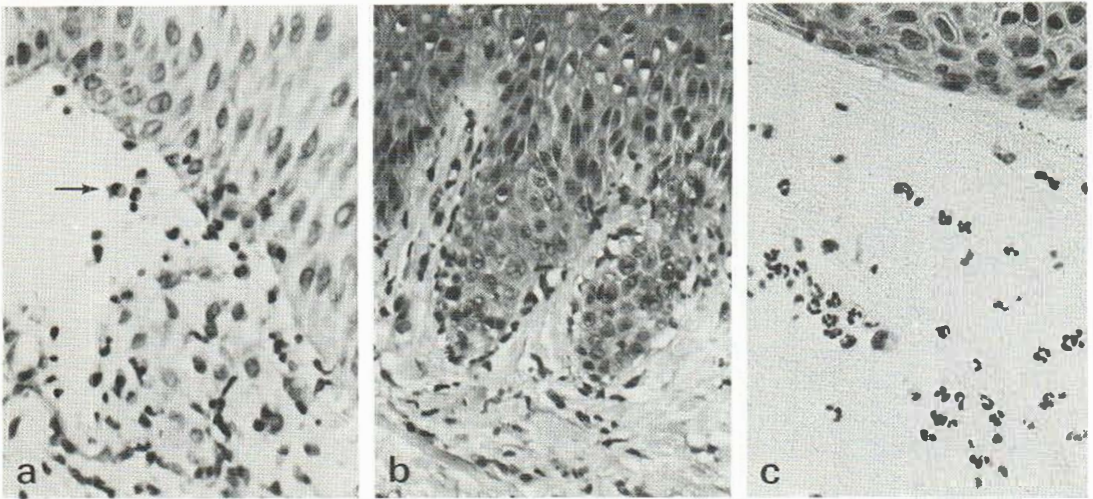


Fig. 2. (a) The edge of a bullous lesion showing subepidermal blistering and many eosinophils (arrow) consistent with polymorph pemphigoid. (b) Peribullous region of an infiltrate-poor lesion: note monolayer of cells at the dermo-epidermal junction, characteristic of monomorph pemphigoid. (c) Bullous/peribullous region containing neutrophils. Although micro-abscesses seem to be absent, the picture is suggestive of dermatitis herpetiformis.

skin, upper arm. The patient had two additional biopsies taken on 16th July, from uninvolved skin, elbow region. The biopsies were obtained under local ethylchloride anaesthesia and processed as previously described (6, 23). For direct IF detection of various plasma protein components we used the following FITC-labelled conjugates: goat anti-human IgG (1 : 32), IgM (1 : 40) and IgA (1 : 60) with monospecificity for heavy Ig chain determinants (Kallestad, Minnesota); rabbit anti-human kappa and lambda light Ig chains (1 : 25), monospecificity established on bone marrow preparations (Dako, Copenhagen); rabbit anti-human C3c (1 : 25) (Dako, Copenhagen); rabbit anti-human C1q (1 : 16) and anti-human fibrinogen (1 : 32) (Behring Diagnostica, W. Germany). The anti-IgG and anti-IgM consisted of F(ab')<sub>2</sub>-labelled antibody fragments. The molar F/P ratio of conjugates varied between 1.65 and 2.3. Working dilutions, indicated in parentheses, were prepared in PBS (0.01 M, pH 7.3) supplemented with BSA 2%.

#### Serum auto-antibodies

Circulating antibodies to epithelial basement membrane (anti-BM as found in pemphigoid) and to intercellular substance (anti-ICS as found in pemphigus) were detected by indirect IF (3) using fresh, unfixed guinea-pig oesophagus, and human oral mucosa as substrates. For indirect IF the goat anti-human IgG, IgM, IgA conjugates listed above were used at a final antibody concentration of 20–30 µg/ml.

#### Fluorescence microscopy

Stained cryostat sections were mounted in phosphate-buffered glycerol (1 : 1, pH 7.3) and examined under a Leitz Orthoplan-Orthomat photomicroscope fitted with a 75W/2 xenon arc and vertical illuminator for incident-light excitation (7).

## IMMUNOFLUORESCENCE RESULTS

#### Serum auto-antibodies

The presence of circulating anti-BM antibody in the patient's serum was most clearly demonstrated on human oral mucosa and less so on guinea-pig oesophagus, yielding titres of 1 : 320 and 1 : 80 respectively. The antibody proved to be of IgG class, yielding negative staining for IgA and IgM class. Anti-ICS antibody was not detectable.

#### Skin biopsies

(1) May 1982. Serial sections of perilesional skin specimens showed blister formation at the dermo-epidermal junction. Foci of homogeneous-linear IgG and C3c deposition were

found both in the roof and on the floor of the blister. Occasionally foci of microgranular IgA deposits were observed in the superficial dermis constituting the floor of the blister. Negative staining reactions were obtained for IgM and Clq, in contrast to the granular staining at the dermo-epidermal junction in positive control skin samples from patients with SLE. The results of direct IF in unaffected skin are presented in Table I (left) and in Fig. 3 (*a, b, c*). The presence of homogeneous-linear IgG and C3c at the epidermal basement membrane, in conjunction with granular IgA and fibrinogen in the dermal papillae, was a constant finding. The IgA deposits were apparently localized beneath the basement membrane zone, as judged from the staining pattern observed with the anti-Ig light chain conjugates. The latter yielded two concomitant patterns: a homogeneous-linear fluorescence pattern at the epidermal basement membrane, as distinct from additional granular staining in the subepidermal compartment. Moreover, preliminary studies using double IF staining for IgA, IgG and laminin showed the presence of green fluorescent IgA deposits beneath the red-staining lamina lucida, whereas the IgG deposits appeared as a single yellow-orange band overlapping with the lamina lucida.

(2) July 1982. Two biopsies from unaffected skin were examined. The results are presented in Table I (right) and in Fig. 3 (*d, e, f*). There were no apparent differences between staining patterns in the two biopsies. The staining patterns for IgA, C3c and fibrinogen were comparable to those described above. Linear staining for IgG was most conspicuous, however, at the basement membrane of a hair follicle, whereas deposits of granular appearance predominated in the papillary region. None of the five biopsies was ever found to demonstrate homogeneous-linear deposition of IgA at the dermo-epidermal junction.

## DISCUSSION

According to clinical and histopathologic criteria our patient had a subepidermal vesiculo-bullous dermatosis sharing features of pemphigoid and dermatitis herpetiformis. The age at onset, flaccid bullae, infiltrate-poor and eosinophil-rich histology, prednisone responsiveness and HLA-B12, B15 haplotype were more consistent with pemphigoid, whereas the

Table 1. Direct immunofluorescence of skin biopsy specimens

In vivo deposit	May 1982 Unaffected skin, dorsal wrist		July 1982 Unaffected skin, right elbow	
	EBM <sup>a</sup>	DP <sup>b</sup>	EBM	DP
IgG	+++ lin. <sup>c</sup>	—	-/++ lin. <sup>c</sup>	+++ gran.
IgA	—	+++ gran. <sup>d</sup>	—	+++ gran.
IgM	—	—	—	—
k-LC	++ lin.	++ gran.	—	++ gran.
λ-LC	+ lin.	±/+ gran.	—	+ gran.
C3c	+++ lin.	—	+++ lin.	—
Clq	—	—	—	—
Fib	—	++ gran.	—	++ gran.

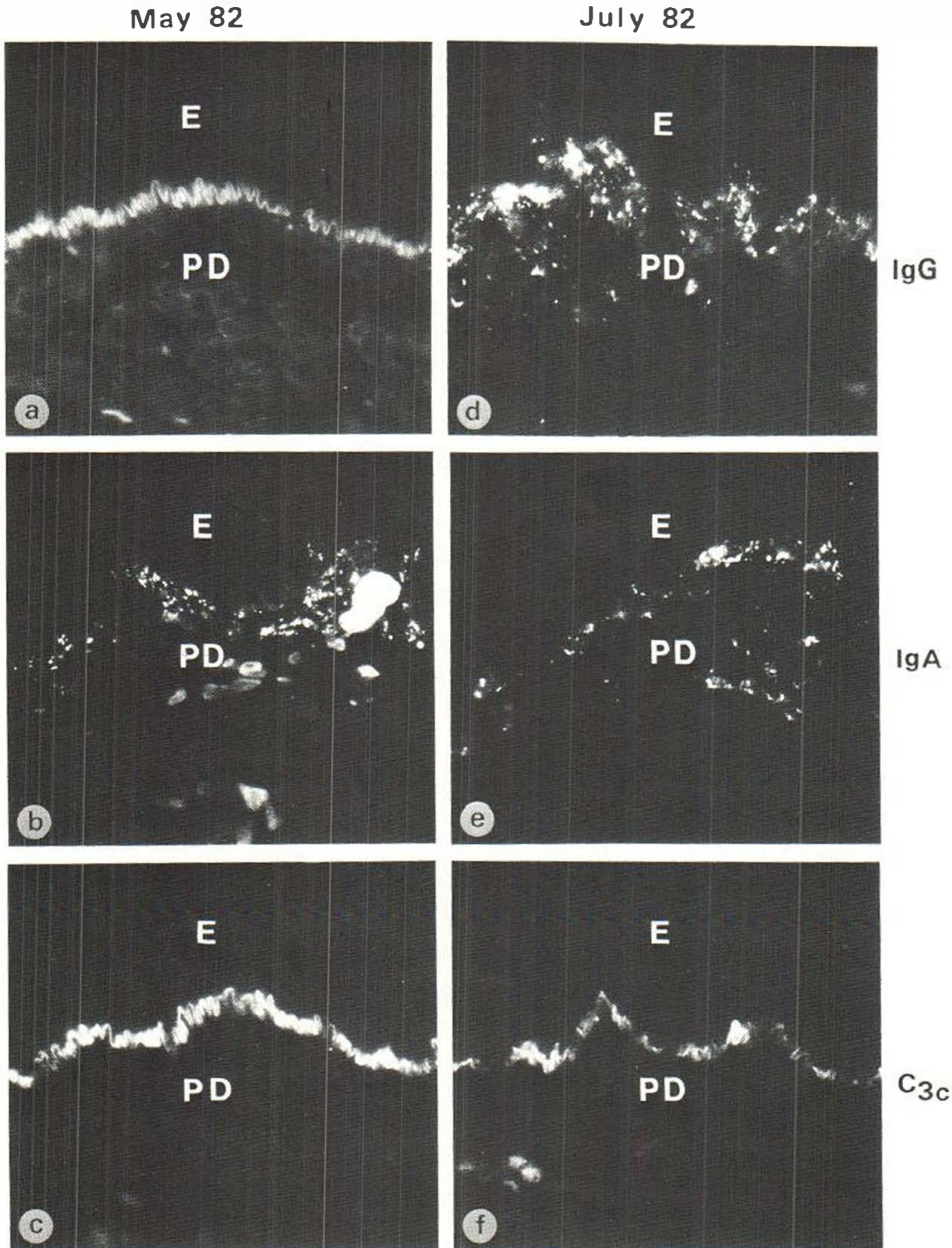
<sup>a</sup> EBM = epidermal basement membrane.

<sup>b</sup> DP = dermal papillae.

<sup>c</sup> lin. = linear deposit type as illustrated in Fig. 2*a*.

<sup>d</sup> gran. = granular deposit type as illustrated in Fig. 2*b*.

<sup>e</sup> ++ linear staining was seen only at the EBM of a hair follicle present in some of the serial sections studied.



*Fig. 3.* Direct IF staining reactions in cryostat sections of unaffected skin (*a, b, c*, 5th May; *d, e, f*, 16th July). (*a*) Linear IgG deposition along the epidermal basement membrane (EBM) in conjunction with (*b*) IgA deposits of microgranular and granular appearance in flatly outlined papillary region, and (*c*) linear C3c staining of the EBM. These are characteristics of both pemphigoid and dermatitis herpetiformis. Skin specimens obtained 2½ months later showed essentially the same deposition pattern, although linear IgG was most conspicuous at the EBM of a hair follicle (not shown) as opposed to (*d*) predominantly granular IgG deposition in the dermal papillae. All photomicrographs are at the same magnification ( $\times 50$ ). *E* = epidermis. *PD* = papillary dermis.

pruritus, grouped vesicles, neutrophil-rich histology and jejunal pathology were more in keeping with dermatitis herpetiformis.

In such cases differentiation often can be made on the basis of immunopathologic criteria (see introduction). Thus, most of the atypical cases described as either polymorph or vesicular pemphigoid could be classified as such on the basis of homogeneous-linear IgG deposition at the EBM zone and/or the presence of circulating IgG class anti-basement membrane antibody (1, 10, 11). However, in a minority of patients with subepidermal blistering the situation has been confused rather than clarified by the finding of homogeneous-linear IgA deposition at the dermo-epidermal junction in uninvolved skin. Different opinions have been expressed as to the interpretation of linear IgA deposits, particularly in relation to the linear IgG/C3 pattern in pemphigoid and the granular, papillary IgA profile in dermatitis herpetiformis (12, 15, 21, 22). Since patients with linear IgA deposits may not form a homogeneous group, the provisional term 'adult linear IgA disease' has been proposed until there is more certainty about the true nature of the disease or diseases (16).

The immunopathologic findings in our patient do not fit in this category. The homogeneous-linear IgG and C3c profile together with the presence of circulating IgG class anti-basement membrane antibody favour pemphigoid, whereas the granular, papillary IgA and fibrinogen deposits are in keeping with dermatitis herpetiformis. The application of double red and green immunofluorescence (9) proved very helpful in distinguishing two sites of immunoglobulin deposition: staining for IgG was found to coincide with staining for laminin, whereas the IgA fluorescence was localized beneath the lamina lucida (unpublished observation).

To the best of our knowledge<sup>1</sup> only one study has appeared that includes patients (only one out of 50) in whom linear IgG+IgM and papillary IgA were found in the same skin biopsy (22). However, this patient, unlike our patient, had no circulating anti-basement membrane antibody. Very recently another atypical immunohistologic profile has been found in a patient initially diagnosed as having dermatitis herpetiformis (4). Direct IF studies showed a dermatitis herpetiformis-like and, later, an atypical granular band instead of a linear band as seen in pemphigoid. The immunoglobulin (IgG) composition, however, was pemphigoid-like in that no IgA was seen.

We are convinced that in the near future more of such atypical and mixed immunohistologic profiles will be recognized. For the time being it seems best to describe carefully all such cases rather than to speculate about the possibility of overlap between disease entities of which the pathophysiology is still poorly understood.

## REFERENCES

1. Bean SF, Michel B, Furey NL, Thorne EG, Meltzer L. Vesicular pemphigoid. *Arch Dermatol* 112: 1402, 1976.
2. Beutner EH, Lever WF, Witebsky E, Jordon RE, Chertock B. Autoantibodies in pemphigus vulgaris. *J Am Med Assoc* 192: 682, 1965.
3. Beutner EH, Nisengard RJ, Kumar V. Defined immunofluorescence: Basic concepts and their application to clinical immunodermatology. In: *Immunopathology of the Skin* (ed. E. H. Beutner, T. P. Chorzelski & S. F. Bean), p. 29. Wiley Medical Publications, 1979.
4. Burnham TK, Nims LP. Case for diagnosis: Vesicular pemphigoid? Immunofluorescence microscopy studies. *Arch Dermatol* 118: 506, 1982.
5. Cormane RH, Szabò E. Immunohistopathology of the skin in pemphigoid. *Br J Dermatol* 83: 435, 1970.

<sup>1</sup> Very recently another patient with mixed IF features of DH and BP has been documented by Jolliffe and Sarkany (*Clin. Exp. Dermatol.* 8: 113, 1983).

6. De Jong MCJM, Doeglas HMC, Dijkstra JWE. Immunohistochemical findings in a patient with penicillamine pemphigus. *Br J Dermatol* 102:333, 1980.
7. De Jong MCJM, Walstra CM. Immunofluorescent localization of antithrombin III in human skin. *Br J Dermatol* 106:281, 1982.
8. Eng AM, Moncada B. Bullous pemphigoid and dermatitis herpetiformis. Histopathologic differentiation of bullous pemphigoid and dermatitis herpetiformis. *Arch Dermatol* 110:51, 1974.
9. Gammon WR, Robinson T, Briggaman RA, Wheeler CE. Double immunofluorescence microscopy: a method for localizing immune deposits in skin disease associated with linear basement membrane zone immunofluorescence. *J Invest Dermatol* 79:312, 1982.
10. Honeyman JF, Honeyman A, Lobitz WC, Storrs FJ. The enigma of bullous pemphigoid and dermatitis herpetiformis. *Arch Dermatol* 106:22, 1972.
11. Honeyman JF, Robles Honeyman A, De la Parra MA, Pinto A, Eguiguren GJ. Polymorphic pemphigoid. *Arch Dermatol* 115:423, 1979.
12. Jablonska S, Chorzelski TP, Beutner EH, Maciejowska E, Rzesza G. Dermatitis herpetiformis and bullous pemphigoid. *Arch Dermatol* 112:45, 1976.
13. Jordon RE, Beutner EH, Witebsky E, Blumenthal G, Hale WL, Lever WF. Basement zone antibodies in bullous pemphigoid. *J Am Med Assoc* 200:751, 1967.
14. Katz SI, Strober W. The pathogenesis of dermatitis herpetiformis. *J Invest Dermatol* 70:63, 1978.
15. Lawley TJ, Strober W, Yaoita H, Katz SI. Small intestinal biopsies and HLA types in dermatitis herpetiformis patients with granular and linear IgA skin deposits. *J Invest Dermatol* 74:9, 1980.
16. Leonard JN, Haffenden GP, Ring NP, McMinn RHH et al. Linear IgA disease in adults. *Br J Dermatol* 107:301, 1982.
17. Lever WF. Pemphigus and Pemphigoid, p. 85. Charles C. Thomas Publ., Springfield, Illinois, 1965.
18. Lever WF. Pemphigus and pemphigoid. *J Am Acad Dermatol* 1:2, 1979.
19. van der Meer JB. Granular deposits of immunoglobulins in the skin of patients with dermatitis herpetiformis. An immunofluorescent study. *Br J Dermatol* 81:493, 1969.
20. van der Meer, JB. Dermatitis Herpetiformis: A Specific (Immunopathologic?) Entity. Thesis 1972. State University of Utrecht. Kooykers Bookshop, P.O. Box 24, Leiden, The Netherlands.
21. Russel Jones, R, Goolamali SK. IgA bullous pemphigoid: a distinct blistering disorder. *Br J Dermatol* 102:719, 1980.
22. Seah PP, Fry L. Immunoglobulins in the skin in dermatitis herpetiformis and their relevance in diagnosis. *Br J Dermatol* 92:157, 1975.
23. Terpstra H, De Jong MCJM, Klokke AH. In vivo bound pemphigus antibodies in a stillborn infant. *Arch Dermatol* 115:316, 1979.