

The Prevalence of Dermatophyte Infections in Hereditary Palmo-Plantar Keratoderma

P. GAMBORG NIELSEN

Department of Dermatology, Central Hospital, Boden, Sweden

Gamborg Nielsen P. The prevalence of dermatophyte infections in hereditary palmo-plantar keratoderma. *Acta Dermato Venereol (Stockh)* 1983; 63: 439-441.

The prevalence of dermatophyte infections in hereditary palmo-plantar keratoderma of the Unna Thost variety was investigated. Sixty patients, who represented 7.5% of a well defined population, participated in the study. The prevalence was found to be about 40%. At the same time the correlation between direct microscopic examination and conventional culture methods was shown to be 88.5%. (Received December 21, 1982.)

P. Gamborg Nielsen, Department of Dermatology, Central Hospital, S-96185 Boden, Sweden.

The occurrence of hereditary palmo-plantar keratoderma is very low in most parts of the world, but in the northernmost county of Sweden (Norrbotten) the incidence among school children was found to be 0.55% (2). Patients with this disorder generally develop a diffuse hyperkeratosis on palms and soles of the type described as the Unna Thost variety (9). For various reasons this disorder creates favourable conditions for dermatophyte growth, and it has been proved that the incidence of dermatophyte infections in hereditary palmoplantar keratoderma is 50-60% (3, 5). Therefore, it was found of interest to investigate the prevalence of dermatophyte infections in this inherited disorder.

MATERIAL AND METHODS

The number of inhabitants of the northernmost county of Sweden (Norrbotten) was 267,000 at the end of 1981. This investigation was performed in a well defined population consisting of 144,000 persons living in a relatively densely populated area called the 'quadrangle' (Fig. 1). As the incidence of hereditary palmo-plantar keratoderma was found to be 0.55% it was expected that about 800 persons in this area would suffer from the disease. From the material of the previously performed investigation on the incidence of hereditary palmo-plantar keratoderma among schoolchildren in 1959, 60 (7.5%) randomly selected patients were invited to visit the clinic. The only criterion for entering the actual study was that the patients had not consulted a doctor about their inherited disorder.

From the 1st to the 5th of November, 1982, 60 patients (30 women and 30 men) average age 34 years (9-67 years) were investigated for dermatophytes on their palms and soles. Specimens for direct microscopic examination were collected from palms and soles by use of a curette and placed on a clean slide stained with Schwartz-Lampkins staining solution (8). A coverglass slip was gently placed on the preparation, which was then allowed to stand for 15 minutes before examination.

● On the same occasion, material was inoculated on Sabouraud's glucose agar without cycloheximide poured into Petri dishes, and incubated at 27°C. Before specimens were taken the hyperkeratotic areas were washed with ethanol-ether to prevent the growth of contaminants (6, 7). Cultures were read every week for 3 weeks, after which they were discarded. Assessment was performed by examination with the naked eye from the front and back sides of the dishes, and by microscopic examination of material collected with adhesive tape from the culture. The tape was placed on a clean slide stained with Lactophenol-Cotton blue before the identification of fungi was performed (1).

RESULTS

The first appearance of hereditary palmo-plantar keratoderma in this material was at an average age of $5\frac{1}{2}$ years (0-13 years) 47/60 (78.2%) showed a diffuse homogeneous hyperkeratosis with distinct demarcation from non-affected skin and 13/60 (21.8%) had a border of hyperkeratotic papules towards normal skin. Pad-like keratoses on the knuckles

Table I. Distribution of fungi and the correlation between direct microscopic examination and conventional culture in a prevalence study on dermatophyte infections in hereditary palmo-plantar keratoderma (60 patients)

Conventional culture	(%)
DERMATOPHYTES	22/60 (36.7)
Total positive cultures from hands and feet	26/60 (43.3)
From the hands	4/26 (16.2)
From the feet	22/26 (83.8)
<i>Trichophyton rubrum</i>	10/26 (38.5)
<i>Trichophyton mentagrophytes</i> }	9/26 (35.6)
<i>Trichophyton verrucosum</i>	
<i>Epidermophyton floccosum</i>	7/26 (26.9)
YEAST SPECIES*	4/60 (6.7)
Group 1	2/4 (50.0)
Group 2	2/4 (50.0)
Group 3	0/4 (00.0)
SAPROPHYTIC FUNGI (extremely scanty growth)	10/60 (16.7)
Penicillium species	3/10 (30.0)
Aspergillus species	2/10 (20.0)
<i>Rhodotorula rubra</i>	2/10 (20.0)
Alternaria, Fusarium and Mycelium sterile	3/10 (30.0)
Direct microscopic examination	
Total positive direct microscopic examinations from hands and feet	28/60 (46.7)
From the hands	4/28 (14.3)
From the feet	24/28 (85.7)
Correlatin between culture and direct microscopic examination	23/26 (88.5)

* Group 1. Growth of yeast: 1-5 colonies on agar after 2-3 weeks.
Group 2. Moderate growth of yeast: 6-10 colonies on agar after 1-2 weeks.
Group 3. Abundant growth of yeast: More than 10 colonies on agar within 1 week.
Groups 1 and 2 are considered to be non-pathogenic in dermatologic terms.

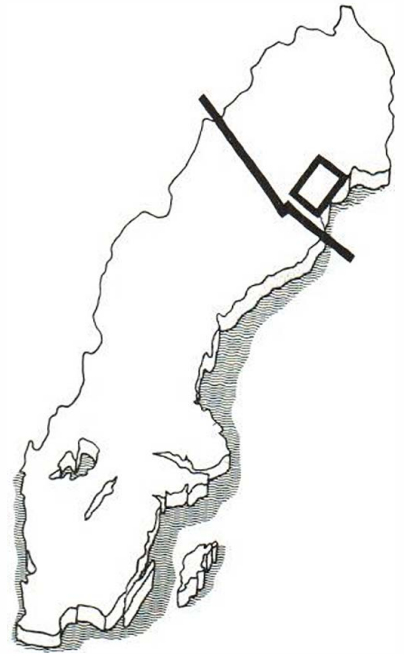


Fig. 1. The 'quadrangle' reproduced on the map of the northernmost county of Sweden (Norrbotten).

was a frequently found additional characteristic, especially in the latter group. All patients complained of the spongy appearance of hands and feet in contact with water, 9 patients of intermittent scaling and 2 of relapsing painful fissures. During childhood and adolescence all but 2 patients had suffered from pronounced hyperhidrosis of hands and feet, which in 14/60 (23.3%) disappeared at an age of about 30 years, leaving a dry hyperkeratosis. Dermatophyte infections in combination with hyperhidrosis of palms and soles were found in 17 cases and with a dry hyperkeratosis in 5 cases. Itching and scaly erythema, which is frequently associated with mycotic infections, was seen in only 3 patients.

The prevalence of dermatophyte infections in hereditary palmo-plantar keratoderma with reference to direct microscopic examination was 41.7% and with reference to the conventional culture method on Sabouraud's glucose agar, 36.7%. The distribution of fungi and the correlation between direct microscopic examination and the conventional culture method are shown in Table I.

DISCUSSION

Of 60 patients, 22 had dermatophyte infections as assessed by conventional culture methods and 25 by direct microscopic examination. Using the culture method as a reference, 4

false-positive microscopic examinations were found. Probably the reverse estimation is equally correct, resulting in 4 false-negative cultures. The correlation between these two methods was 88.5% and does not differ from previously performed investigations (4).

Trichophyton mentagrophytes and *verrucosum* were found in 34.6% as compared with about 17% in other studies (3, 5, 6). *Epidermophyton floccosum* was found in 26.9%, which disagrees with the predominance to a level of 50% of this fungus in a previously performed study on the incidence of dermatophyte infections in hereditary palmo-plantar keratoderma (3). The type of dermatophyte predominating in relatively small materials is probably accidental, so it is not likely that the relatively large number of *Trichophyton mentagrophytes* and *verrucosum* found in this material has any significance.

REFERENCES

1. Acten, G.: The use of detergents for direct mycologic examination. *J Invest Dermatol* 26: 389-397, 1956.
2. Bergström, C.: Keratoderma palmaris et plantaris Unna-Thost. *Nord Med* 78: 1035, 1967.
3. Elmros, T. & Liden, S.: Hereditary palmo-plantar keratoderma: Incidence of dermatophyte infections and the results of topical treatment with retinoic acid. *Acta Dermatovener (Stockholm)* 61: 453-455, 1981.
4. Gamborg Nikelsen, P.: A comparison between direct microscopy and culture in dermatological mycotic material. *Mykosen* 24: 555-560, 1981.
5. Gamborg Nielsen, P. & Karltop, N.: Keratoderma palmaris et plantaris and mycotic infections. *Mykosen* [accepted 1981].
6. Gamborg Nielsen, P.: A simple method to reduce growth of contaminants in routine mycological procedure. *Mykosen* 25: 368-376, 1982.
7. Gamborg Nielsen, P.: Control of growth of saprophytic fungi in routine mycotic cultures. *Mykosen* 26: 46-52, 1983.
8. Schwartz, J. H. & Lampkins, B. E.: A rapid simple stain for fungi in skin, nail scrapings and hairs. *Arch Dermatol* 89: 89-94, 1964.
9. Thost, A.: Über erbliche Ichtyosis palmaris et plantaris cornea. *Med. Diss. Heidelberg* 1880.