

## Sebaceous Glands Changes Following Topical Application of Citral

A. ABRAMOVICI,<sup>1</sup> R. WOLF<sup>2</sup> and M. SANDBANK<sup>2</sup>

<sup>1</sup>*Department of Pathology, Tel-Aviv University Sakler School of Medicine and*

<sup>2</sup>*Department of Dermatology, Beilinson Hospital and the Tel-Aviv University Sakler School of Medicine, Tel-Aviv, Israel*

Abramovici A, Wolf R, Sandbank M. Sebaceous glands changes following topical application of citral. *Acta Derm Venereol (Stockh)* 1982; 63: 428-431.

The long-lasting effect of a flavour cosmetic constituent on male rat skin was studied. Topical daily application of citral (15.4%) solution for 3 months produced an increase in the number of sebaceous gland lobules and hyperplasia of sebaceous cells in each gland. It is suggested that the mechanism of this hyperplasia might be activation of the testosterone 5 $\alpha$ -reductase which induces the formation of dihydrotestosterone, the mediator of sebaceous gland activity. *Key words: Sebaceous glands hyperplasia; Citral.* (Received December 23, 1982.)

A. Abramovici, Department of Pathology, Tel-Aviv University Sakler School of Medicine, Tel-Aviv, Israel.

Citral (3.7 dimethyl 2.6-octadienol) is an important constituent of natural essential oils, extracted from citrus fruits and various flowers. Nowadays it is synthesized on an industrial scale and incorporated as a flavour additive in many cosmetic products (1,2).

The contrast between the continuously increasing and uncontrolled usage of citral as an additive to soaps, detergents deodorant creams, lotions and perfumes, and the paucity of works published about its long-term effects on the skin is striking. The aim of the present work was to investigate the histopathological changes in the rat skin induced by topical application of citral over a long period.

### MATERIAL AND METHODS

Young male and female Wistar rats from Beilinson animal colony ( $\approx$ 150 g body weight) were maintained in a climatized environment with 12-h light/dark cycle. 36 animals (18 males and 18 females) were treated daily for a period of 90 days with a dose of 0.2 cc 15.4% citral (Fluka, Buchs, Switzerland) dissolved in 70% ethanol solution ( $\approx$ 185 mg/kg body weight/day). We were unable to determine the LD<sub>50</sub> for citral administered topically in 70% ethanol solution. However, it can be said that even at much higher doses (460 mg/kg BW), no obvious toxic effects were observed by Toaf et al. (9) other than an increase in their aggressive behaviour. An identical volume of solvent alone was applied on 10 control animals, 5 males and 5 females. Both groups were smeared gently with a glass rod on a preshaved skin area of approximately 4 cm<sup>2</sup> in the dorso-scapular region.

All the animals were fed on standard Purina chow, and water supplied ad libitum. At the end of 3 months the animals were killed by cervical dislocation and pieces of skin (2 $\times$ 0.3 cm) were excised from the smeared region of treated and control rats. The tissue was fixed in a 4% saline formalin buffer phosphate solution (pH 7.2) and routinely embedded in paraffin wax. Histological sections 6  $\mu$ m thick were stained with Mayer's hematoxylin-eosin as well as with the Masson trichrome method for collagen, with Verhof's procedure for elastin fibers, and with Alcian blue at pH 1.0 and 2.5 for sulfated and non-sulfated mucopolysaccharides, respectively (4).

A quantitative study of sebaceous glands in a given area (1 mm) was performed in five different sections and the mean score of sebaceous cells for each sebaceous gland lobule was counted and statistically analysed.

### RESULTS

*Macroscopic examination.* The hair growth rate seems to be delayed in the treated male animals, as reflected by the less frequent need for shaving, than in the controls and treated




Fig. 1. Control animal. Epidermis shows thick keratin layer. 5 sebaceous glands are seen in the section. Hematoxylin eosin  $\times 35$ .

female rats. The citral-smear area also showed a brown-yellow pigmentation which contrasted with the white fur of control rats.

*Microscopic examination.* The epidermis in the control animals was the same as in the citral-treated animals. The control animals, however, showed a thicker keratin layer. The number of hair follicles was the same in both groups. A striking change was seen in the number and volume of sebaceous glands in the male rats (Table I). In the citral-treated male animals their number was doubled (Figs. 1, 2). The glands were so enlarged that they formed an almost continuous mass from follicle to follicle (Figs. 3, 4). The sebaceous cells had a normal foamy cytoplasm and their diameter was identical in both control and treated animals. The average number of sebaceous cells in a cross-sectioned lobule was about 11 in normal glands, whereas in the citral-treated rats their number increased to 18–20 cells per lobule. The basal layer cells were alike in both groups. Whereas no mitotic figures were seen in the basal layer of the glands in the control animals, a few mitotic figures were observed in the citral-treated animals.

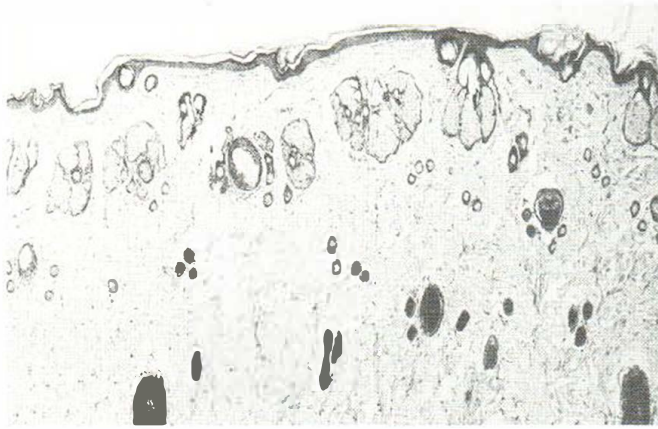
## DISCUSSION

The present study shows that citral at a dose of 185 mg/kg B. W. applied over a period of 90 days does not cause any peculiar irritation or sensitization of the rat skin.

Previous studies on the irritative effect of citral on the skin, at various concentrations from 1 to 8%, showed that the 8% concentration was marginally irritative when applied over a period of 21 days. Lower concentrations did not provoke any irritation (5). On the other hand, citral proved to be a potent primary irritant of skin at higher temperatures in man (6). Although the amount of citral utilized in this study was quite large, compared with the cosmetic usage, the question raises regarding their possible noxious effects during

Table I. Effect of citral on sebaceous gland of rat skin

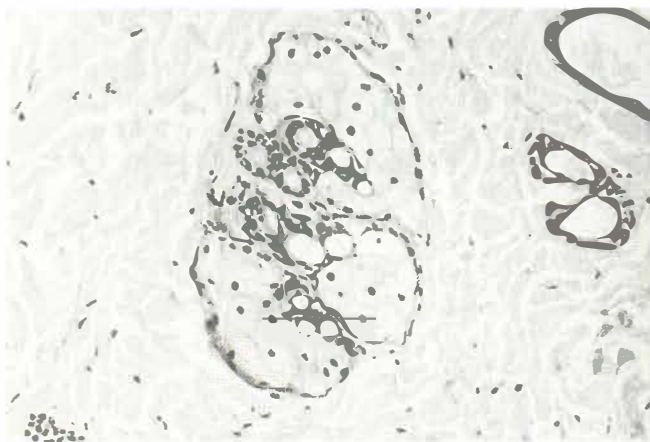
	Citral males	Ethanol + citral females
Glands/mm	$7.5 \pm 0.6$	$3.9 \pm 0.4$
Cells/lobule	$19 \pm 1$	$11 \pm 1$
Mitoses	3–4	0



*Fig. 2.* Citral-treated animal. 8 sebaceous glands, each with 3-4 lobules are seen in the section. Hematoxylin eosin,  $\times 35$ .

prolonged and uncontrolled exposure in man. Many reports have attributed to citral deleterious effects on various biological systems, both *in vitro* (7, 8, 9) and *in vivo* (3, 10). Citral displayed a marked cytotoxicity on HeLa cells (7) and inhibited cell growth of neoplastic mast cells (8) as well as hemolysis of rat erythrocytes (9). A selective oocyte degeneration accompanied by a reproductive failure was noted in female rats after long-term treatment (3). Citral also had a teratogenic effect on chick embryos, affecting mainly the limbs and eyes. The limb bud epidermis is very sensitive to citral, undergoing lysis and ulceration during the first 2 hours post treatment (11). In the present study we could not find any indication of cytotoxic effect on the rat epidermis or of inhibition of cell proliferation and/or differentiation. However, the most significant histopathological changes in the skin were hyperplasia of sebaceous glands and pigmentation in male rats. Identical lesions were observed by Hsia & Voigt (6) in hamster skin after a 3-week topical application of testosterone. This androgen hormone stimulates the sebum production and also increase the mitotic rate of the sebaceous gland in rats (Ebling 74).

The evidence to date strongly supports the concept that sebaceous gland activity is mediated by hormones, as both castrated and hypophysectomized rats show a decrease in sebum secretion, whereas estrogen and cyprosterone inhibit this process (Ebling 74; Shuser & Thodi 74). Thus the difference between males and females can be explained.



*Fig. 3.* Control animal. Sebaceous gland lobule containing 10-12 sebaceous cells. Hematoxylin eosin,  $\times 200$ .

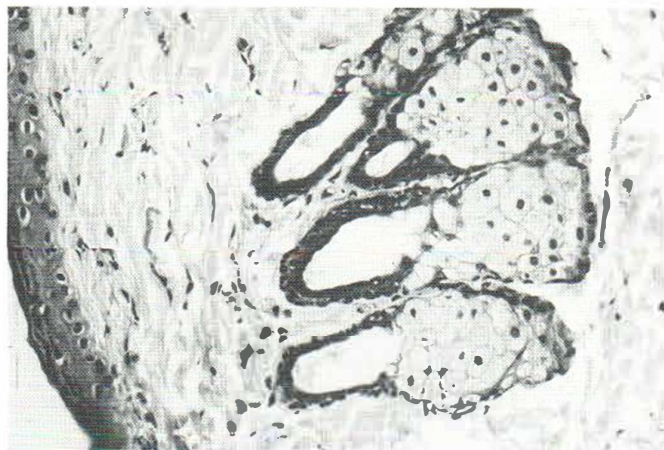


Fig. 4. Citral-treated animal. Sebaceous gland composed of 3–4 lobules each containing 15–20 cells. Hematoxylin eosin,  $\times 200$ .

The stimulatory effect of androgen on the sebaceous gland seems to be mediated via the dehydrotestosterone (DHT), the main active metabolite of testosterone, resulting from  $\alpha 5$ -reductase activity in skin. Citral is known to be an inducer for several hepatic drug-metabolizing enzymes (12), although it may be deactivated by a reductase system from rat liver homogenates.

All things considered, we can speculate on a hypothesis in which citral might stimulate the enzyme activity and subsequently lead to an increased production of DHT, the main factor responsible for sebaceous gland hyperplasia.

It is impossible for us to ascertain whether citral really does act on  $\alpha 5$ -reductase, but if this should be so, one might expect an increase of this enzyme in other target organs such as the ventral prostate in rats (8) and in consequence a prostate hyperplasia ought to arise. Further studies concerning this aspect are now in progress in our laboratory.

## REFERENCES

1. Opdyke D L J. Citral. *Food Cosmet Toxicol* 1979; 17: 259–266.
2. Maibach H I. Reports to RIFM. 7 July–September. 1971.
3. Rothenborg H W, Menné T, Sjölin K E. Temperature dependent primary irritant dermatitis from lemon perfume. *Contact Dermatitis* 1977; 3: 37–48.
4. Zolotovitch G, Nachev Ch, Siljanovska K Stojcevs. Untersuchungen der zytotoxischen Wirkung von aus ätherischen Ölen isolierten Karbonylverbindungen. *C R Acad Bulg Sci* 1967; 20: 1213–1216.
5. Thomas D B, Pasternak C A. Vit A and the biosynthesis of sulphated mucopolysaccharides. Experiments with rats and cultured neoplastic mast cells. *Biochem J* 1969; 111: 407–412.
6. Hsia S L, Voig W. Inhibition of dihydrotestosterone formation: An effective means of blocking androgen action in hamster sebaceous gland. *J Invest Dermatol* 1974; 62: 224–227.
7. Parke D V, Rachman H. The effects of some terpenoids and other dietary nutrients on hepatic drug metabolizing enzymes. *Biochem J* 1969; 113: 12P.
8. Isaacs J T, Coffey D S. Changes in dihydrotestosterone metabolism associated with the development of canine benign prostatic hyperplasia. *Endocrinology* 1981; 108: 445–453.
9. Toaf M E, Abramovici A, Sporn J, Liban E. Selective oocyte degeneration and impaired fertility in rats treated with aliphatic monoterpene, citral. *J Reprod Fert* 1979; 55: 347–352.
10. Pearse A G. *Histochemistry, Theoretical and Applied*. Churchill Livingstone Ltd., Vol. 1. London, 1968.
11. Sporn J, Abramovici A. Monoterpene biodegradation by an aldehyde reductase system in rat liver homogenates. *Isr J Med Sci* 1976; 12: 1351.
12. Abramovici A, Rachmuth-Forschmidt P, Liban E, Sandbank M. Experimental limb dysmorphogenesis as a model of chemical injury response in undifferentiated embryonic tissues: A light and electron microscopical study. *J Pathol* 1980; 131: 289–308.