

SHORT REPORTS

Formaldehyde-induced Fluorescence Method for Touch Preparations from Amelanotic Melanoma Tissues: A Simple and Rapid Method for the Demonstration of Melanogenic Activities of Amelanotic Melanoma Cells

TAKAFUMI MORISHIMA and NORIYASU NAGASHIMA

Department of Dermatology, Nihon University School of Medicine, Tokyo, Japan

Morishima T, Nagashima N. Formaldehyde-induced fluorescence method for touch preparations from amelanotic melanoma tissues: A simple and rapid method for the demonstration of melanogenic activities of amelanotic melanoma cells. *Acta Derm Venereol (Stockh)* 1983; 63: 418-421.

Touch preparations from four amelanotic melanoma tissue samples were studied with the formaldehyde-induced fluorescence method. Fluorescent amelanotic melanoma cells could easily be detected under a fluorescence microscope. The fluorescence microscopic pictures obtained by the touch-fluorescence method were equally evaluated with those obtained by the classical fluorescence method. The method made it possible to demonstrate the melanogenic activity of amelanotic melanoma cells within 30 min. The routine application of this method to the diagnosis of amelanotic melanoma is suggested. *Key words: Touch-fluorescence method; Amelanotic melanoma; 5-S-cysteinyldopa; Fluorescence method of Falck & Hillarp.* (Received March 15, 1983.)

T. Morishima, Department of Dermatology, Surugadai Nihon University Hospital, 1-8-13, Kandasurugadai, Chiyoda-ku, Tokyo, Japan.

As a sensitive tool for the demonstration of cysteinyldopas or DOPA, the formaldehyde-induced fluorescence method of Falck & Hillarp is useful for examining the morphology and localization of melanocytes, nevus cells and melanoma cells (7-11, 13, 14). We have recently reported that this method is useful for demonstration of melanogenic activities not only of melanotic melanoma but also of amelanotic melanoma (12). The successful application of this method depends on immobilization of the catechol amino acids in lesions by freeze-drying and subsequent condensation of the catechol amino acids with gaseous formaldehyde (3, 6).

As we have freeze-dried the lesions for 7 days, this method is not useful for the quick diagnosis of malignant melanoma. On one occasion, the touch preparations from melanotic melanoma were exposed to gaseous formaldehyde, and soon afterwards the slides were examined with fluorescence microscopy. The melanoma cells emitted specific fluorescence beyond our expectations.

According to the literature, Ehinger et al. examined imprints of cutaneous metastatic melanoma with the fluorescence method and reported that melanoma cells emitted a granular yellowish fluorescence and contained fluorescent intranuclear bodies (4). De Lellis applied the fluorescence method to study touch preparations from a biogenic amine-producing tumor containing metastatic melanotic melanoma and reported that melanoma cells emitted green specific fluorescence (5). The aim of the present study was to show whether or not the application of the fluorescence method to touch preparations (tentatively called the touch-fluorescence method) would be useful for the quick diagnosis of amelanotic malignant melanoma, which is one of the most difficult diseases to diagnose.

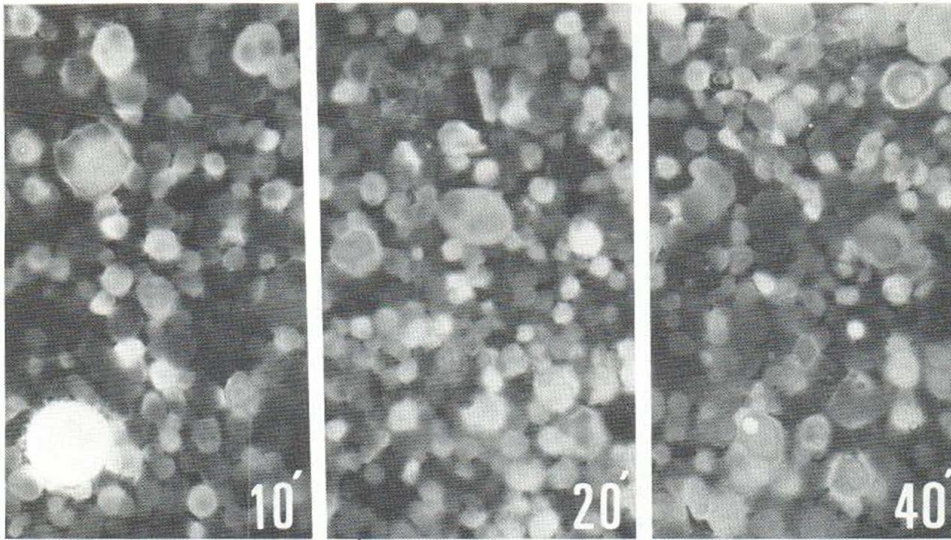


Fig. 1. Intensity of specific fluorescence and exposure time to gaseous formaldehyde. It is shown that an adequate exposure time is 10 to 20 min.

MATERIALS AND METHODS

Several touch preparations were obtained from melanotic melanoma tissues immediately after excision of the melanoma, in order to define the conditions for the formaldehyde vapor reaction. These slides were exposed to gaseous formaldehyde at $+80^{\circ}\text{C}$ for 10 to 60 min. Control slides were heated without paraformaldehyde at $+80^{\circ}\text{C}$ for 10 to 60 min. As shown in Fig. 1, specific fluorescence was localized in the perikaryon of the melanotic melanoma cells, indicating that a suitable exposure time to gaseous formaldehyde is 10 to 20 min.

Two samples from cutaneous metastatic amelanotic melanoma and two samples from metastatic amelanotic melanoma of a lymph node were studied with the touch-fluorescence method described below. At the same time, these tissue samples were examined by the classical fluorescence method of Falck & Hillarp, and 5-S-cysteinyl-dopa (5-S-CD) and DOPA in the lesions were analysed biochemically. The data obtained by these methods have already been reported (12). Control touch preparations were obtained from two lesions of reticulum cell sarcoma, and from one lesion of neurofibrosarcoma, which had to be differentiated histopathologically from amelanotic melanoma, and at the same time, those tissue samples were analysed for 5-S-CD and DOPA.

The procedure of our touch-fluorescence method is as follows:

1. Small tissue masses were taken from the unpigmented lesion immediately after excision. The blood and exudate on the masses were removed with dry gauze.
2. Touch preparations from the tissue samples were made on the non-fluorescent glass slides cleaned with alcohol.
3. The slides were air-dried at room temperature.
4. The slides were then transferred to a closed vessel containing about 3 g of paraformaldehyde which had been equilibrated previously to a relative humidity of 60%.
5. The vessel was placed in an oven at 80°C for 20 min.
6. After the exposure to gaseous formaldehyde, the slides were mounted with liquid paraffin and observed with fluorescence microscopy. The Nikon FL-type fluorescence microscope was used, fitted with a Nikon Y-51 filter. The source of the activation lamp was a Toshiba SHL-200 with a Nikon B filter. A dark-field condenser for oil immersion was used for examination and photography.

RESULTS

When the touch preparations from amelanotic melanoma were observed with fluorescence microscopy, fluorescent amelanotic melanoma cells could easily be detected. As shown in

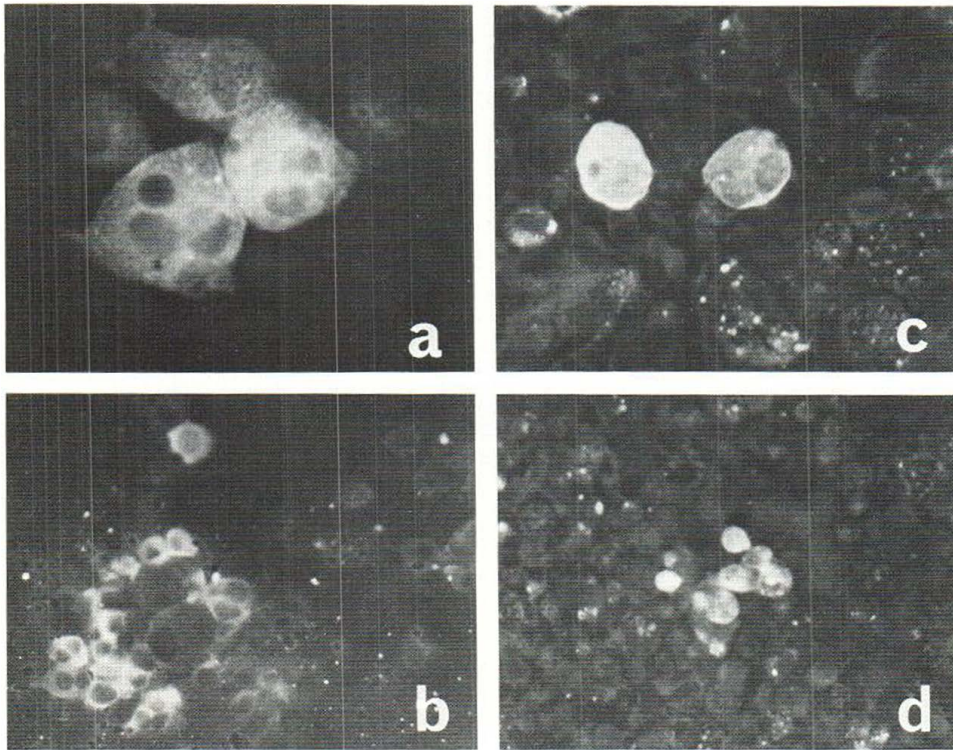


Fig. 2. Findings of four samples of metastatic amelanotic melanoma obtained by the touch-fluorescence method. Amelanotic melanoma cells can easily be detected by fluorescence microscopy. Specific fluorescence emitted from the amelanotic melanoma cells is localized in the perikaryon of these cells. (a) A subcutaneous lesion of a 27-year-old male patient ($\times 400$). (b) A cutaneous lesion of a 65-year-old female patient ($\times 200$). (c) A lesion in the inguinal lymph node of a 39-year-old male patient ($\times 400$). (d) A lesion in the inguinal lymph node of a 57-year-old male patient ($\times 200$).

Fig. 2. specific fluorescence was definitely localized in the perikaryon of these cells. The numbers of fluorescent cells varied with the site of observation and with the tissue samples taken. DOPA was not detected in these amelanotic melanoma tissues, and 5-S-CD values were within the range 7.4-17.4 $\mu\text{g/g}$ (12). On the basis of these results, it was considered that the specific fluorescence was emitted by the amelanotic melanoma cells owing to the presence of 5-S-CD. Fluorescent cells could not be demonstrated in the touch preparations taken from the above-mentioned malignant mesenchymal tumors and no 5-S-CD nor DOPA could be detected in these tumors.

DISCUSSION

Malignant melanoma characterized with little or no formation of melanin is called amelanotic melanoma. Therefore, it is important for the definite diagnosis of amelanotic melanoma to show evidence of melanogenesis. The melanogenic activity of these cells is usually demonstrated by histochemical methods such as DOPA and tyrosine reactions, or by ultrastructural observations. It has also been demonstrated by organ culture (2) and determination of DOPA oxidase (1).

We have recently reported that the classical fluorescence method of Falck & Hillarp and

biochemical determination of 5-S-CD in the lesion are useful for the definite diagnosis of amelanotic melanoma (12). 5-S-cysteinyldopa, which constitutes the buildingblock of melanin formation, was identified as a fluorogenic catechol amino acid. As shown in Fig. 2, the fluorescence microscopic pictures obtained by the touch fluorescence method were equally evaluated with those obtained by the classical fluorescence method of Falck & Hillarp (12). In addition, this method made it possible to demonstrate the melanogenic activity of amelanotic melanoma cells within 30 min. When quick-frozen sections of unpigmented tumors taken at operation are suspected of being malignant and the presence of fluorescent cells is demonstrated by this method, the unpigmented tumor can be diagnosed definitely as amelanotic melanoma. This method also makes it possible to demonstrate rapidly and simply the melanogenic activity of amelanotic melanoma, which is otherwise difficult to diagnose.

REFERENCES

1. Comstock EG, Wynne ES, Russel WO. Dopa oxidase activity in differential diagnosis of amelanotic melanoma tissue. *Cancer Res* 1959; 19: 880.
2. Costa J, Rosai J, Gordon W, Philpott GW. Pigmentation of amelanotic melanoma in culture. *Arch Pathol* 1973; 95: 371.
3. Corrodi H, Jonsson G. Fluorescence method for the histochemical demonstration of biogenic monoamines. *J Histochem Cytochem* 1967; 15: 65.
4. Ehinger B, Falck B, Jacobsson S, Rorsman H. Formaldehyde-induced fluorescence of intranuclear bodies in melanoma cells. *Br J Dermatol* 1969; 81: 115.
5. De Lellis R. Formaldehyde-induced fluorescence technique for the demonstration of biogenic amines in diagnostic histopathology. *Cancer* 1971; 28: 1704.
6. Falck B, Hillarp N-Å, Thieme G, Torp A. Fluorescence of catecholamines and related compounds condensed with formaldehyde. *J Histochem Cytochem* 1962; 10: 348.
7. Falck B, Jacobsson S, Olivecrona H, Olsen G, Rorsman H, Rosengren E. Determination of catecholamines, 5-hydroxytryptamine and 3,4-dihydroxyphenylalanine (dopa) in human malignant melanomas. *Acta Derm Venereol (Stockh)* 1966; 46: 65.
8. Falck B, Jacobsson S, Olivecrona H, Rorsman H. Fluorescent dopa reaction of nevi and melanoma. *Arch Dermatol* 1966; 94: 363.
9. Falck B, Jacobsson S, Lindvall O, Nietsche U-B. On the occurrence of cysteinyldopa and dopa in melanocytes and benign nevi cells. *Scand J Plast Surg* 1976; 10: 185.
10. Morishima T, Ishikawa T, Endo M, Tsujiguchi Y. Pagetoid malignant melanoma and lentigo malignant melanoma of toe. A study with the fluorescence method (Falck and Hillarp). *Arch Dermatol Res* 1978; 262: 275.
11. Morishima T, Endo M. Pigmented nevus between recipient and donor sites by intermediate skin grafting procedure. A study with fluorescence method (Falck & Hillarp). *Acta Derm Venereol (Stockh)* 1978; 58: 231.
12. Morishima T, Tatsumi F, Fukada E, Watanabe M, Nagashima N, Hanawa S. Studies on amelanotic melanoma with the fluorescence method (Falck and Hillarp) and biochemical analysis of 5-S-cysteinyldopa in the tissues. *Arch Dermatol Res* (in press).
13. Paul E., Hartwig H-G, Möller W, Illig L. Fluorescenz-histochemische Untersuchung und mikrofluorometrische Analysen an pigmentbildenden Tumoren der Haut. *Arch Dermatol Forsch* 1975; 253: 125.
14. Paul E, Illig L. Melanin-producing dendritic cells and histogenesis of malignant melanoma. *Arch Dermatol Res* 1976; 257: 163.