

## Mutilating Palmo-Plantar Keratoderma

P. GAMBORG NIELSEN

*Department of Dermatology, Central Hospital, Boden, Sweden*

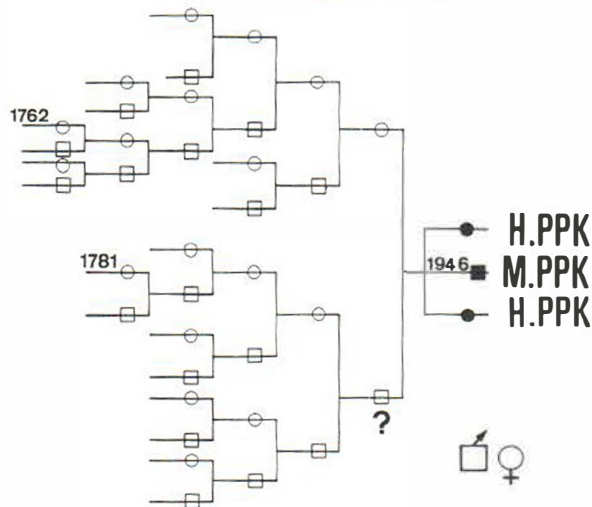
Gamborg Nielsen P. Mutilating palmo-plantar keratoderma. *Acta Derm Venereol* (Stockh) 1983; 63: 365-367.

A 36-year-old male, with no history of hereditary palmo-plantar keratoderma, showed at the age of 2-3 years a typical keratoderma of the Unna Thost variety on palms and soles. At the age of 16 years he developed mutilating symptoms localized to the fingers. Radiologic examination showed abnormally pointed end phalanges. (Received December 21, 1982.)

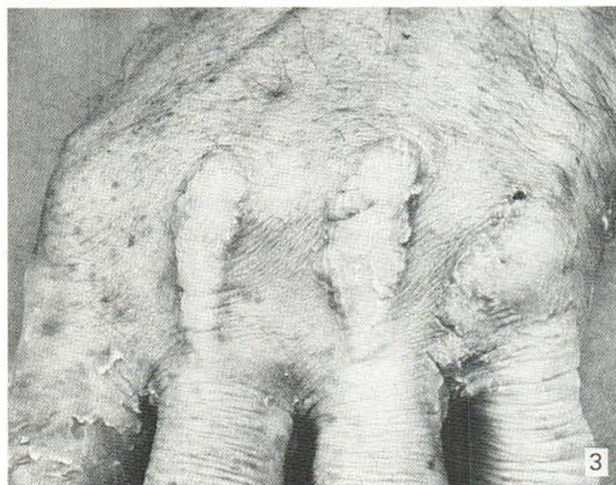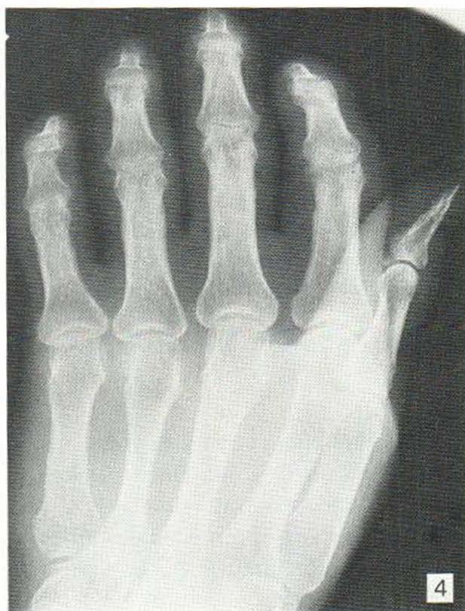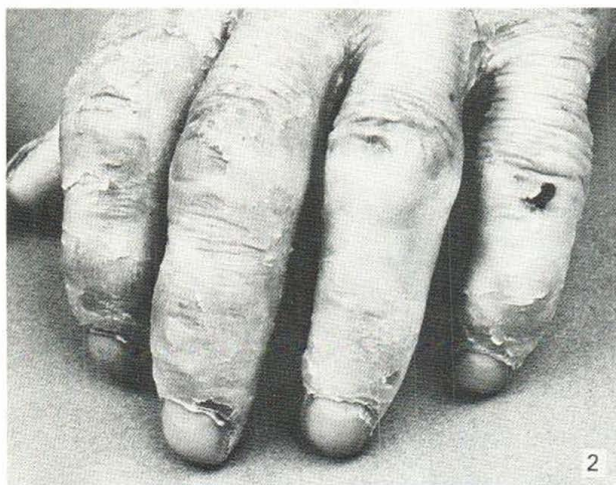
P. Gamborg Nielsen, Department of Dermatology, Central Hospital, S-961 85 Boden, Sweden.

In the northernmost county of Sweden (Norrbotten) the incidence of hereditary palmo-plantar keratoderma Unna Thost was found to be 0.55% (1); one case of mutilating palmo-plantar keratoderma was found in this material (5, 2). Two types of mutilating palmo-plantar keratoderma have been described, the first a syndrome associated with the name of Vohwinkel, determined by an autosomal dominant gene with or without associated anomalies; the second an autosomal recessive type connected with ectodermal dysplasias (3, 6).

Palmo-plantar keratoderma is present from infancy and, though diffuse, is honey-combed by small depressions. The hyperkeratotic areas are generally surrounded by an intensive erythroderma on both hands and feet. Constricting hyperkeratotic bands lead to progressive strangulation of the digits from the age of 4 or 5 years, though this development can be delayed for 25-30 years. Hyperhidrosis is invariably present, and warty papules on the backs of hands and feet are usually to be found. In the autosomal dominant type of mutilating keratoderma the following associated symptoms have been described: linear keratotic lesions on elbows and knees, reticular skin pigmentation, dystrophia of the cornea, lipomatosis and osteopetrosis (Albers-Schönberg disease). The autosomal recessive type is connected with loss of hearing, patchy cicatricial alopecia and keratosis of the groins and perianal skin.



*Fig. 1.* The genealogy of the family in which the mutilating palmoplantar keratoderma was found.



*Fig. 2.* Constricting bands encircling the fingers are demonstrated after the hands had been kept in water for 15 minutes.

*Fig. 3.* Elongated hyperkeratotic papules localized to the dorsum of the right hand.

*Fig. 4.* The extremely pointed end-phalanx of the first finger of the left hand, demonstrated by radiologic examination.

## CASE REPORT

A 36-year-old male, the second of three children, in a family with no history of hereditary palmo-plantar keratoderma, participated in an investigation on the prevalence of fungus infections in this inherited disorder.

At the age of 2 or 3 years the patient and his two sisters showed a typical keratoderma on both hands and feet. In 1959 all three participated in a genetic investigation on the inheritance of palmo-plantar keratoderma in the northernmost county of Sweden (Norrbotten).

At this examination it was established that they suffered from a typical hereditary palmo-plantar keratoderma of the Unna Thost variety. Large keratotic papules were seen on the backs of hands and a diffuse hyperkeratosis was confined to the first and second phalanx of all fingers. The father of these 3 people was said to have had a palmar and plantar hyperkeratosis, which disappeared at the age of 18 years. At the investigation in 1959 he showed no signs of keratoderma. The genealogical table of the family is shown in Fig. 1.

The second examination of these 3 patients was performed in November of 1982 at the Department of Dermatology, Central Hospital, Boden. The 2 sisters had an unchanged typical hereditary palmo-plantar keratoderma Unna Thost, whilst the brother demonstrated mutilating signs from the fingers, the onset of which took place at the age of 16 years.

The examination showed an enormously thick, diffuse hyperkeratosis surrounded by an intensely red area on both hands and feet. Bands of constricting hyperkeratosis localized to the joints, broader than those described in the literature, encircled the 4th and 5th fingers in particular. Deficiency of extension capacity of the metacarpophalangeal and interphalangeal joints, in particular in the 3rd, 4th and 5th fingers of the left hand, was found (figs. 2 and 3). The finger and toe nails were normal and no other ectodermal dysplasias were seen.

Radiological examination showed that the end phalanges were abnormally pointed, the greatest abnormality being found in the index fingers of both hands (Fig. 4) (4).

## DISCUSSION

The syndrome, mutilating palmo-plantar keratoderma, is extremely rare and has been described in only a few case reports. This case differs from the original descriptions in that the constricting bands were broader and no other keratotic lesions were found, and it cannot be excluded that the variety described here is a special type of Unna Thost keratoderma. This problem cannot be discussed satisfactorily until more cases are discovered.

The genetic pattern gives no guidelines for inheritance, and it is not impossible that the patient's sisters might develop the mutilating form later on. So far the question is open as to whether or not this mutilating keratoderma is an autosomal dominant or autosomal recessive disease.

## REFERENCES

1. Bergström, C.: Keratoderma palmaris et plantaris Unna Thost. *Nord Med* 78: 1035, 1967.
2. Franceschetti, Von A. & Schnyder, U. W.: Versuch einer klinisch genetischen Klassifikation der hereditären Palmoplantarkeratosen unter Berücksichtigung assoziierter Symptome. *Dermatologica* 120: 154-178, 1960.
3. Gibbs, R. C. & Frank, S. B.: Keratoma Hereditaria Mutilans (Vohwinkel). *Arch Dermatol* 94: 619-625, 1966.
4. Presley, N. L. & Bonte, F. J.: The Roentgen appearance of mutilating palmo-plantar keratosis. *Am Reontgenol* 86: 944, 949, 1961.
5. Rook, A. Wilkinson, D. S. & Ebling, F. J. G.: *Textbook of Dermatology*, 3rd edn, pp. 1300-1307. Blackwell Scientific Publications, Oxford, 1979.
6. Wigley, J. E. M.: A case of hyperkeratosis palmaris et plantaris associated with ainhum-like constriction of the fingers. *Br J Dermatol* 41: 188-191, 1929.