

Elephantiasis of External Ears: A Rare Manifestation of Pediculosis capitis

S. MAHZOON and B. AZADEH

Department of Dermatology and Pathology, Shiraz University Medical School, Shiraz, Iran

Mahzoon S, Azadeh B. Elephantiasis of external ears: A rare manifestation of pediculosis capitis. *Acta Derm Venereol (Stockh)* 1983; 63: 363-365.

A case of elephantiasis of the external ears associated with pediculus capitis is reported. Hypersensitivity to the louse bite and Melkersson-Rosenthal syndrome are discussed. (Received September 8, 1982.)

B. Azadeh, Department of Pathology. Shiraz Medical School, Shiraz, Iran.

Elephantiasis and elephantiasiform enlargement of the ears have rarely been described, following eczema, frostbite, erysipelas and piercing of the ears (3). Elephantiasis of the ears associated with pediculosis does not previously appear to have been reported.

CASE REPORT

A 33-year-old woman with enlarged and mildly pruritic ears of 3 years' duration had been heavily infested with pediculus capitis for several years. Both ears were erythematous and markedly swollen: the right one (Fig. 1) was more severely affected. A few post-auricular subcutaneous nodules (5-10 mm) were present bilaterally. The skin over the nape of the neck and upper back was indurated and hyperpigmented. Right cervical lymph nodes were enlarged. She had a persistent right peripheral facial palsy, thought to be Bell's palsy. The white cell count ranged $8.2-11.3 \times 10^9/l$, with 8-11% eosinophils. The erythrocyte sedimentation rate was 45 mm/hour (normal 20 mm/hour).

Other tests including serum protein electrophoresis, liver function tests and antinuclear antibodies were normal. Scrapings of ear lobes and nasal mucosa showed no acid-fast bacilli. Chest X-ray, and bone survey were normal. Patch tests with the whole battery of European standard allergens proved negative. Cervical lymph node biopsy showed non-specific reactive changes. Skin biopsies of the right ear (Fig. 2) showed hyperkeratosis, follicular plugging, focal spongiosis, elongated rete ridges and numerous branching hair follicles. The dermis was infiltrated by chronic inflammatory cells composed predominantly of lymphocytes together with eosinophils, plasma cells and a few melanin-laden macrophages. The cellular infiltrate formed aggregates with no germinal centres around dilated capillary branches. Numerous dilated and conspicuous lymphatic spaces were present, especially in the superficial and mid-dermis. Mast cells were apparently increased in number. No acid-fast bacilli, epithelioid or foreign-body type granuloma were seen. There was no iron pigment or amyloid deposition. Biopsies of post-auricular nodules and the skin of the back showed similar changes. However, the lymphatics were not dilated or conspicuous in the biopsies of the back lesions.

Her pediculosis was treated with DDT. Intralesional injections of 10 mg/ml triamcinolone acetonide (kenalog) resulted in a decrease in the size and induration of the ears, with almost complete resolution of subcutaneous nodules.

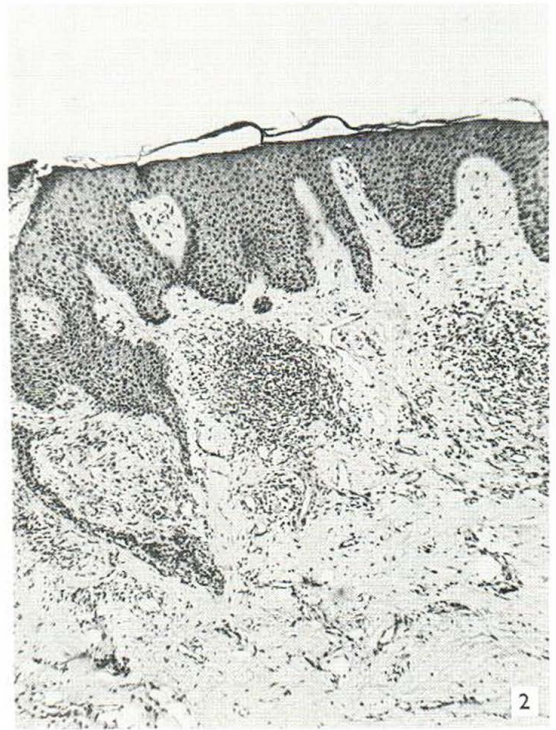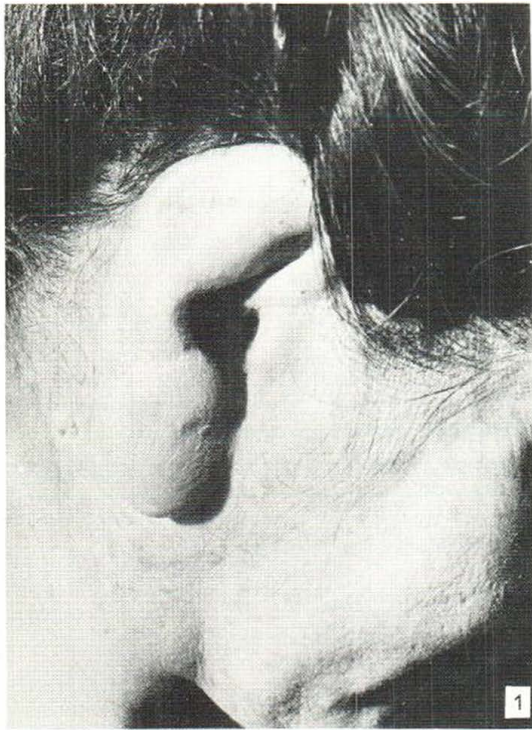


Fig. 1. The patient's swollen right ear. Note the nits on her hair.

Fig. 2. External ear biopsy showing inflammatory cellular aggregates and dilated lymphatics. HE. $\times 60$.

COMMENT

Repeated exposures to the body louse will result in a hypersensitivity reaction in most individuals (7). Experimentally sensitized humans to sandflies (9) and to mosquito bites (6) and guinea pigs to flea bites (1), regardless of species of arthropod, manifest a definite sequency of types of reactivity.

Histological studies on human skin (2) and on guinea pigs (4) in different stages of reactivity to arthropod bite suggest that histological changes conform with those of immediate and delayed hypersensitivity reactions. Cutaneous manifestations in this patient appear to be the result of long-standing exposure to the louse bite in a sensitized individual. Elephantiasis of the ears may be due to a continued hypersensitivity reaction in this particular anatomical location. Obstruction of lymphatic vessels by granulomas has been proposed as a factor in cheilitis granulomatosa (8). In the absence of typical clinical features and absence of epithelioid granulomata, cheilitis granulomatosa appears unlikely in our case. Chronic hypertrophic vulvulitis with similarities to cheilitis granulomatosa have, however, been described (5).

REFERENCES

1. Benjamini, E., Feingold, B. F. & Kartman, L.: Skin reactivity in guinea pigs sensitized to flea bites. The sequency of reactions. *Proc Soc Exp Biol Med* 108:700. 1961.
2. Goldman, L., Rockwell, E. & Richfield, D. F.: Histopathological studies on cutaneous reactions to the bites of various arthropods. *Am J Trop Med Hyg* 1:514. 1952.

3. Hörbst, L. & Loos, H. O.: Über Elephantiasis der Ohrmuschel. Arch Dermatol Syphilo 166:342, 1932.
4. Larrivee, D. H., Benjamini, E., Feingold, B. F. & Shimizu, M: Histologic studies of guinea pig skin. Different stages of allergic reactivity to flea bites. Exp Parasitol 15:491, 1964.
5. Larsson, E. & Westermark, P.: Chronic hypertrophic vulvulitis: A condition with similarities to cheilitis granulomatosa (Melkersson-Rosenthal syndrome). Acta Dermatovener (Stockholm) 58:92, 1978.
6. Mellanby, K.: Man's reaction to mosquito bites. Nature 158, 554:751, 1946.
7. Peck, S. M., Wright, W. H. & Gant, J. Q.: Cutaneous reactions due to body louse (Pediculus humanus). J Am Med Ass 123:821, 1943.
8. Pontén, J. & Thyresson, N.: The epitheloid reaction in cheilitis granulomatosa. Proc 18 Meeting Scand Dermatol Ass p. 118. Turku, 1968.
9. Theodor, O.: A study of the reaction to phlebotomus bites with some remarks on "Harara". Trans R Soc Trop Med Hyg 29:273, 1935.