

Cutaneous Sarcoidosis: An Immunofluorescence Study

SUSANNE ULLMAN,¹ POUL HALBERG,² DORRIT STAHL³ and NIELS K. VEIEN³

¹Department of Dermatology, Rigshospital, ²Department of Medicine, Division of Rheumatology, Hvidovre Hospital, and ³Department of Dermatology, Finsen Institute, University of Copenhagen, Copenhagen, Denmark

Ullman S, Halberg P, Stahl D, Veien NK. Cutaneous sarcoidosis: An immunofluorescence study. *Acta Derm Venereol* (Stockh) 1983; 63: 343-346.

Biopsy specimens from granulomatous skin lesions of 14 patients with active sarcoidosis were examined by immunofluorescence microscopy. In seven lesions, deposits of IgM, IgA or complement C3 were demonstrated in the dermal vessel walls and/or at the dermal-epidermal junction. Similar deposits were found in three of twelve biopsy specimens from clinically normal skin from a buttock of the same patients. The results support the hypothesis that deposition of circulating immune complexes in the vessel walls may be of importance for the development of granulomatous lesions in sarcoidosis. *Key words:* Sarcoidosis; Immunofluorescence; Vessel walls. (Received December 7, 1982.)

S. Ullman, Department of Dermatology Rigshospital, Blegdamsvej 9, DK-2100 Copenhagen Ø, Denmark

In 1972 Salo & Hannuksela demonstrated, by means of immunofluorescence microscopy, deposits of IgM and complement C3 in vessel walls in Kveim reactions of 20 patients with sarcoidosis (1). Skin lesions from 5 of the patients were also examined and in 2 of them granular deposits were found at the dermal-epidermal junction (DEJ). These results were confirmed by Quismorio et al. who demonstrated deposits of IgM in the vessel walls in the

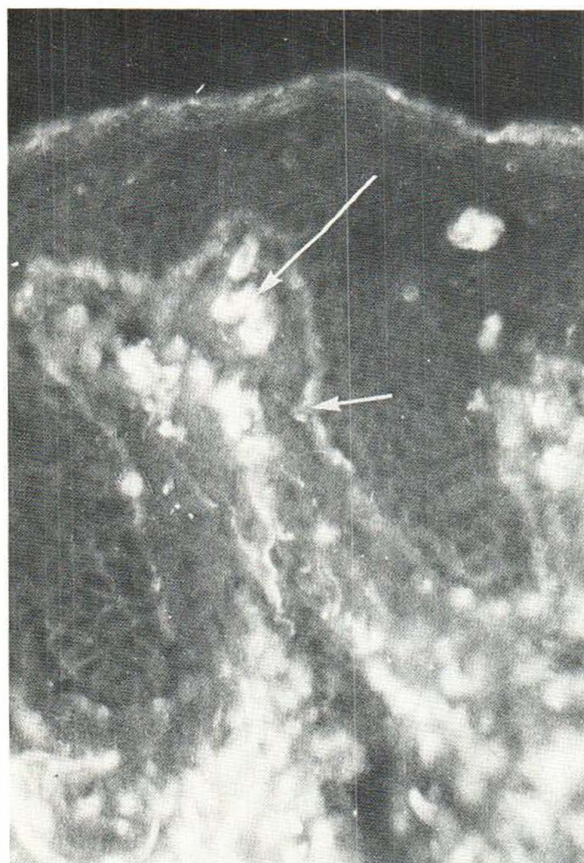


Fig. 1. Deposits of IgM in the dermal vessel walls (*long arrow*) and at the DEJ (*short arrow*) in granulomatous skin lesion from a patient with sarcoidosis.

skin lesions of 5 of 8 patients with sarcoidosis as well as deposits at the DEJ in 2 patients (2). However, the immunofluorescence study by Kataria et al. was negative except for a characteristic deposition of fibrinogen in a diffuse pattern in the granulomas, which was also reported in the other studies (1-3).

In this study biopsies of granulomatous skin lesions from 14 patients with active sarcoidosis were examined by immunofluorescence microscopy.

Table I. Findings in skin lesions from 7 patients with sarcoidosis

Patient	Skin lesions		Uninvolved skin	
	DEJ	Vessel walls	DEJ	Vessel walls
L. V. C.	IgM, IgA, C3	IgM, C3	IgM	-
S. I.	-	C3	-	-
R. J.	-	C3	-	-
A. M.	IgM	-	-	-
J. E. R.	IgM, C3	IgM		Not tested
E. P.	-	C3	C3	-
B. L.	-	IgA, C3	-	C3

MATERIAL AND METHODS

Fourteen patients (10 women, 4 men) with active sarcoidosis were included in the study. Active sarcoidosis was defined as suggested at the Seventh International Conference on sarcoidosis and other granulomatous disorders, New York, 1975. All patients had granulomatous skin lesions. At the time of biopsy, one patient (A. M.) received methotrexate, 10 mg per week, while the other 13 patients did not receive any systemic treatment.

Biopsy specimens were obtained from the skin lesions of all the patients. Twelve patients had biopsies taken also from clinically uninvolved skin of a buttock. The biopsy specimens were examined for deposits of IgG, IgM, IgA and complement C3 by a direct immunofluorescence technique (4). Nine of the biopsies from skin lesions were also examined for deposits of fibrinogen.

Sections of the biopsy specimens were also stained with hematoxylin-eosin for routine histopathological examination.

RESULTS

In the hematoxylin-eosin stained sections of granulomatous skin lesions, non-caseous granulomas were found.

By immunofluorescence microscopy, deposits in the dermal vessel walls and/or at the DEJ were demonstrated in biopsies from 7 of the 14 patients with granulomatous skin lesions (Table I, Fig. 1). The deposits consisted of IgM, IgA and/or C3, but IgG was never found. Granular deposits were found at the DEJ and in the vessel walls in two and one biopsy, respectively, from clinically normal skin. The patient who received methotrexate (A. M.) had deposits of IgM at the DEJ of the involved skin.

The characteristic diffuse pattern of fibrinogen deposition in the granulomas was seen in all of the nine biopsy specimens from skin lesions which were stained with antifibrinogen.

COMMENT

Our results confirmed previous studies in which deposits of immunoglobulins and complement were found in the vessel walls and at the DEJ of some (but not all) granulomatous skin lesions. Previously described diffuse depositions of fibrinogen in the granulomas were also found (1-3).

In patients with active sarcoidosis, increased B-cell activity with increased levels of serum immunoglobulins, immune complexes and antibodies to infectious agents, rheumatoid factors and antinuclear antibodies have been demonstrated (5-7). The present and previous findings suggest that the deposition of immune complexes may be of importance for the pathogenesis of sarcoid lesions.

ACKNOWLEDGEMENTS

We wish to thank Mariann Andersen for skilful technical assistance.

This study was supported by a grant (no. 512-8196) from the Danish Medical Research Council.

REFERENCES

1. Salo, O. P. & Hannuksela, M.: Immunohistology of the Kveim reaction. *Ann Clin Res* 4: 169, 1972.
2. Quismorio, F. P., Sharma, O. P. & Chandor, S.: Immunopathological studies on the cutaneous lesions in sarcoidosis. *Br J Dermatol* 97: 635, 1977.
3. Kataria, U. P., Zafranias, A. & Sharma, H. M.: Immunohistochemistry of human cutaneous sarcoidosis: A study of nine cases. *Hum Pathol* 9: 517, 1978.
4. Ullman, S. & Dahl, M. V.: Necrobiosis lipoidica. An immunofluorescence study. *Arch Dermatol* 113: 1671, 1977.

5. Daniele, R. P., Dauber, J. H. & Rossman, M. D.: Immunologic abnormalities in sarcoidosis. *Ann Intern Med* 92: 406, 1980.
6. Daniele, R. P., McMillan, L. J., Dauber, J. H. & Rossman, M. D.: Immune complexes in sarcoidosis. A correlation with activity and duration of disease. *Chest* 74: 261, 1978.
7. Johnson, N. M., McNicol, M. W., Burton-Kee, J. E. & Mowbray, J. F.: Circulating immune complexes in sarcoidosis. *Thorax* 35: 286, 1980.