

The Immediate Action of Long-wave Ultraviolet Radiation (UVA) on Suprabasal Melanocytes in Human Skin: A Transmission Electron Microscopical Study

HARRY BEITNER and GÖRAN WENNERSTEN

Department of Dermatology, Karolinska Sjukhuset, Stockholm, Sweden

Beitner H, Wennersten G. The immediate action of long-wave ultraviolet radiation (UVA) on suprabasal melanocytes in human skin: A transmission electron microscopical study. *Acta Derm Venereol (Stockh)* 1983; 63: 328-334.

The immediate effects of long-wave ultraviolet irradiation (UVA) in non-erythematous doses on suprabasal melanocytes in normal skin of healthy caucasians with skin types II and III was investigated with the transmission electron microscopy (TEM) in order to detect possible morphological changes. In skin type III the melanocytes remained essentially unaltered, but in skin type II, multiple pinocytotic vesicles, large vacuoles, swelling, and partial to total dissolution of the inner membranes of the mitochondria and numerous small vesicles associated with an enlarged Golgi apparatus were observed after 3.6 to 14.5 J/cm² of UVA irradiation. No IPD reaction was observed in any of the subjects with skin type II irradiated with UVA up to 20 J/cm². *Key Words: Long-wave ultraviolet irradiation (UVA); Normal healthy caucasians; Skin type; Transmission electron microscopy (TEM); Suprabasal melanocytes; Immediate pigment darkening (IPD).* (Received December 2, 1982.)

H. Beitner, Department of Dermatology, Karolinska Sjukhuset, S-104 01 Stockholm 60, Sweden.

The increasing use of photochemotherapy in recent years has led to a new interest and rapid accumulation of information about the photobiological properties of long-wave ultraviolet light (UVA, 320-400 nm). Although signs such as erythema and immediate pigment darkening (IPD) were reported as early as in 1938 (4, 9) to follow directly upon UVA irradiation, it was assumed for many years that UVA was biologically relatively inert. In 1957, however, it was demonstrated (10) that UVA damaged dermal capillaries and caused necrosis of endothelial cells, though no major changes on the epidermal cellular level were observed. Pathak et al. (12) showed in 1962 that UVA and visible light can initiate the formation of new melanin, and this has since been confirmed in numerous reports (7). The observation by Jimbow and Fitzpatrick (5) that UVA influenced the distribution of intermediate (100 Å) filaments in suprabasal melanocytes and enhanced the formation of dendrites was confirmed in a recent paper by Lavker and Kaidbey (11). However, in the latter study, 18-20 hours after UVA irradiation, no significant changes could be observed in the fine structural appearance of the cytoplasmic organelles in the melanocytes (11).

The purpose of the present transmission electronmicroscopical (TEM) investigation was to examine the immediate effect of UVA in non-erythematous doses on subbasal melanocytes in normal skin of caucasian patients with skin types II and III.

MATERIAL AND METHODS

Subjects

Five healthy caucasian volunteers of both sexes in the age range 23 to 60 years participated in the study. Three had skin type II and 2 skin type III (Table I). No pathological reactions to solar irradiation were known in any of these subjects.

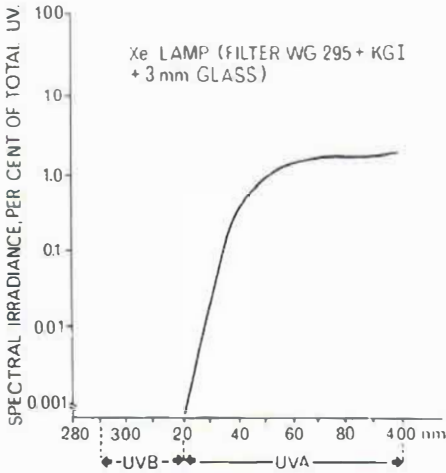


Fig. 1. Relative spectral irradiance of the Osram high pressure xenon arc lamp (XBO 150 W) equipped with a Schott WG 295 filter, a 3-mm ordinary glass filter and a KG I heat-protective filter giving long-wave ultraviolet radiation.

Classification of skin type

The normal reactions to solar radiation were evaluated for all individuals. The criteria (8) were based on the history of full sun exposure in early summer in Sweden with regard to the degree of erythema and pigmentation usually obtained, and assessed as regards the following types of reaction. Skin type I: always burn, never tan; II: always burn, sometimes tan; III: sometimes burn, always tan; IV: never burn, always tan.

Light test procedure

Light testing was performed with an Osram high pressure xenon arc lamp (XBO 150 W) in a Zeiss microscope lamp housing with a quartz collector to produce a round, uniformly bright spot, 1.5 cm in diameter, at an exposure distance of 15 cm from the filter holder to an untanned part of the gluteal region. For ordinary MED estimations the lamp was equipped with a Schott WG 295 filter giving an sun-spectrum-like radiation (15). Spectral irradiance expressed as a percentage of total UV emission was measured with a narrow bandwidth spectroradiometer system (from EG & Inc., Salem, Mass., USA, type 580/585). Calibration of the spectroradiometer was done against a 1000 W halogen lamp (G.E. DXW 1000 from Statens Provningsanstalt, Borås, Sweden). The G.E. 1000 DXW lamp used has data which can be traced to the National Bureau of Standards (NBS), USA. The reference irradiation was compared with corresponding readings from a battery-operated portable, digital, wide bandwidth radiometer J-260 with sensors for 297 and 365 nm (from Ultraviolet Product Inc, San Gabriel, Calif., USA). The calibrated instruments measured the irradiance from the xenon arc lamp at a distance of 15 cm (3, 16). The computer-plotted relative spectral irradiance curve (Fig. 1) demonstrates the absence of measurable amounts of irradiation below 320 nm, when the xenon arc lamp was equipped with the Schott WG 295, 3 mm glass and KG I filter combination. The intensity of the lamp with this filter combination was measured primarily around the 360 nm band with a Waldman UVA meter and was estimated to 7.5 mWcm^{-2} .

Table I. Skin type, minimal erythema dose (MED) of short-wave ultraviolet irradiation (UVB) and immediate pigment darkening (IPD) threshold doses for the subjects included in the study

Subject	Age (yrs)	Sex	Skin type	MED (sec)	IPD (J/cm^2)
1	60	F	II	8	>20.0
2	45	M	II	10	>20.0
3	60	F	II	6	>20.0
4	33	F	III	6	2.7
5	23	F	III	8	2.7

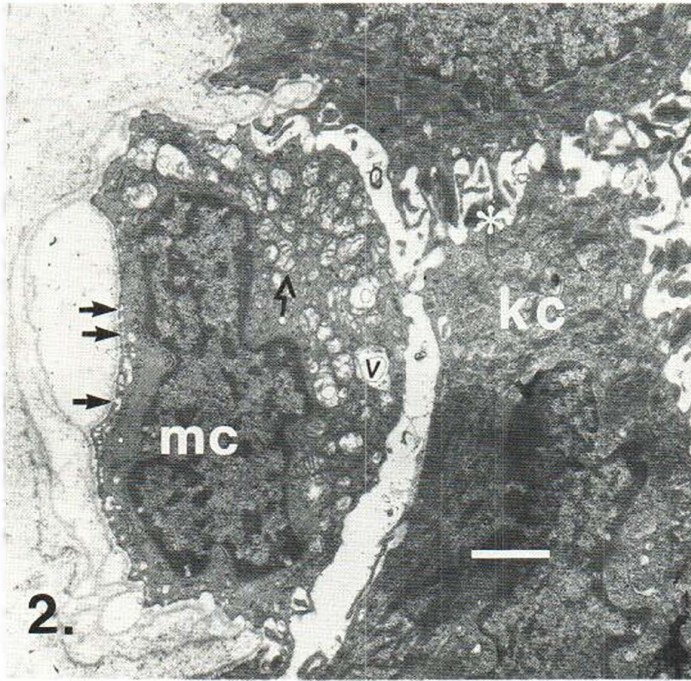


Fig. 2. Melanocyte (mc) with multiple pinocytotic vesicles (→), swollen mitochondria with partial to total dissolution of the inner membranes (→) and vacuoles (v). A melanosome (*) is seen in the intercellular space between the adjacent keratinocytes (kc). Dose UVA 3.6 J/cm², skin type II. Bar = 50 μm.

Tissue preparation

A 2-mm punch biopsy was taken before irradiation and 1, 2, 4, 8, 16 and 32 minutes afterwards, corresponding to 0.45, 0.9, 1.75, 3.6, 7.25 and 14.5 J/cm² of UVA irradiation (Table II). The specimens were immediately transferred to small UVA opaque containers at the temperature of +4°C where they were fixed in 2% glutaraldehyde in 0.1 M cacodylate + 0.1 M sucrose buffer, pH 7.4. The tissues were then post-fixed in 1% osmium-tetroxide, stained with uranyl acetate and, after dehydration through graded concentrations of ethanol and propylene oxide, embedded in Epon 812. Sections 600 Å thick were cut on an LKB ultratome and viewed in a JEOL 100 C transmission electron microscope at 60 kV.

RESULTS

Before UVA exposure

The suprabasal melanocytes had in general a large oval nucleus with few invaginations. The cytoplasm was narrow and around the nucleus intermediate filaments were seen.

Table II. UVA doses administered prior to punch biopsy (in minutes) with corresponding dose (in Joules/cm²)

Minutes	J/cm ²
0	0
1	0.45
2	0.9
4	1.75
8	3.6
16	7.25
32	14.5

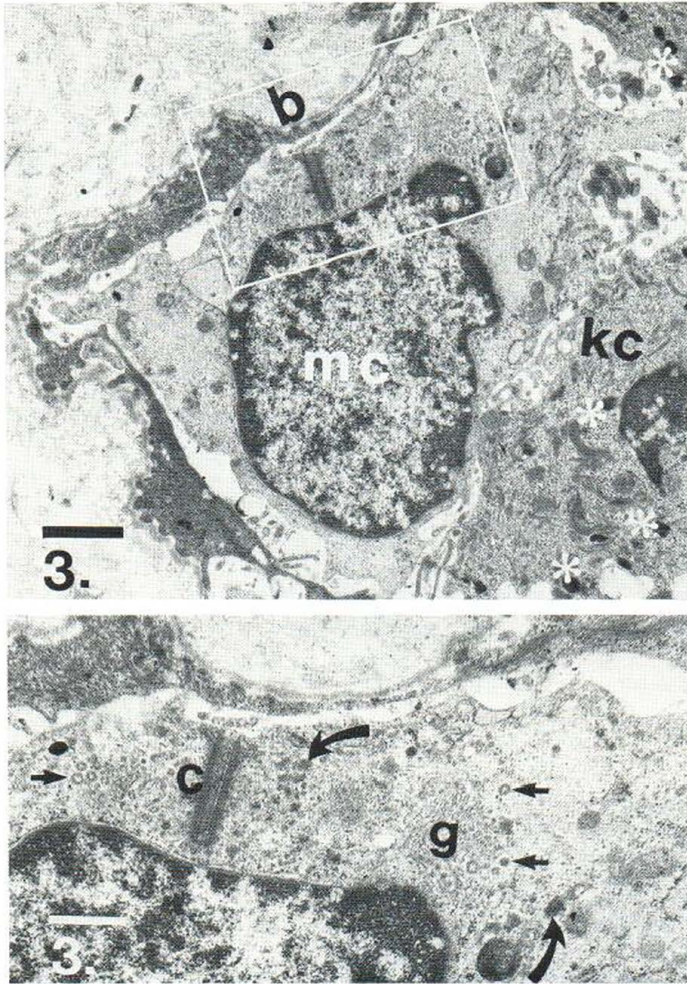


Fig. 3. a melanocyte (mc) situated on the basal lamina (b) alongside keratinocytes (kc) with melanosomes (*). Bar = 50 μm . Inset: high-power electron-micrograph of an area with numerous coated vesicles (\rightarrow) and premelanosomes (\blacktriangleright) associated with an enlarged Golgi complex (g). Cilium-like structure (c). UVA dose 14.5 J/cm^2 , skin type II. Bar = 100 μm .

Cytoplasmic organelles such as Golgi apparatus and endoplasmic reticulum were poorly developed. Melanosomes were with a few exceptions absent in skin type II melanocytes and few were observed in skin type III. The mitochondria did not appear swollen and the inner membranes were intact. The cells were identified as melanocytes by serial sectioning and tilting, which revealed the absence of tonofilaments, desmosomes and Langerhans granules.

After UVA exposure

In skin type II, multiple pinocytotic vesicles, swollen mitochondria with partial to total dissolution of the inner membranes and large solitary vacuoles developed after 3.6 J/cm^2 of UVA irradiation (Fig. 2). After 14.5 J/cm^2 , formation of numerous small vesicles associated with enlarged Golgi complexes appeared in the cytoplasm (Fig. 3). In skin type III, melanocytes with elongated dendrites and parallel bundles of intermediate filaments were observed after low doses of UVA, 0.45 J/cm^2 (Fig. 4a, b). Apart from this phenomenon, the melanocytes remained essentially unaltered (Fig. 5).

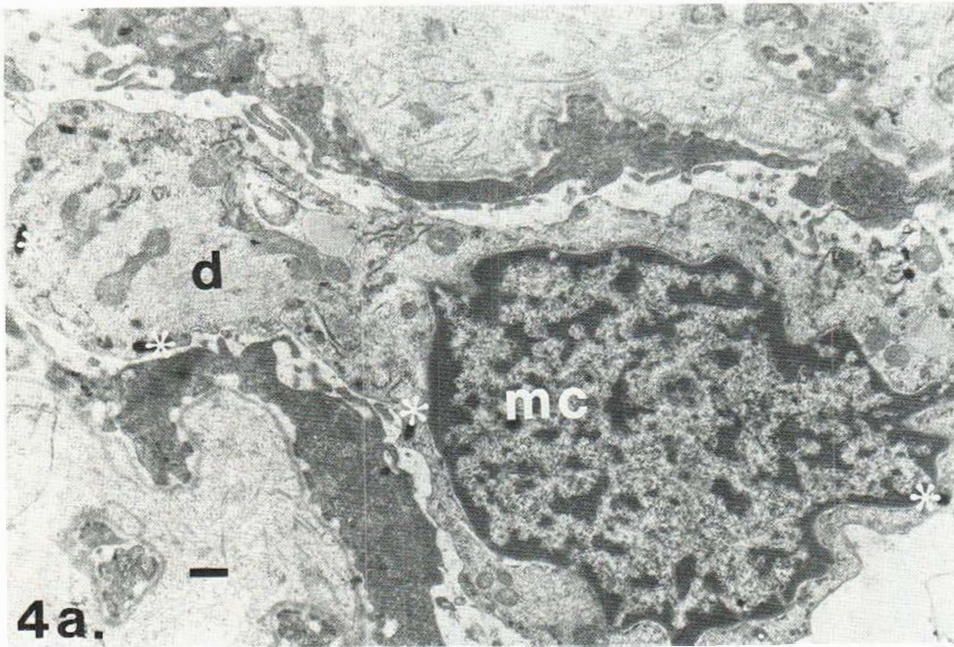


Fig. 4a. Melanocytes (mc) with an elongated dendrite (d). Bar = 10 μ m. Mature melanosomes (*) are seen in the periphery of the cell.

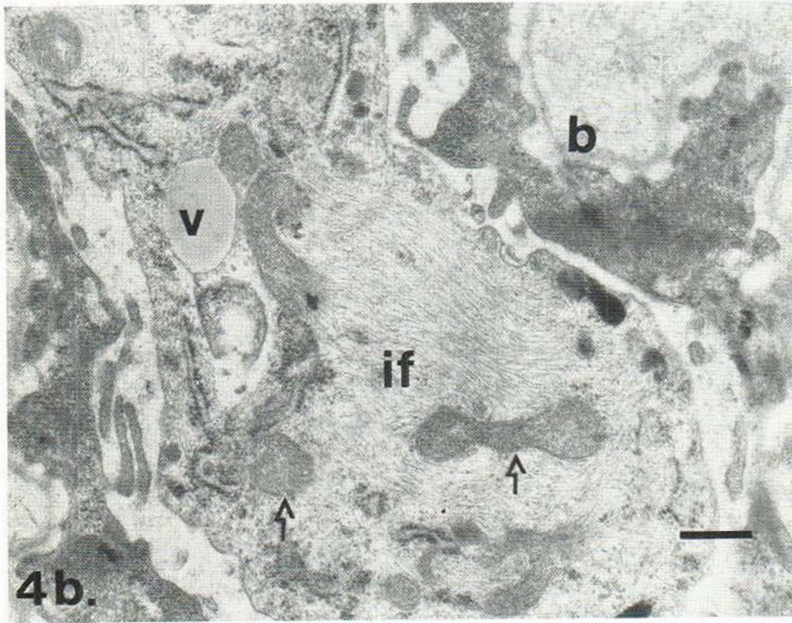


Fig. 4b. Higher magnification electron-micrograph showing parallel bundles of intermediate filaments (if) in close apposition to large mitochondria (→) and a vacuole (v). The location of the basal lamina (b) is indicated. Dose 0.45 J/cm², skin type II. Bar = 10 μ m.

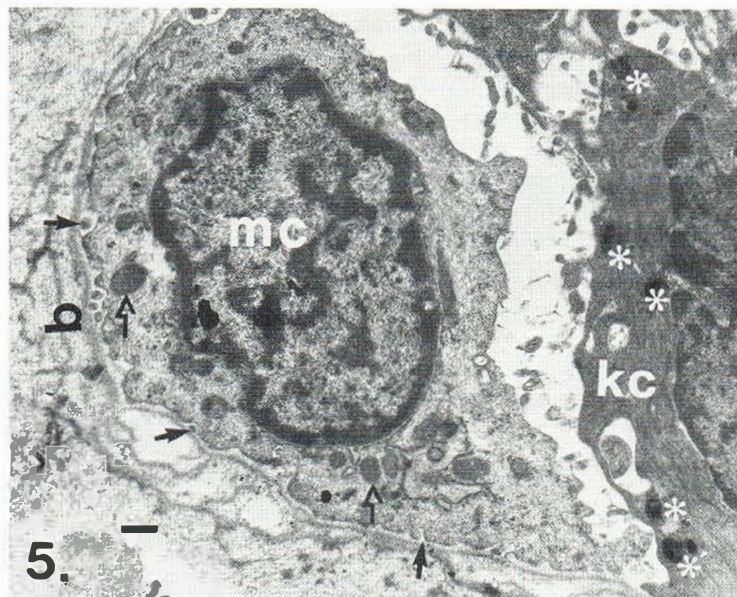


Fig. 5. Electron micrograph demonstrating an essentially unaltered melanocyte (*mc*) with numerous condensed, but well preserved mitochondria (\rightarrow). Note the pinocytotic (\blacktriangleright) activity in the periphery of the melanocyte in the area adjacent to the basal lamina (*b*). In the keratinocyte (*kc*) several grouped melanosomes (*) are seen. UVA dose 14.5 J/cm², skin type III. Bar = 10 μ m.

DISCUSSION

The enlargement of Golgi complexes and formation of small vesicles probably represents the onset of melanosomal differentiation. Jimbow & Uesugi (6) demonstrated, by combining TEM and histochemistry, that this is the case in C 57 Black mouse melanocytes. The swelling and partial to total dissolution of the inner membranes and cristae of mitochondria, seen predominantly in the irradiated melanocytes, skin type II, but not in adjacent keratinocytes, indicate a greater vulnerability to the histotechnical preparation due to a different metabolic state in these cells (14). We could not, when using TEM alone, clearly relate the elongation of dendrites and changes in distribution pattern of intermediate filaments to UVA irradiation administered. The signs of melanocyte stimulation in the form of increased pinocytotic and secretoric activity occurred in this study mainly in subjects with skin type II, while the suprabasal melanocytes in subjects with skin type III remained essentially unaltered. Thus, these results do not contradict the findings of Lavker and Kaidbey (11), since they used subjects belonging to skin types III and IV, from whom biopsies were taken 18–20 hours after irradiation. However, this stresses the importance of performing skin typing of the subjects included in this kind of experiment. We have in a previous study reported that individuals belonging to skin type II have an insufficient or absent IPD reaction, as was also observed in the subjects included in this study (Table 1). The clinical significance of the IPD reaction is still discussed, but it has been documented in previous studies that individuals with an insufficient or absent IPD reaction are more prone to develop pathological light sensitivity, actinic degeneration and cutaneous malignancies (1, 2). The combination of the absence of the IPD reaction and the occurrence of the intracellular changes demonstrated in this study could indicate that one function of the IPD reaction might be to absorb extensive UV light, thus reducing the dose reaching the melanocytes and underlying structures.

Our results seem to indicate that the intracellular changes observed in the suprabasal melanocytes are dependent on individual pigmentation capacity and on the UVA dose delivered. It should be emphasized that the biopsies were taken immediately after the

UVA exposure and in none of our patients with skin type II was any IPD reaction observed at the time for the biopsy. According to our previous report on patients with type II skin, the IPD reaction was either absent or required an UVA dose significantly greater than 9.0 J/cm^2 (1). Furthermore, the UVA doses used in the present study are significantly lower than those required to produce a MED reaction to UVA. Fair-skinned caucasians with type I and II skin have in earlier studies been found to have a MED to UVA radiation of about $29\text{--}36 \text{ J/cm}^2$ (13). The immediate ultrastructural changes in UVA-exposed melanocytes of patients with type II skin revealed in this study for UVA doses as low as 3.6 to 14.5 J/cm^2 , have not to our knowledge been described before.

ACKNOWLEDGEMENTS

We are indebted to Prof. Ulf Brunk for his support and valuable opinions. The skilful technical assistance of Erik Arro, Agneta Lukunius, Ulla Lindahl and Gunilla Nilsson are gratefully acknowledged.

This investigation was supported by grants from the Edvard Welander Foundation, the Finsen Foundation and Karolinska Institutet.

REFERENCES

1. Beitner, H. & Wennersten, G.: Clinical aspects of the immediate pigment darkening (IPD) reaction in normal individuals. *Acta Dermatovener (Stockholm)* 60: 323-326, 1980.
2. Beitner, H., Ringborg, U., Wennersten, G. & Lagerlöf, B.: Further evidence for increased light sensitivity in patients with malignant melanoma. *Br J Dermatol* 104: 289-294, 1981.
3. Fjellner, B., Hägermark, Ö.: Histamine release from rat peritoneal mast cells exposed to ultraviolet light. *Acta Dermatovener (Stockholm)* 62: 215-220, 1982.
4. Hausser, I.: Über spezifische Wirkungen des langwelligen ultravioletten Lichts auf die menschliche Haut. *Strahlentherapie* 62: 315-322, 1938.
5. Jimbow, K. & Fitzpatrick, T. B.: Changes in distribution pattern of cytoplasmic filaments in human melanocytes during ultraviolet-mediated melanin pigmentation. *J Cell Biol* 65: 481-488, 1975.
6. Jimbow, K. & Uesugi, T.: New melanogenesis and photobiological processes in activation and proliferation of precursor melanocytes after UV-exposure: Ultrastructural differentiation of precursor melanocytes from Langerhans cells. *J Invest Dermatol* 78: 108-115, 1982.
7. Kaidbey, K. H. & Kligman, A. M.: The acute effects of long-wave ultraviolet radiation of human skin. *J Invest Dermatol* 72: 253-256, 1978.
8. Melski, J. W., Tanenbaum, L., Parish, J. A., Fitzpatrick, T. B., Bleich, H. L. and 28 participating investigators: Oral methoxsalen photochemotherapy for the treatment of psoriasis: A cooperative clinical trial. *J Invest Dermatol* 68: 328-335, 1977.
9. Miescher, G. & Minder, H.: Untersuchungen über die durch langwelliges Ultraviolet hervorgerufene Pigmentdunkelung. *Strahlentherapie* 66: 6-23, 1939.
10. Miescher, G.: Zur Histologie der licht-bedingten Reaktion. *Dermatologica* 115: 345-357, 1957.
11. Lavker, R. M. & Kaidbey, K. H.: Redistribution of melanosomal complexes within keratinocytes following UV-A irradiation: A possible mechanism for cutaneous darkening in man. *Arch Dermatol Res* 272: 215-228, 1982.
12. Pathak, M. A., Riley, F. J., Fitzpatrick, T. B. & Curmen, W. L.: Melanin formation in human skin induced by long-wave ultraviolet and visible light. *Nature* 193: 148-150, 1962.
13. Parrish, J. A., Andersson, R. R., Urbach, F. & Pitts, D.: UV-A. Biological Effects of Ultraviolet Radiation with Emphasis on Human Response to Long-wave Ultraviolet, p. 119. Plenum Press, New York 1978.
14. Trump, B. F. & Arstila, A. K.: Pathobiology of Cell Membranes, vol. 1, pp. 1-52. Academic Press, New York, 1975.
15. Wennersten, G. & Swanbeck, G.: Treatment of light sensibility with carotenoids, serum concentrations and light protection. *Acta Dermatovener (Stockholm)* 54: 491-499, 1974.
16. Wester, U.: Mätmetoder vid fototerapi. Department of Radiation Physics, R.I. 1980-04, Stockholm, Sweden.