

Induction of Leukocyte Adherence at the Basement Membrane Zone with Subsequent Activation of Their Metabolic Pathway by Pemphigoid Antibodies and Complement

KEIJI IWATSUKI, HACHIRO TAGAMI and MIZUHO YAMADA

Department of Dermatology, Hamamatsu University School of Medicine, Hamamatsu, Japan

Iwatsuki K. Induction of leukocyte adherence at the basement membrane zone with subsequent activation of their metabolic pathway by pemphigoid antibodies and complement. *Acta Derm Venereol (Stockh)* 1983; 63: 290-295.

We observed in our *in vitro* studies that human leukocytes were attached by their complement receptors to the basement membrane zone (BMZ) of the skin specimens pretreated with pemphigoid antibodies and complement. The resultant histologic feature was very similar to that of an early stage of the inflammatory reactions observable in the lesions of bullous pemphigoid. Eosinophils were also attracted to the BMZ in proportion to their number in cell suspensions, but the adhesion of eosinophils occurred neither selectively nor excessively. The nitroblue tetrazolium (NBT) test, which was carried out after the leukocyte attachment test, demonstrated that only those leukocytes bound specifically to the BMZ incorporated NBT dye complexes vigorously to form formazan crystals in their cytoplasm. The present studies showed that complement-fixing anti-BMZ antibodies induce enhancement of leukocyte activities as well as immune adherence to the BMZ, indicating that the enhanced leukocyte function plays a role in the separation between epidermis and dermis in bullous pemphigoid. *Key words: Pemphigoid antibody; Immune adherence; Eosinophil; NBT test.* (Received December 13, 1982.)

K. Iwatsuki, Department of Dermatology, Hamamatsu University School of Medicine, 3600 Handacho, Hamamatsu, 431-31, Japan.

It has been proposed that the cutaneous infiltration by leukocytes and blister formation in bullous pemphigoid are caused by antibodies to the basement membrane zone (BMZ), which activate complement, thereby attracting leukocytes to the dermal-epidermal junction (11). In favorable sections of biopsy specimens, a progressive infiltration of leukocytes can be seen in the upper dermis and junctional zone prior to blister formation (5, 14). In bullous lesions, the blister cavity contains numerous eosinophils, neutrophils and mononuclear cells (13). The results of previous immunological studies on the skin lesions and blister fluid supported a possibility that complement activation mediated by pemphigoid antibodies with a subsequent accumulation of leukocytes is important in the pathogenesis of bullous pemphigoid (1, 3, 4, 11).

Recently, Gammon and co-workers (6, 7, 8) demonstrated firm evidence of an interaction between pemphigoid antibodies, complement and leukocytes in the pathomechanisms of bullous pemphigoid, using an *in vitro* assay system. However, the functional aspects of leukocytes in the pathogenesis underlying the development of blister formation remains obscure. The present studies were undertaken to define the interaction between complement-fixing anti-BMZ antibodies and leukocytes, including eosinophils, and to assess the enhancement of leukocyte function mediated by immune complexes formed at the BMZ.

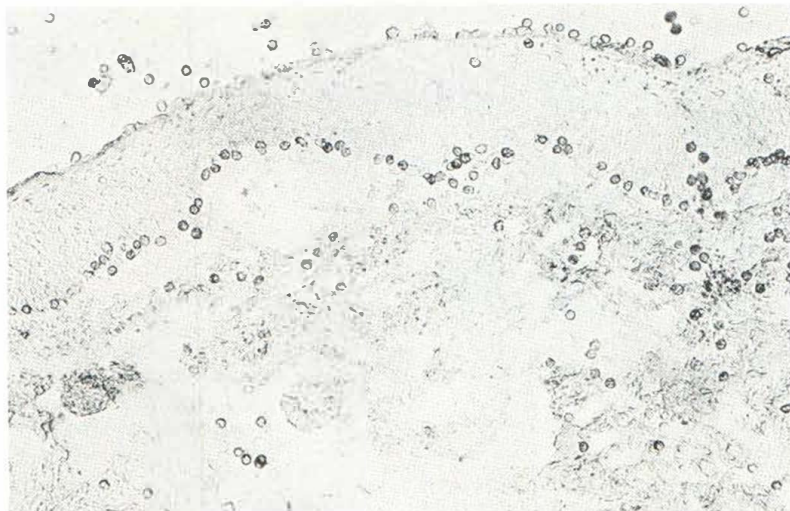


Fig. 1. Leukocytes were attached specifically to the BMZ and horny layer mediated by complement-fixing antibodies.

MATERIALS AND METHODS

1. Preparation of skin samples

Skin samples were obtained from hypertrophic scar of 3 healthy, human blood group O persons. Those samples were washed in 10% glycerin in phosphate-buffered saline (PBS, pH 7.4) for 30 min at 4°C, or snap-frozen in liquid nitrogen, and then stocked at -70°C until use.

2. Preparation of serum samples

Four samples containing antibodies to the BMZ were obtained from patients with active bullous pemphigoid. Prior to use, all serum samples were heat-inactivated at 56°C for 30 min and stocked at -70°C. Antibody titres of those sera were found to range from 1:10 to 1:320, measured by a standard indirect immunofluorescence method, utilizing the skin specimens described above as a substrate and commercially prepared fluorescein isothiocyanate-labelled antihuman IgG, IgA, IgM, IgE sera. Antibodies detected at the BMZ belonged to only IgG class in two sera, and to both IgG and IgA in the remaining two sera. Control serum samples were obtained from healthy volunteers and patients with a variety of skin disorders such as psoriasis, erythroderma, annular erythema and prurigo.

3. Preparation of leukocytes

Peripheral blood leukocytes were obtained from normal volunteers and patients with psoriasis, eczema, erythroderma, Löffler's syndrome and prurigo by dextran sedimentation of 4 ml of heparinized whole blood. Leukocyte-rich plasma was removed and centrifuged at 1000 rpm for 5 min. The supernatant was used later as a complement source. Residual red blood cells were shock-lysed by 0.2% aqueous sodium chloride, and isotonicity was then re-established by adding 1.6% sodium chloride. After centrifugation, leukocytes were resuspended in Hanks' solution with concentration of $2-3 \times 10^7$ /ml adding fresh self-plasma or heat-inactivated plasma. The percentages of eosinophils in the cell suspensions ranged from 1.4% to 63%. Viability of isolated leukocytes was greater than 97%.

4. Leukocyte attachment test

The leukocyte attachment test was carried out on skin specimens as previously described (6, 15). In brief, 8- μ m cryostat skin specimens were placed on slide glasses. The tissue specimens were allowed to dry for 30 min and then washed for 15 min in PBS. The tissue specimens were incubated with two drops of heat-inactivated 1:2 or 1:4 diluted pemphigoid or control serum for 30 min in a moist chamber, and rinsed in PBS for 15 min. After incubation with 20% fresh self-plasma in PBS for 20 min, vinyl type strips were taped around the tissue specimens treated with pemphigoid serum or control serum and complement, and then a coverglass was placed on the vinyl tape strips to form a gap between the tissue specimens and the glass. The cell suspension was poured into the gap to cover the tissue sections, and then 45 min incubation was performed at 37°C in a moist chamber. Following incubation, vinyl tape strips and the coverglass were removed and non-adherent cells were washed

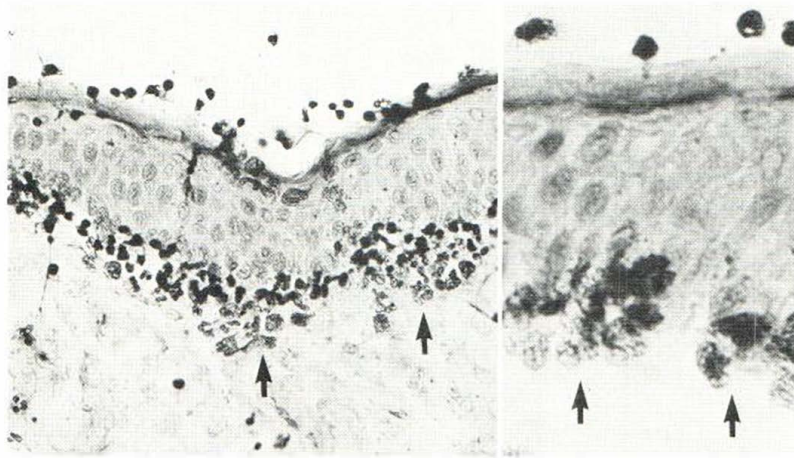


Fig. 2. Eosinophils (arrow) were also bound to the BMZ, mediated by complement-fixing anti-BMZ antibodies.

away with PBS. The tissue specimens were fixed in methanol, and stained with hematoxylin and eosin. Some slides were processed for a standard immunofluorescence study to detect deposition of IgG and C3 along the BMZ. Commercially prepared fluorescein isothiocyanate-labelled antisera to human IgG and C3 were used at a dilution of 1:20; those fluorescein to protein molar ratio were 1.3 and 1.2, respectively.

5. Nitroblue tetrazolium (NBT) test

The NBT test was performed to evaluate both phagocytotic activity and one of the metabolic pathways, the myeloperoxidase-H₂O₂-halide system, of leukocytes bound to the BMZ due to complement-fixing antibodies. Following 45 min incubation with the cell suspension in the process of the leukocyte attachment test as described above, excess cell suspension was removed gently from the gap without rinsing. The solution containing 0.6 ml of 0.28% NBT in saline, 0.5 ml of fresh plasma and 0.3 ml of saline was poured into the gap between the coverglass and the slide glass, and incubated further for a 15 min at 37°C. Formazan-forming leukocytes attached to the BMZ were easily detectable under a light microscope, in contrast to those which adhered non-specifically to the slide glass and to other portions of the tissue specimens.

RESULTS

1. Adhesion of leukocytes to the BMZ

When leukocytes suspended in Hanks' solution with fresh plasma were incubated with tissue specimens treated with anti-BMZ antibodies and complement, they were microscopically noted to attach specifically to both the BMZ and the horny layer (Fig. 1). When they were incubated with tissue specimens treated with control sera not containing anti-BMZ antibodies, leukocytes were found to adhere only to the horny layer.

In the control study carried out in the absence of a complement source, i.e., using leukocytes suspended in Hanks' solution with heat-inactivated plasma, no specific attachment of leukocytes was observed.

Hematoxylin-eosin-stained sections showed that the leukocytes attached to the BMZ and horny layer comprised neutrophils, eosinophils and a small number of monocytes (Fig. 2).

2. Immunofluorescence studies

Immunofluorescence studies performed on the tissue specimens after completing the leukocyte attachment test demonstrated deposits of IgG and C3 along the BMZ and horny

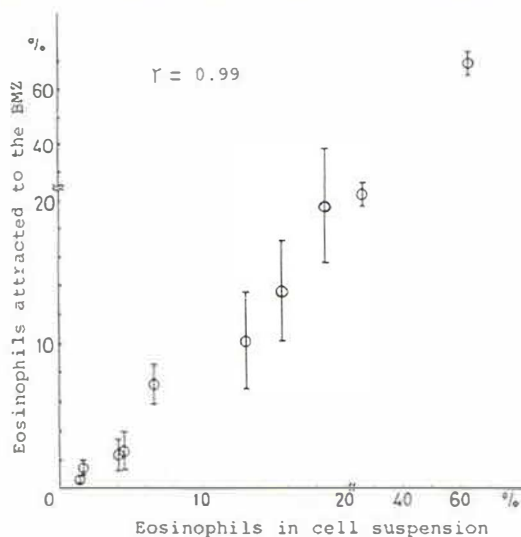


Fig. 3. Attachment of eosinophils to the BMZ, mediated by complement-fixing anti-BMZ antibodies occurring in close relation to the number of eosinophils in the cell suspension.

layer. Deposits of IgG and C3 at the horny layer were observed even in the tissue specimens incubated only with cell suspension in fresh plasma, but no such deposits could be seen at the BMZ. These results indicated that a deposit of complement-fixing anti-BMZ antibodies is specific to the sera taken from patients with bullous pemphigoid, and that deposits of IgG and C3 at the horny layer are mediated by complement-fixing anti-stratum corneum antibodies that everybody possesses in serum (12).

3. Correlation between the number of eosinophils attached to the BMZ and that in cell suspensions

The proportions of eosinophils attracted to the BMZ mediated by complement-fixing anti-BMZ antibodies were determined by counting the number of eosinophils among 200 to 400 adherent cells at the BMZ of 6 to 8 tissue specimens, and compared with those in cell suspensions. The results showed that the proportion of eosinophils attached to the BMZ

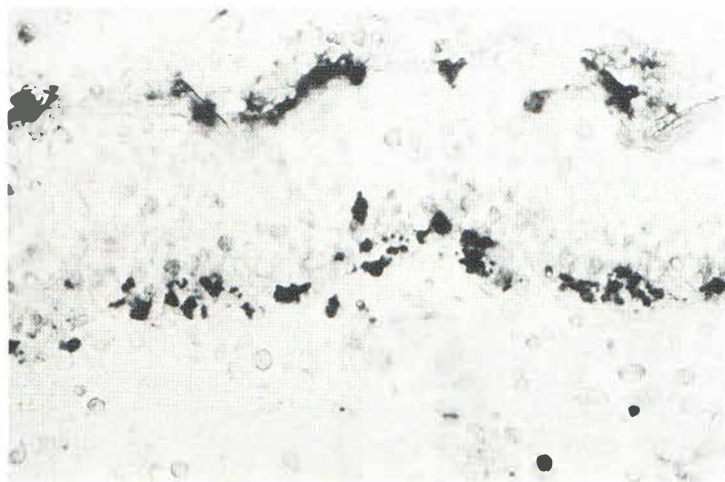


Fig. 4. Leukocytes bound to the BMZ and horny layer incorporated NBT dye complexes into their cytoplasm and formed blackish-blue crystals of formazan. Note the other leukocytes non-specifically adherent to the slide glass and tissue specimens, showing little incorporation of NBT dye complexes.

was closely related to that in the cell suspension (Fig. 3). Thus, complement-fixing anti-BMZ antibodies could also mediate the adhesion of eosinophils to the BMZ in a non-selective manner.

4. NBT test

According to a previous report (9), normal neutrophils show little incorporation of the NBT complexes unless they are stimulated to phagocytotic activity. Only stimulated neutrophils incorporate the NBT dye complexes into their cytoplasm and, after lysosomal fusion, intracellular reduction results in the formation of insoluble crystals of formazan.

Leukocytes attached to the BMZ and horny layer were found to have numerous blackish-blue formazan crystals in their cytoplasm (Fig. 4). However, leukocytes randomly adhering to the slide glass and tissue specimens had few such crystals.

DISCUSSION

Blister formation in bullous pemphigoid is a clean split between epidermis and dermis, similar to the separation one can obtain by the action of enzymes or acids or salts that act on the BMZ. Although a large number of leukocytes infiltrate the blister cavity and upper dermis, the roof of the bulla shows no degenerative changes in the early lesions (13). This fact indicates that the infiltrating leukocytes affect only the BMZ to which immunoglobulins and complement are bound.

The reports of Gammon and co-workers (6, 7, 8) on the pathomechanisms of the bullous pemphigoid using the leukocyte attachment test provide firm evidence that complement-fixing anti-BMZ antibodies attract leukocytes to the BMZ. The results of our studies further demonstrated that eosinophils are also attracted to the BMZ by the action of complement-fixing immunoglobulins bound to the BMZ. These findings may explain why numerous eosinophils exist in the blister cavity. As shown in the Fig. 3, however, complement-fixing anti-BMZ antibodies did not attract eosinophils to the BMZ selectively. Thus, an infiltration of eosinophils into the lesional skin may also be mediated by some other eosinophil chemotactic factors such as reported by previous investigators (1, 4).

It is well established that neutrophils incorporate immune complexes as well as microorganisms after immune adherence by their complement receptors. Phagocytosed immune complexes and microorganisms are killed and digested through the process of the myeloperoxidase-H₂O₂-halide system. In order to evaluate the activation of the intracellular metabolic system of leukocytes at the BMZ, we used the NBT reduction test. The results demonstrated that leukocytes attracted to the BMZ and horny layer incorporated NBT dye complexes into the phagosomes and that the NBT dye complexes were converted into blackish-blue crystals of formazan by the process of intracytoplasmic reduction. Thus, both leukocytes bound to the BMZ and those bound to the horny layer were stimulated to phagocytotic and metabolic activities by complement-fixing anti-BMZ antibodies and by anti-stratum corneum antibodies, respectively. This enhanced function of leukocytes at the BMZ may result in release of lysosomal enzymes and superoxides, causing a separation between the epidermis and dermis, as noted in bullous pemphigoid. It has also been proposed that eosinophil peroxidase in the granules reacts with H₂O₂ and a halide to generate toxic complexes capable of damaging target cells or tissues (5, 10). However, the role of eosinophils in the blister formation of bullous pemphigoid remains obscure, as they also have regulatory effects for enzymes derived from mast cells and other inflammatory agents (2). In early lesions of bullous pemphigoid, the feature showing that leukocytes are lining along the BMZ is occasionally seen in favorable sections, which suggests that the mechanisms mentioned above may actually occur at the BMZ in vivo.

The present studies provided further evidence that the enhanced function of leukocytes, including eosinophils, mediated by the interaction between antibodies and complement, plays an important role in the inflammatory responses observed in bullous pemphigoid.

ACKNOWLEDGEMENTS

This work was supported by Grant-in-aid for Scientific Research 457269 and 557252 from the Ministry of Education, Japan, and the Basic Research Grant from the Japanese Dermatological Association.

REFERENCES

1. Baba, T., Sonozaki, H., Seki, K., Uchiyama, M., Ikesawa, Y. & Torisu, M.: An eosinophil chemotactic factor present in blister fluid of bullous pemphigoid patients. *J Immunol* 116:112, 1976.
2. Cohen, S. G. & Ottesen, E. A.: Eosinophils in immune function. *In Cellular Function in Immunity and Inflammation* (ed. J. J. Oppenheim, D. L. Rosensteich & M. Potter), 1st ed., 103 pp. Edward Arnold, New York, 1981.
3. Diaz-Perez, J. L. & Jordon, R. E.: The complement system in bullous pemphigoid. IV. Chemotactic activity in blister fluid. *Clin Immunol Immunopathol* 5:360, 1976.
4. Dierksmeier, U., Frosch, P. J. & Czarnetzki, B. M.: Eosinophil chemotactic factor (ECF) in blister fluid of dermatological diseases. *Br J Dermatol* 102:43, 1980.
5. Dubertret, L., Bortaux, B., Fossec, M. & Touraine, R.: Cellular events leading to blister formation in bullous pemphigoid. *Br J Dermatol* 104: 615, 1980.
6. Gammon, W. R., Lewis, D. M., Carlo, J. R., Sams, W. M. Jr & Wheeler, C. E., Jr: Pemphigoid antibody mediated attachment of peripheral blood leukocytes at the dermal-epidermal junction of human skin. *J Invest Dermatol* 75:334, 1980.
7. Gammon, W. R., Merritt, C. C., Lewis, D. M., Sams, W. M. Jr, Wheeler, C. E., Jr & Carlo, J. R.: Leukocyte chemotaxis to the dermal-epidermal junction of human skin mediated by pemphigoid antibodies and complement; Mechanisms of cell attachment method. *J Invest Dermatol* 76:514, 1981.
8. Gammon, W. R., Merritt, C. C., Lewis, D. M., Sams, W. M. Jr, Carlo, J. R. & Wheeler, C. E., Jr: An in vitro model of immune complex-mediated basement membrane zone separation caused by pemphigoid antibodies, leukocytes, and complement. *J Invest Dermatol* 78:285, 1982.
9. Hudson, L. & Hay, F. C.: Cellular dynamics in vivo. *In Practical Immunology*, 2nd ed. 78 pp. Blackwell Scientific Publications, Oxford, 1980.
10. Jong, E. C. & Klebanoff, S. J.: Eosinophil-mediated mammalian tumor cell cytotoxicity: Role of the peroxidase system. *J Immunol* 124:1949, 1980.
11. Jordon, R. E.: The complement system in pemphigus and bullous pemphigoid. *In Immunopathology of the Skin* (ed. E. H. Beutner, T. P. Chorzelski & S. F. Bean), 2nd ed., 135 pp. Wiley, New York, 1979.
12. Krogh, H. K. & Tönder, O.: Stratum corneum antigens and antibodies. *In Immunopathology of the Skin* (ed. E. H. Beutner, T. P. Chorzelski & S. F. Bean), 2nd ed. 413, pp. Wiley, New York, 1979.
13. Pinkus, H. & Mehregan, A. H.: *A Guide to Dermatohistopathology*. 3rd ed. 135 pp. Appleton-Century-Crofts, New York, 1981.
14. Schaumberg-Lever, G., Orfanos, C. E. & Lever, W. F.: Electron microscopic study of bullous pemphigoid. *Arch Dermatol* 106:662, 1972.
15. Yamamoto, T., Kihara, I., Morita, T. & Oite, T.: Attachment of polymorphonuclear leukocytes to glomeruli with immune deposits. *J Immunol Method* 26:315, 1979.