

to the effect of chlorpheniramine and cimetidine on dermographic wealing. A further problem with both the study of Matthews et al. (9) and our own is that although the dose of cimetidine used was probably adequate for H<sub>2</sub> receptor antagonism, the dose of chlorpheniramine used for a therapeutic effect was too low.

The clinical relevance of our findings is not clear because despite the very similar effects on histamine wealing of the same H<sub>1</sub> and H<sub>2</sub> antagonists (1) the combination of cimetidine and chlorpheniramine appears not to add to the response of chronic idiopathic urticaria to the H<sub>1</sub> antagonist alone (1); indeed the itch was slightly worse (1). Although there was no increased itching in our patients with dermographism, they were only given a single dose of the antagonists, whereas in the study of Matthews et al. (9), where the drugs were given over a period of weeks, there was some increase in itch similar to that which we had found in chronic idiopathic urticaria. This cannot be due to a general effect of H<sub>2</sub> antagonists on histamine metabolism (10) nor to an inhibition of the negative feed-back of histamine on the mast cell (7), as the dermographic weal size would have been increased which it was not (3). However, there is evidence that histamine wealing leads to release of secondary mediators (2); one possibility is that of a change in production of a nonwealing pruritic agent in the dermis or a wealing or non-wealing pruritogen in small quantities but high concentrations locally at the itch receptors during prolonged administration of H<sub>2</sub> receptor blockers.

Finally, whilst our evidence that the dermographic weal response can be reduced by a combination of an H<sub>1</sub> and H<sub>2</sub> antagonist suggests the involvement of both receptors, in the absence of full dose-response studies to establish the effect of maximum H<sub>1</sub> and H<sub>2</sub> receptor blockade, it is impossible to assess the degree of involvement of these two receptor classes in dermographism. Thus we cannot conclude from the present observation that the combination of H<sub>1</sub> and H<sub>2</sub> antagonists will necessarily be of any advantage in the treatment of dermographism over an effective H<sub>1</sub> antagonist by itself.

#### REFERENCES

1. Cook, L. J. & Shuster, S.: Lack of effect of H<sub>2</sub> blockade in chronic urticaria. *Br J Dermatol* 101, Suppl. 17: 20-21, 1979.

2. — Histamine weal formation and absorption in man. *Br J Pharmacol* 69: 579-586, 1980.
3. — Persistence of histamine weals and production of secondary vasoactive agents. *J Invest Dermatol* 74: 6, 460, 1980.
4. Davies, M. G. & Greaves, M. W.: The current status of histamine receptors in human skin: therapeutic implications. *Br J Dermatol* 104: 601, 1981.
5. Greaves, M. W. & Sondergaard, J.: Urticaria pigmentosa and factitious urticaria. *Arch Dermatol* 101: 418, 1970.
6. Kirby, J. D. & Matthews, C. N. A., James, J., Duncan, E. H. L. & Warin, R. P.: The incidence and other aspects of factitious wealing (dermographism). *Br J Dermatol* 85: 331, 1971.
7. Lichtenstein, L. M. & Gillespie, E.: Inhibition of histamine release by histamine controlled H<sub>2</sub> receptor. *Nature* 244: 287, 1973.
8. Marks, R. & Greaves, M. W.: Vascular reactions to histamine and compound 48/80 in human skin. Suppression by a histamine H<sub>2</sub> blocking agent. *Br J Clin Pharmacol* 4: 367, 1977.
9. Matthews, C. N. A., Boss, J. M., Warin, R. P. & Storari, F.: Effect of H<sub>1</sub> and H<sub>2</sub> antagonists on symptomatic dermographism. *Br J Dermatol* 101: 1, 57, 1979.
10. Yamamoto, S., Francis, D. & Greaves, M. W.: In vitro anaphylaxis in guinea-pig skin: amplification by burimamide. *J Invest Dermatol* 67: 696, 1976.

### Successful Treatment of Cold Angio-Oedema by H<sup>2</sup>-Antihistamine Therapy

P. Klemp, B. Staberg,<sup>1</sup> N. Agdal and  
I. M. Munkvad

*Departments of Dermatology and Clinical Physiology,  
The Finsen Institute, DK-2100 Copenhagen, Denmark*

Received October 29, 1982

**Abstract.** Two patients with severe cold angio-oedema were practically relieved from their symptoms during H<sub>2</sub>-blocker therapy (cimetidine 1000 mg daily). Classic H<sub>1</sub>-blocker therapy had no effect on their symptoms and combined H<sub>1</sub>- and H<sub>2</sub>-blocker treatment was just as effective in ameliorating the symptoms of cold angio-oedema as H<sub>2</sub>-blocker treatment alone. A low dose of the H<sub>2</sub>-blocker (400 mg cimetidine daily) was almost able to control the angio-oedema formation after cold exposure, but provoked typically urticarial lesions. This observation strongly indicates that H<sub>2</sub>-receptors may play an important role in the pathogenesis of cold angio-

oedema and that a massive, subcutaneous, cold angio-oedema may obscure cold urticarial lesions.

**Key words:** Cold angio-oedema; Cimetidine; Cold urticaria

Severe cold angio-oedema is a rare, potentially life-threatening disorder primarily affecting the subcutaneous tissue (7). Cold stimulus immediately provokes a transient itching and a persistent monstrous swelling of the exposed skin area. Urticarial lesions are not seen.

Moderate swelling involving the deep dermis after cold exposure might also be seen in the parallel condition, cold urticaria, which is a common and often harmless phenomenon characterized by typically urticarial lesions after cold stimuli (1).

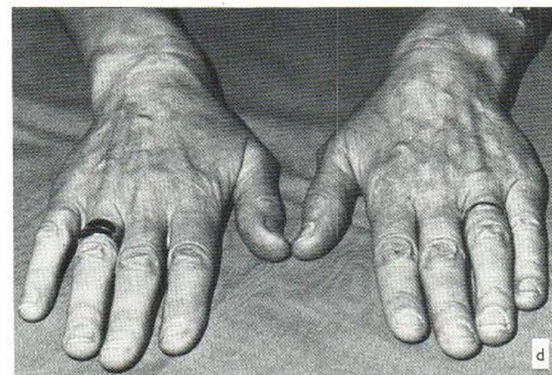
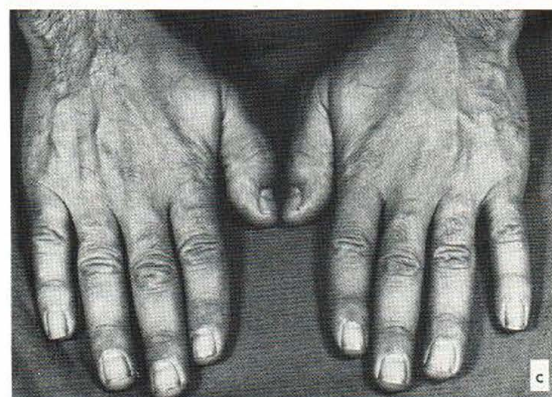
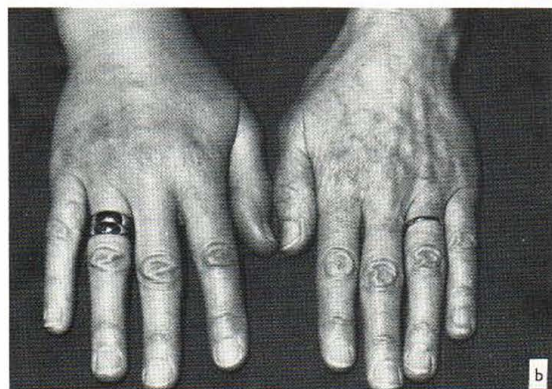
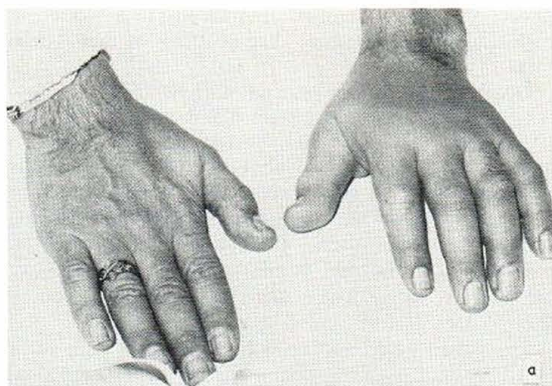
The etiology of these disorders is not known. To solve this problem most experiments have been carried out in patients with cold urticaria and histamine release might be one possible pathogenic factor (4, 5). Classic antihistamine therapy has been reported to be the drug of choice in cold urticaria (3), but these drugs have not proved successful in controlling oedema formation in patients with cold angio-oedema.

Recently, combined  $H_1$ - and  $H_2$ -antihistamine agents and hydrocortisone were used successfully in a patient with cold angio-oedema during heart surgery in hypothermic cardiopulmonary bypass (2).

We have treated 2 patients with severe cold angio-oedema with a  $H_2$ -blocker (cimetidine). This therapy proved to be extremely effective in ameliorating the symptoms of cold angio-oedema. As far as we know, this is the first reported case of successful treatment of cold angio-oedema with a  $H_2$ -blocker alone.

### CASE REPORTS

Two patients, a 34-year-old man and a 57-year-old woman, presented with a 10–12-year history of typical, severe cold angio-oedema. Cold stimulus provoked an intense itching and a monstrous swelling of the exposed skin area lasting for 8–12 hours or even more. Both patients had learned to live with their symptoms by avoiding any cold stimuli. Shortly before the referral to our clinic



*Fig. 1.* Cold angio-oedema in 2 patients after exposure to cold water for 3 min (picture *a* and *b*). Below is seen the same hands after the cold test during cimetidine treatment. All photos were taken 2 min after the cold test.

one of the patients fainted dramatically in a swimming bath. Classic antihistamines had no effect on their symptoms.

General examinations were normal and standard laboratory studies including complete blood count,  $C_3$ ,  $C_4$  and  $C_1$ -esterase inhibitor, immunoglobulins were normal and cryoglobulins, cold agglutinins and cold haemolysins were not found. A cold test, application of cold water ( $+4^\circ\text{C}$ ) on the dorsum of the hand, provoked oedema of the whole hand after 3 min and, simultaneously, the patients felt an intense, painful itching and a transient physical discomfort. The oedema persisted for 8–36 hours (Fig. 1). Urticarial lesions were not observed.

The patients began a fortnight's treatment with combined  $H_1$ - and  $H_2$ -antihistamine therapy (cyproheptadine 16 mg daily and cimetidine 1000 mg daily). During the first few days both patients experienced how the cold angio-oedema symptoms had disappeared, allowing them to wash hands in cold water, to walk outdoors in cold weather and drink cold drinks without taking any particular precautions. However, both patients complained of drowsiness, which they had earlier experienced during  $H_1$ -blocker treatment. A new cold test provoked only a discrete swelling of the hand and a weak, short-lasting itching.

The drug therapy was stopped for one week during which the cold angio-oedema symptoms reappeared. This was confirmed by a cold test which provoked massive, long-lasting oedema.

The patients were then treated with cimetidine 1000 mg daily for one week, during which time the patients again were relieved of their symptoms. A cold test provoked only discrete oedema of the hand (Fig. 1). The treatment was then stopped for one week and a new cold test provoked massive oedema and itching.

Shortly after these experiments the male patient got a divorce and he emigrated to a warmer climate (Jordan).

The female patient was treated with a lower dose of cimetidine in order to find the tolerated dose, which gave no symptoms of cold angio-oedema. With a daily dose of 400 mg cimetidine the angio-oedema was almost controlled, but during this treatment she developed typically urticarial lesions after cold exposure and she now fulfilled the generally accepted criteria of the diagnosis 'cold urticaria'.

She has now received 800–1000 mg cimetidine daily for the last 8 months and, apart from a mild itching sensation after cold exposure, she is free from any symptoms of cold angio-oedema.

### COMMENT

The inability of the conventional antihistamine to produce consistent suppression of cold angio-oedema formation may be explained by the fact that histamine may be only one of several chemical mediators capable of producing the vascular changes observed (3). Failure might also be ascribed to inappropriate therapeutic doses, as drowsiness and dizziness are well-known side effects

of high doses of these classic  $H_1$ -antihistamines (8). Evidence also shows that human skin possesses  $H_2$ -receptors (6) which are not blocked by these classic antihistamines.

Our observations show that  $H_2$ -receptors may play an important role in the pathogenesis of cold angio-oedema. Furthermore, a low dose of cimetidine was able to reduce the cold angio-oedema formation, but provoked typical urticarial lesions after cold exposure. These findings strongly indicate that an urticarial lesion might be obscured by a massive, subcutaneous, cold angio-oedema.

### REFERENCES

1. Champion, R. H., Roberts, S. O. B., Carpenter, R. G. & Roger, J. H.: Urticaria and angio-oedema. *Br J Dermatol* 81: 588, 1969.
2. Johnston, W., Moss, I., Philbin, D. M., Guiney, T. E., Sisson, I. H., Buckley, M. I. & Lowenstein, E.: Management of cold urticaria during hypothermic cardiopulmonary bypass. *N Engl J Med* 306: 219, 1982.
3. Jorizzo, J. L. & Smith, E. B.: The physical urticarias. *Arch Dermatol* 118: 194, 1982.
4. Kaplan, A. P. & Beaven, M. A.: In vivo studies of the pathogenesis of cold urticaria, cholinergic urticaria and vibration-induced swelling. *J Invest Dermatol* 67: 327, 1976.
5. Kaplan, A. P., Garofalo, I., Sigler, R. & Hauber, T.: Idiopathic cold urticaria: In vitro demonstration of histamine release upon challenge of skin biopsies. *N Engl J Med* 305: 1074, 1981.
6. Monroe, E. N., Cohen, S. H., Kalbfleisch, J. & Schulz, C.: Combined  $H_1$  and  $H_2$  antihistamine therapy in chronic urticaria. *Arch Dermatol* 117: 404, 1981.
7. Sheldon, J. M., Mathews, K. P., Lovell, R. G. & Arbor, A.: The vexing urticaria problem: Present concepts of etiology and management. *J Allergy* 25: 525, 1954.
8. Sigler, R. W., Evans, R., Horakova, Z., Ottesen, E. & Kaplan, A. P.: The role of cyproheptadine in the treatment of cold urticaria. *J Allergy Clin Immunol* 65: 312, 1980.