

SHORT REPORTS

Quantification of Alkaline Phosphatase in Lesions and Uninvolved Skin of Psoriatic Patients

P. C. M. van de Kerkhof, Helga van Rennes
and P. D. Mier

*Department of Dermatology, University of Nijmegen,
Javastraat 104, 6524 M. J. Nijmegen, The Netherlands*

Received July 28, 1982

Abstract. Alkaline phosphatase (ALP) has been quantified in psoriatic skin for the first time. The levels of both the soluble and the particulate forms of this enzyme were grossly elevated in psoriatic lesions; by contrast, levels in the clinically uninvolved skin of the patient were normal. The changes in the lesion cannot be explained solely in terms of vasodilatation, since UVR-induced erythema was accompanied only by a modest increase in soluble ALP activity.

Key words: Alkaline phosphatase; Psoriasis; UVR

Many investigators have studied the histochemical localization of alkaline phosphatase (3.1.3.1, ALP) in normal human skin and in various pathological conditions (2, 3, 6). There is general agreement that a marked increased staining of the capillary loop may be seen in the psoriatic lesion. However, despite reports of structural changes in the capillaries of clinically uninvolved skin of patients with psoriasis (4), the intensity of ALP staining in the uninvolved skin seems to be normal (7).

We have recently developed a sensitive fluorimetric microassay for ALP and have described the properties of the cutaneous enzyme (5). Here we present the first quantitative data regarding ALP in psoriasis. For comparative purposes, ALP levels have also been determined during UVR-induced erythema of normal human skin.

MATERIALS AND METHODS

Subjects

Psoriatic patients were selected who had stable, chronic lesions which had not been treated for at least one week; biopsies were taken either from the central region of a well-established plaque or from the clinically healthy skin

at least 20 cm distance from a lesion. Control specimens were obtained from the upper back of paid volunteers with no personal or family history of psoriasis. In certain experiments a site (2 cm diameter) on the back of control subjects was irradiated with 3 times the minimal erythema dose using whole-spectrum emission from a xenon arc (XBO 150, Osram, Germany) 16 h prior to biopsy.

Biopsy

All specimens were cut freehand using a razorblade in combination with a metal 'guard' (hole 4 mm diameter). No anaesthetic agent was employed. Biopsies averaged about 2 mg fresh weight; direct histological examination indicated that the central area included all epidermal layers plus some underlying dermis.

ALP assay

Biopsies were homogenized in 500 μ l of bovine serum albumin solution (1 mg/ml) using an all-glass Potter-type homogenizer fitted with an ice-jacket. The homogenate was centrifuged to yield a clear supernatant ('soluble ALP'); the residue was washed once and resuspended in 500 μ l bovine serum albumin solution ('particulate ALP').

ALP was assayed as described previously (5). Briefly, duplicate 20 μ l samples were incubated with 20 μ l of a solution of 0.5 mM 4-methylumbelliferyl phosphate at pH 9.8 containing 5 mM NaF to avoid possible interference from epidermal acid phosphatase. After 1 h at 37°C the reaction was stopped by the addition of 1 ml carbonate buffer (pH 10.5) and the 4-methylumbelliferone released was determined by fluorescence.

RESULTS

Levels of soluble and particulate ALP activity are shown in Figs. 1 and 2 respectively. It is seen that both forms of the enzyme are grossly increased in the psoriatic lesion ($p < 0.001$ in both cases, Wilcoxon ranking test). By contrast, all specimens from the clinically uninvolved skin of the psoriatic patients fell within the normal range.

In the case of the irradiated control specimens, there was a relatively modest but statistically significant ($p < 0.05$) increase in the soluble ALP activity; this was not accompanied by any change in the level of the particulate enzyme.

DISCUSSION

These data confirm the histochemical reports regarding ALP staining in psoriasis. Furthermore,

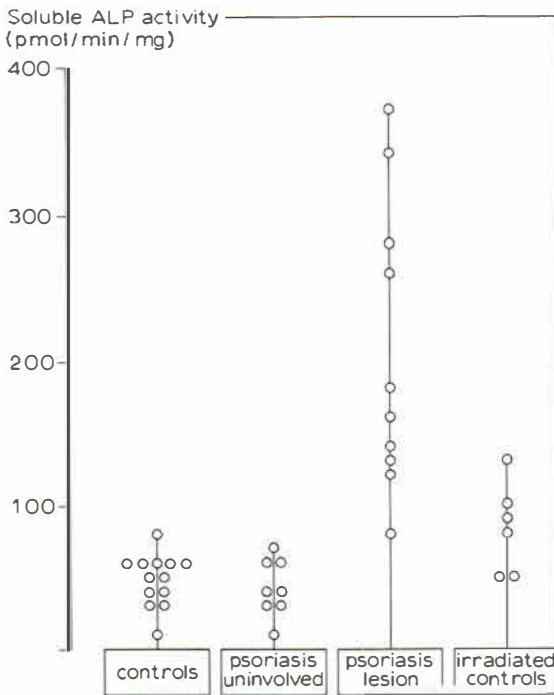


Fig. 1. Levels of soluble ALP in the individual specimens.

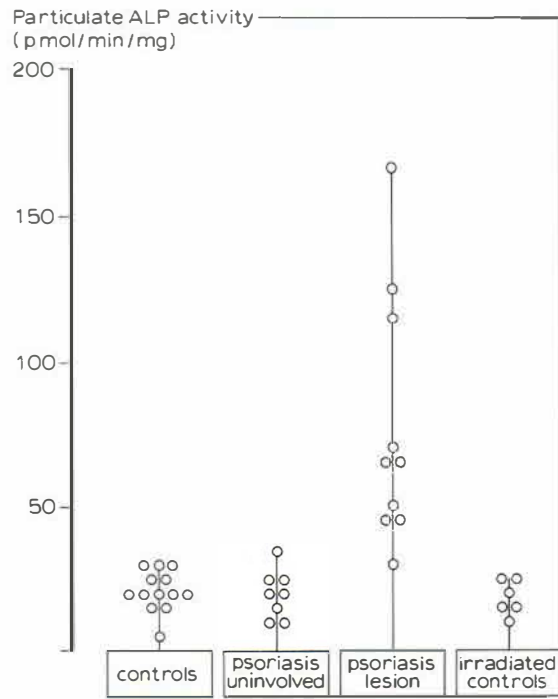


Fig. 2. Levels of particulate ALP in the individual specimens.

the sharp distinction between ALP levels in the psoriatic lesions and those in the irradiated control biopsies indicate that the psoriatic abnormality cannot be interpreted simply as a metabolic consequence of vasodilatation. Indeed, it is likely that there is in fact no change in the cellular levels of ALP during UVR-induced erythema, since the slight increase in the soluble enzyme is compatible with the larger volume of plasma 'trapped' in the dilated vessels. Histochemical evidence suggests that the inflammatory infiltrate might contribute to the elevated ALP levels in the psoriatic lesion (1). However, since the infiltrate is well established at 16 h after UVR (personal communication, Prof. G. Volden, Tromsø) and since the particulate levels of ALP in these specimens were normal, we may exclude this possibility as a major contribution in psoriasis.

Whether or not our findings are specific for psoriasis must, of course, await a more extensive investigation. The quantitative technique described here would in any case seem to offer a more sophisticated approach to the study of dermatoses in which abnormalities of the dermal capillaries are a prominent feature.

REFERENCES

- Braun-Falco, O. & Burg, G.: Das entzündliche Infiltrat bei Psoriasis vulgaris. *Arch Klin Exp Dermatol* 236: 297, 1970.
- Fisher, I. & Glick, D.: Histochemistry. XIX. Localization of alkaline phosphatase in normal and pathological human skin. *Proc Soc Exp Biol Med* 66: 14, 1947.
- Kopf, A. W.: The distribution of alkaline phosphatase in normal and pathologic human skin. *Arch Dermatol* 75: 1, 1957.
- Madden, J. F.: Histologic studies of uninvolved skin of patients with psoriasis. *Arch Dermatol Syphilol* 44: 655, 1941.
- Mier, P. D. & van Rennes, H.: Cutaneous alkaline phosphatase: a biochemical study. *Arch Dermatol Res.* In press.
- Pirilä, V. & Eränkö, O.: Distribution of histochemically demonstrable alkaline phosphatase in normal and pathological human skin. *Acta Pathol Microbiol Scand* 27: 650, 1950.
- Wohlrab, W. & Grüneberg, T.: Histochemische Befunde an der klinisch gesunden Haut von Psoriatikern. *Arch Klin Exp Dermatol* 225: 259, 1966.