

THE T-LYMPHOCYTE AND CUTANEOUS CHURG-STRAUSS GRANULOMA

R. K. Winkelmann, Stanislav A. Buechner, Frank C. Powell and Peter M. Banks

Department of Dermatology and Section of Surgical Pathology, Mayo Clinic and Mayo Foundation, Rochester, Minnesota, USA

Abstract. Studies of biopsy specimens from 4 patients with Churg-Strauss granulomas of the skin were performed with monoclonal antibodies to T-lymphocyte subset antigens. The finding of a predominance of a LEU3 antibody-reactive helper T-cell population in the perivascular areas and in the palisading and central granuloma areas was noteworthy. Pronounced reduction of suppressor T-cells in the lesions was observed in 2 patients; the lesions were associated with vasculitis and rheumatoid arthritis in one patient and with vasculitis and lupus erythematosus in the other. The Churg-Strauss granuloma demonstrated features of a cutaneous helper T-cell granuloma.

Key words: Churg-Strauss granuloma; Cutaneous granuloma; Immunologic findings in Churg-Strauss granuloma; T-cells; T-lymphocytes; Allergic granulomatosis

The Churg-Strauss granuloma is a cutaneous necrotizing extravascular granuloma associated with systemic vasculitis, usually in the form of allergic granulomatosis (6, 9, 17, 20). Necrotizing vasculitis in the large and small vessels of the skin and viscera may also be found (4, 5, 7). The coexistence of immune-complex vasculitis and granulomatous vasculitis suggests that the granuloma may represent a reactive change in the host which is associated with the vasculitis. Granulomatous vasculitis might develop from an immune-complex vasculitis that would include lymphocytic cell-mediated vascular inflammation and then evolve into the allergic granuloma or Wegener's granulomatosis (11), depending on lymphocyte responsiveness. Using monoclonal antibodies to detect human T-cell subsets, we studied skin biopsy specimens from 4 patients with Churg-Strauss extravascular cutaneous necrotizing granuloma. T-lymphocytes were consistently found in perivascular and granulomatous areas.

METHODS

Biopsy specimens were taken for lymphocyte studies from 4 patients with cutaneous Churg-Strauss granuloma.

All 4 cases will be reported *in extenso* elsewhere. Each patient presented with symmetrical papulopurpuric and infarctive lesions on the elbows and knees. One patient also had isolated lesions on the distal digits of the hands and feet. Two patients had systemic allergic granulomatosis, and one of these also had well-differentiated lymphocytic lymphoma. One patient had rheumatoid arthritis and rheumatoid vasculitis, and the fourth patient had vasculitis associated with systemic lupus erythematosus. The histopathologic features were studied by reviewing multiple sections stained with hematoxylin and eosin. The diagnosis was established according to the criteria of Dicken & Winkelmann (9, 20).

Portions of 5-mm punch biopsy specimens removed for diagnostic purposes were immediately frozen in liquid nitrogen. Cryostat sections (4 to 6 μ m) were studied for the presence of various T-cell subsets (10, 13, 16). The monoclonal antibodies (Becton-Dickinson, Sunnyvale, CA 94086) employed in this study were as follows: anti-LEU1, which reacts with 95% of human thymocytes, all of the peripheral T-lymphocytes, and activated T-cells; anti-LEU2A, which reacts with peripheral T-cells involved in cell-mediated cytotoxicity and suppression (TH_2 cells), which comprise 20 to 40% of normal human peripheral blood lymphocytes; and anti-LEU3A, which is reactive with helper-inducer T-cell subset (TH_2 cells), which comprises 40 to 60% of normal lymphocytes.

The detection of hybridoma antibody binding to these cells was determined by peroxidase-conjugated goat-antimouse IgG (Tago, Burlingame, CA 94010), utilizing a peroxidase histochemical reaction. Similar monoclonal antibodies against human κ and λ light chains of immunoglobulins were used to demonstrate B-cell (12).

In addition, we studied the distribution of infiltrating macrophages-histiocytes, using established histochemical reactions. Cryostat sections were stained for the presence of acid phosphatase (15) and α -naphthyl butyrate esterase (14) (non-specific esterase). Histiocytes display a strong diffuse intracytoplasmic activity of acid phosphatase and non-specific esterase (3). In contrast, stimulated T-lymphocytes show a strong focal acid phosphatase activity (8) that is largely confined to the Golgi area.

RESULTS

Biopsy specimens from skin lesions in all 4 patients demonstrated palisading, necrotizing granulomas in the dermis, characteristic of the Churg-Strauss granuloma (Fig. 1). The central basophilic necrosis

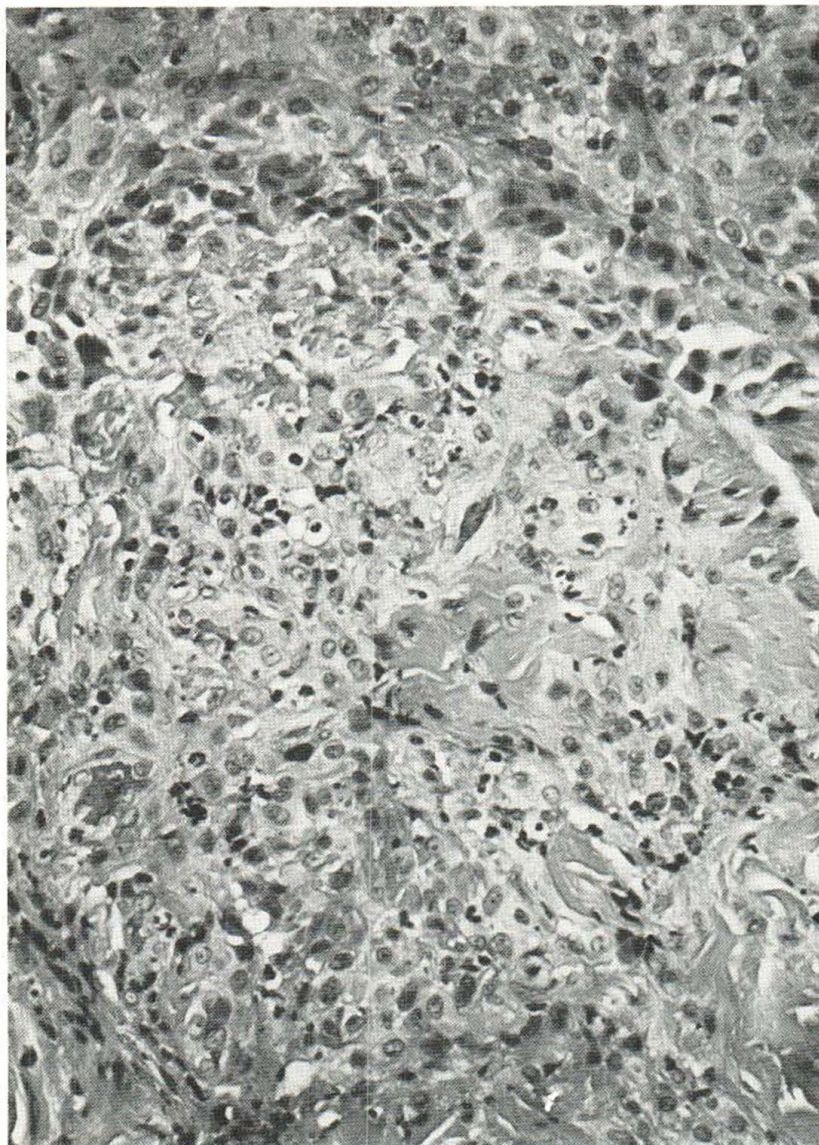


Fig. 1. Churg-Strauss granuloma showing central fibrillar collagen degeneration surrounded by palisading histiocytes (Hematoxylin and eosin; $\times 250$).

was associated with leukocytoclastic polymorphonuclear leukocytes infiltrated about hyalinized and necrobiotic collagen. Infiltrated peripherally about this central mass were palisading clumps of histiocytes with occasional foam or giant cells. The presence of activated histiocytes was confirmed by strong intracytoplasmic diffuse activity of acid phosphatase and non-specific esterase (Fig. 2).

The study of the tissue with LEU1 antibody showed perivascular masses of T-lymphocytes in the upper and deep dermis. LEU1-reactive lymphocytes also were observed intermingled with histio-

cytes in the palisading granuloma. At low power, the form of the granuloma could be discerned by the histiocyte-lymphocyte pattern alone (Fig. 3).

Staining with LEU2A antibody, which detects cytotoxic (suppressor) T-cell subset lymphocytes, revealed varying numbers of strongly positive cells in the perivascular infiltrates. In two cases, only a few suppressor T-cells were found in the granulomas of the patients with systemic lupus erythematosus and rheumatoid arthritis. The study also showed that the important component of the T-cell infiltrate consisted of LEU3A-reactive helper

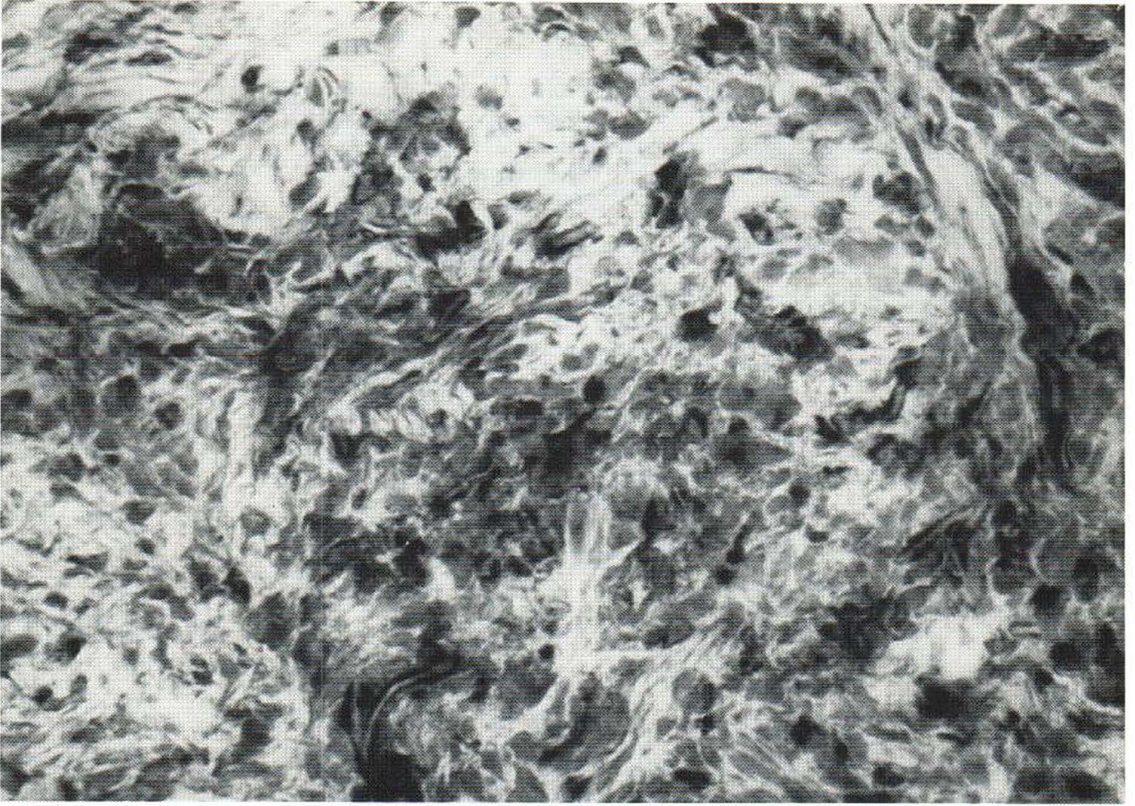


Fig. 2. Activated histiocytes with strong diffuse acid phosphatase activity are seen within a granuloma ($\times 320$).

T-cells about blood vessels and within and about the localized granuloma (Fig. 4). In some areas, isolated groups of LEU3A-reactive helper T-cells were surrounded by a mass of large histiocytes. Some cells within and about the granuloma were difficult to classify because of the dermal necrosis.

In the specimens that we studied for acid phosphatase activity, most of the lymphocytes around the blood vessels and within the granuloma showed a focal distinctive activity that is evidence of activated T-lymphocytes. Small infiltrates composed of closely associated T-lymphocytes and histiocytes displaying a very strong activity of diffuse acid phosphatase and non-specific esterase could be identified about the granuloma.

DISCUSSION

The consistent presence of T-lymphocytes about the vessels in relation to the Churg-Strauss granuloma suggests that they may have an active role in

the inflammatory process. This is supported by the presence of T-lymphocytes that have surface antigens characteristic of helper T-cells. Examinations of other forms of vasculitis may reveal a more important role for the lymphocyte in vasculitis than is generally stated.

The presence of helper T-cells near the histiocytes in Churg-Strauss granuloma suggests the similarity of this process to the lesion of granuloma annulare. Buechner et al. (2) have demonstrated helper T-cells in abundance about the blood vessels associated with the palisading histiocytes and in microgranulomas within the lesion of granuloma annulare. These authors have also demonstrated similar findings in the granulomatous nodules of cutaneous sarcoidosis. The Churg-Strauss granuloma, therefore, resembles the lesions of granuloma annulare not only in general form but also in relation to the T-lymphocytes at sites of disease activity. The Churg-Strauss granuloma may be another cutaneous T-cell-dependent granuloma.

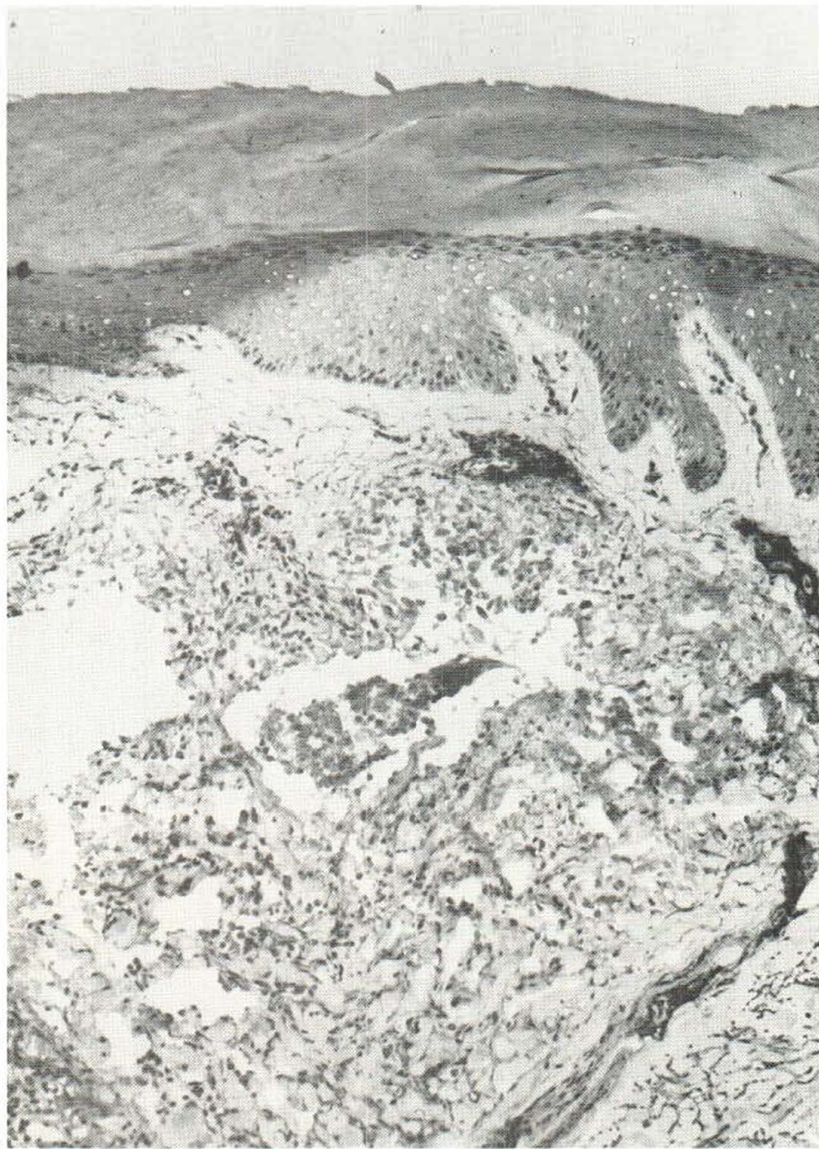

Fig. 3. Demonstration of T-lymphocytes in perivascular infiltrates and within Churg-Strauss granuloma, by monoclonal anti-LEU1 antibody ($\times 100$).

Variations in the proportion of T-cell subsets in cutaneous infiltrates may be related to the different immunopathologic abnormalities associated with the diseases that produce Churg-Strauss granuloma. In patients with autoimmune diseases, including systemic lupus erythematosus and rheumatoid arthritis, a loss of suppressor T-cells has been frequently observed (18). In our group, 2 patients with autoimmune diseases had a remarkably low number of LEU2A antibody-reactive suppressor T-cells in the perivascular infiltrates.

Interestingly, the helper-inducer T-cell subset

could be identified in all cases. These observations suggest that the granuloma formation may be mediated by a relative increase in the numbers of helper T-cells at sites of disease.

One possibility is that the presence of activated T-lymphocytes associated with histiocytes represents a delayed hypersensitivity reaction to an antigen, leading to granuloma formation. The frequent association of Churg-Strauss granuloma with allergic conditions and systemic vasculitis supports this hypothesis.

We have not answered the question of whether

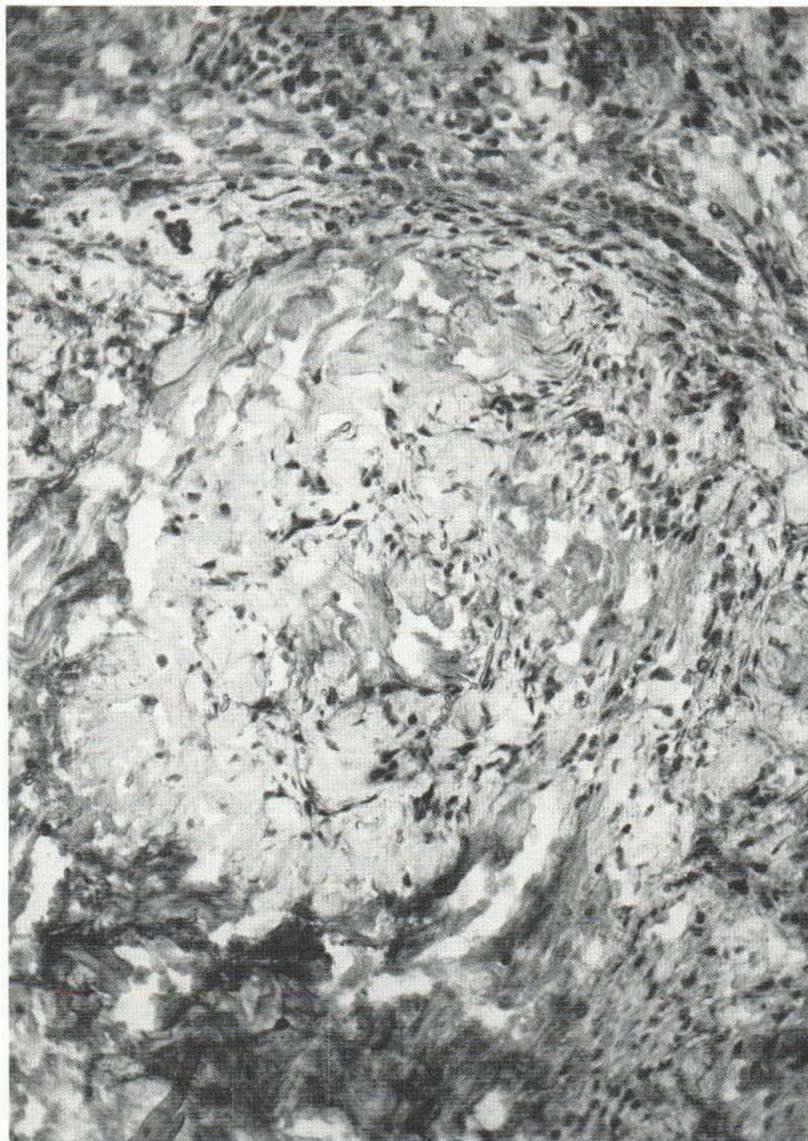


Fig. 4. LEU3A reactive-positive helper T-cells around blood vessels and within granuloma ($\times 160$).

it is the antigen, the nature of the vasculitis, or the host that produces this unique histologic pattern. Our patients had systemic allergic granulomatosis and drug, malignancy, or connective tissue disease related to the production of the vasculitis. Such multiple causes strongly suggest that it is the pattern of vasculitis response, not the cause, that leads to the lesion. We tend to believe that certain hosts produce a mixed cellular reaction vasculitis in which helper T-cells predominate. From this environment, the T-cell granuloma may develop.

An alternative explanation, that these lesions

are similar to granuloma annulare lesions arising in a patient with vasculitis, does not seem as satisfactory to us because of the acute appearance of these symmetrical lesions. Our study of granuloma annulare lesions shows only rare polymorphonuclear leukocytes in these lesions, in contrast to assessments by others (1). Our cases of granuloma annulare do not show necrotizing vasculitis clinically or histologically (19, 21). We believe that the intermittently positive immunofluorescence findings in granuloma annulare associated with the blood vessels are secondary and similar to those

seen in erythema multiforme and acute guttate parapsoriasis. The explanation that granuloma annulare is a delayed hypersensitivity granuloma may also apply to the Churg-Strauss granuloma.

ACKNOWLEDGEMENT

Dr Buechner is a visiting clinician from the Department of Dermatology, University of Basle, Switzerland, supported by a grant from the Swiss National Science Foundation.

REFERENCES

- Ackerman, A. B.: Histologic diagnosis of inflammatory skin disease: A method of pattern analysis. Lea & Febiger, Philadelphia, 1978.
- Buechner, S. A., Winkelmann, R. K. & Banks, P. M.: Identification of T-cell subpopulations in granuloma annulare. *Arch Dermatol* (in press).
- Burg, G. & Braun-Falco, O.: Fortschritte in der cytochemischen Differenzierung von Infiltratzellen in der Haut. *Hautarzt* 25: 1, 1974.
- Chumbley, L. C., Harrison, E. G., Jr & DeRemee, R. A.: Allergic granulomatosis and angiitis (Churg-Strauss syndrome): Report and analysis of 30 cases. *Mayo Clin Proc* 52: 477, 1977.
- Churg, J.: Allergic granulomatosis and granulomatous-vascular syndromes. *Ann Allergy* 21: 619, 1963.
- Churg, J. & Strauss, L.: Allergic granulomatosis, allergic angiitis, and periarteritis nodosa. *Am J Pathol* 27: 277, 1951.
- Crotty, C. P., DeRemee, R. A. & Winkelmann, R. K.: Cutaneous clinicopathologic correlation of allergic granulomatosis. *J Am Acad Dermatol* 5: 571, 1981.
- Davey, F. R., Dock, N. L. & MacCallum, J.: Cytochemical reactions in resting and activated T-lymphocytes. *Am J Clin Pathol* 74: 174, 1980.
- Dicken, C. H. & Winkelmann, R. K.: The Churg-Strauss granuloma: Cutaneous, necrotizing, palisading granuloma in vasculitis syndromes. *Arch Pathol Lab Med* 102: 576, 1978.
- Engleman, E. G. & Levy, R.: Studies of a human T lymphocyte antigen recognized by a monoclonal antibody (abstract). *Clin Res* 28: 502A, 1980.
- Howell, S. B. & Epstein, W. V.: Circulating immunoglobulin complexes in Wegener's granulomatosis. *Am J Med* 60: 259, 1976.
- Kersey, J. H. & Gajl-Peczalska, K. J.: T and B lymphocytes in humans: A review. *Am J Pathol* 81: 446, 1975.
- Kung, P. C., Goldstein, G., Reinherz, E. L. & Schlossman, S. F.: Monoclonal antibodies defining distinctive human T cell surface antigens. *Science* 206: 347, 1979.
- Li, C. Y., Lam, K. W. & Yam, L. T.: Esterases in human leukocytes. *J Histochem Cytochem* 21: 1, 1973.
- Li, C. Y., Yam, L. T. & Lam, K. W.: Acid phosphatase isoenzyme in human leukocytes in normal and pathologic conditions. *J Histochem Cytochem* 18: 473, 1970.
- Reinherz, E. L., Kung, P. C., Goldstein, G. & Schlossman, S. F.: Further characterization of the human inducer T cell subset defined by monoclonal antibody. *J Immunol* 123: 2894, 1979.
- Strauss, L., Churg, J. & Zak, F. G.: Cutaneous lesions of allergic granulomatosis: A histopathologic study. *J Invest Dermatol* 17: 349, 1951.
- Strelkauskas, A. J., Callery, R. T., McDowell, J., Bore, Y. & Schlossman, S. F.: Direct evidence for loss of human suppressor cells during active autoimmune disease. *Proc Natl Acad Sci USA* 75: 5150, 1978.
- Umbert, P. & Winkelmann, R. K.: Granuloma annulare: Direct immunofluorescence study. *Br J Dermatol* 95: 487, 1976.
- Winkelmann, R. K. & Dicken, C. H.: The cutaneous necrotizing palisading granuloma (Churg-Strauss granuloma). *Major Probl Dermatol* 10: 242, 1980.
- Winkelmann, R. K., Umbert, P. & Kossard, S.: Granuloma annulare: A histiocytic lesion of cell-mediated immunity. *G Ital Dermatol Venereol* 115: 147, 1980.

Received November 1, 1982

R. K. Winkelmann, M.D., Ph.D.
Mayo Clinic
Rochester, Minnesota 55905
USA